

**UCC Library and UCC researchers have made this item openly available.
Please [let us know](#) how this has helped you. Thanks!**

Title	Case records of the Massachusetts General Hospital. Weekly clinicopathological exercises. Case 7-2005. A 59-year-old woman with an incidentally discovered adrenal nodule.
Author(s)	Dluhy, R. G.; Maher, Michael M.; Wu, C. L.
Publication date	2005-03-10
Original citation	Dluhy, R. G., Maher, M. M. and Wu, C. L. (2005) 'Case records of the Massachusetts General Hospital. Weekly clinicopathological exercises. Case 7-2005. A 59-year-old woman with an incidentally discovered adrenal nodule', The New England Journal of Medicine, 352(10), pp. 1025-1032. http://www.nejm.org/doi/full/10.1056/NEJMcp059002
Type of publication	Article (peer-reviewed)
Link to publisher's version	http://dx.doi.org/10.1056/NEJMcp059002 Access to the full text of the published version may require a subscription.
Rights	© 2005 Massachusetts Medical Society. All rights reserved. From Dluhy, et al. 'Case 7-2005: A 59-year-old woman with an incidentally discovered adrenal nodule', N Engl J Med, 2005; 352:1025-1032. Reprinted with permission.
Item downloaded from	http://hdl.handle.net/10468/3074

Downloaded on 2021-01-20T16:28:18Z

CASE RECORDS of the MASSACHUSETTS GENERAL HOSPITAL

Founded by Richard C. Cabot
Nancy Lee Harris, M.D., Editor

Jo-Anne O. Shepard, M.D., Associate Editor
Sally H. Ebeling, Assistant Editor

Stacey M. Ellender, Assistant Editor
Christine C. Peters, Assistant Editor



Case 7-2005: A 59-Year-Old Woman with an Incidentally Discovered Adrenal Nodule

Robert G. Dluhy, M.D., Michael M. Maher, M.D., and Chin-Lee Wu, M.D.

PRESENTATION OF CASE

A 59-year-old woman was seen in the clinic for evaluation of an adrenal mass.

Two years earlier, she had undergone her first physical examination since childhood, having sought medical attention because of morning stiffness and polyarticular joint pain that she had had for several months and the recent onset of dysuria. She was found to have hypertension (blood pressure, 140/100 mm Hg) and rheumatoid arthritis. A urine culture showed growth of *Escherichia coli*, and amoxicillin was prescribed. Doxazosin (4 mg) and lisinopril (10 mg) were administered for the hypertension; her arthritis symptoms were controlled by hydroxychloroquine.

Dysuria, pyuria, and positive urine cultures persisted, despite multiple courses of antibiotics. Five months after the physical examination, a computed tomographic (CT) scan of the pelvis showed a colovesical fistula. There was a well-circumscribed, homogeneous mass, 2.5 cm in diameter, in the left adrenal gland. A low anterior resection of the rectum and excision and closure of the colovesical fistula were performed. Over the next year, the patient gained 7 kg in weight and remained hypertensive despite increasing doses of antihypertensive medications. An abdominal–pelvic CT scan obtained 17 months after the first scan showed that the left adrenal mass was unchanged in size and appearance and the density was measured at 4 Hounsfield units. The patient was referred to an endocrinologist.

The patient was unmarried and had never been sexually active. Menopause occurred when she was 47 years of age. She had smoked three packs of cigarettes per day for 40 years but had stopped 4 years earlier, at 55 years of age. She consumed approximately one alcoholic beverage per week. There was no family history of endocrine disorders or tumors. Her medications were lisinopril (20 mg daily), hydroxychloroquine (20 mg twice daily), doxazosin (8 mg daily), and nifedipine (60 mg daily).

The patient's blood pressure was 150/90 mm Hg, and her pulse 80 beats per minute and regular; her weight was 109 kg. At the examination by the endocrinologist, mild facial plethora and fullness were evident. There was no hirsutism. There were dorso-cervical and supraclavicular fat pads. There was no bruising of the soft tissue. The thyroid gland was not enlarged. Examination of the abdomen showed truncal obesity without striae. There was no organomegaly. Neurologic examination showed no abnormalities, and there was no proximal limb weakness.

From the Division of Endocrinology, Diabetes and Metabolism, Brigham and Women's Hospital (R.G.D.); the Departments of Radiology (M.M.M.) and Pathology (C.-L.W.), Massachusetts General Hospital; and the Departments of Medicine (R.G.D.), Radiology (M.M.M.), and Pathology (C.-L.W.), Harvard Medical School.

N Engl J Med 2005;352:1025-32.

Copyright © 2005 Massachusetts Medical Society.

A complete blood count, levels of serum electrolytes, and the results of tests of renal, liver, and thyroid function were all normal. After the administration of 1 mg of dexamethasone in the evening, the morning cortisol measurement was 2.2 μg per deciliter. On multiple examinations, all performed in the morning during a two-month period, the levels of corticotropin ranged from 11 to 40 pg per milliliter (2.4 to 8.8 pmol per liter); the normal range is 6 to 76 pg per milliliter (1.3 to 16.7 pmol per liter). The results of other hormone tests are shown in Tables 1, 2, and 3.

A CT scan of the patient's head after intravenous administration of contrast material showed a partially empty sella turcica and no signs of a pituitary adenoma. A chest radiograph showed no abnormalities.

A diagnostic procedure was performed.

DIFFERENTIAL DIAGNOSIS

Dr. Robert G. Dluhy: May we review the imaging of the adrenal mass?

Dr. Michael M. Maher: The original CT scan shows a left adrenal mass, 2.5 cm in diameter; the density of the lesion appears low (Fig. 1A). The scan from 17 months later again shows a well-circumscribed, low-density mass, 2.5 cm in diameter, that has remained stable in size (Fig. 1B). The density of the lesion was measured at 4 Hounsfield units, which suggests the presence of fat and a diagnosis of an adrenal adenoma. The right adrenal gland is normal.

Dr. Dluhy: This 59-year-old, postmenopausal, hypertensive woman with recurrent urinary tract infec-

tions was incidentally found to have a left adrenal mass, 2.5 cm in diameter, during a CT examination of the abdomen and pelvis. Seventeen months later, she had gained 7 kg and remained hypertensive even though she was taking three drugs to lower her blood pressure. The findings on physical examination suggested Cushing's syndrome, with truncal obesity and palpable supraclavicular and dorsocervical fat pads, but there were no signs of abdominal striae, proximal limb weakness, or hirsutism. A CT scan obtained at the time of the visit to the endocrinologist showed that the left adrenal mass had not enlarged. The mass was homogeneous and of low density, findings consistent with the diagnosis of a cortical adenoma.

The term "incidentaloma" has been coined for an adrenal mass that is discovered during diagnostic testing for another condition, rather than testing performed because of the suspicion of an adrenal disorder.¹ Benign adrenal masses of 1 to 2 cm in size are found in 2 to 3 percent of adults older than 50 years of age who are examined at autopsy. The prevalence of clinically inapparent adrenal masses increases with age and approaches 7 percent among persons older than 70 years of age. Conversely, incidentalomas are uncommon in patients younger than 30 years of age; thus, an adrenal mass in a young patient is probably clinically important.

In the evaluation of an adrenal mass, there are two issues that need to be addressed. First, is the mass benign or malignant? Second, if it is a primary adrenal tumor, is it functional— is it secreting hormones or not? In this case, the issue is whether the mass is causing severe hypertension and the physical features that suggest Cushing's syndrome.

Table 1. Urinary Hormone Levels.*

Variable	Day 1	Day 3	Day 16	Day 61	Normal Values
Free cortisol ($\mu\text{g}/24$ hr)	20	110	96	73	20–70
Total volume (ml/24 hr)	1050	1600	2000	1320	
Creatinine (mg/24 hr)	NA	NA	1460	1056	
Epinephrine ($\mu\text{g}/24$ hr)	5				2–24
Norepinephrine ($\mu\text{g}/24$ hr)	51				15–100
Total catecholamines ($\mu\text{g}/24$ hr)	56				20–121
Metanephrine ($\mu\text{g}/24$ hr)	127				45–290
Normetanephrine ($\mu\text{g}/24$ hr)	375				82–500
Total metanephrines ($\mu\text{g}/24$ hr)	502				120–700

* NA denotes not available.

BENIGN OR MALIGNANT?

Seventy-five percent of adrenal masses detected during staging in a patient with cancer represent metastases.¹ Such masses usually have high CT attenuation values (>20 Hounsfield units), in contrast to the adrenal mass in this patient. For a cortical neoplasm, such as this mass, the first concern is whether it is an adrenal cortical carcinoma. This is a very rare cancer, with an estimated prevalence of 5 cases per 1 million persons, but it has a high associated mortality rate. The risk that the tumor will be a carcinoma increases with the size of the tumor.² The risk of cancer is 2 percent among tumors less than 4 cm in diameter, but it increases to 25 percent for tumors greater than 6 cm. Accordingly, most clinicians recommend excision of adrenal masses greater than 6 cm. There is controversy as to whether neoplasms from 4 to 6 cm in size should be removed; the overwhelming majority are benign, but the risk of cancer is 6 percent. Other radiographic features that may indicate a benign neoplasm include smooth borders without evidence of hemorrhage or necrosis.

The neoplasm in this patient was 2.5 cm in diameter and was described as well circumscribed and homogeneous. Most important, over the course of 17 months, the mass had not changed in size or appearance. Periodic radiographic surveillance, such as every six months over a period of several years, of patients with small adrenal masses that carry a low risk of cancer, such as this one, is an accepted strategy to ascertain with some confidence whether the lesion is benign.³ Although some benign mass-

Table 2. Serum Hormone Levels.

Variable	Value	Normal Value
Renin (ng/ml/hr)	12.2	0.7–10.0
Aldosterone (ng/dl)	7.0	2–9
Dehydroepiandrosterone sulfate (μg/dl)	37	30–260*

* This is the normal range for postmenopausal women.

Table 3. Corticotropin-Releasing Hormone Stimulation Test (1 μg per Kilogram of Body Weight).*

Time in Relation to Stimulation	Corticotropin	Cortisol
min	pg/ml	μg/dl
-15	12	14
0	14	12
15	33	23
30	40	31
60	33	37
90	25	31
120	16	26

*This test was performed in the morning.

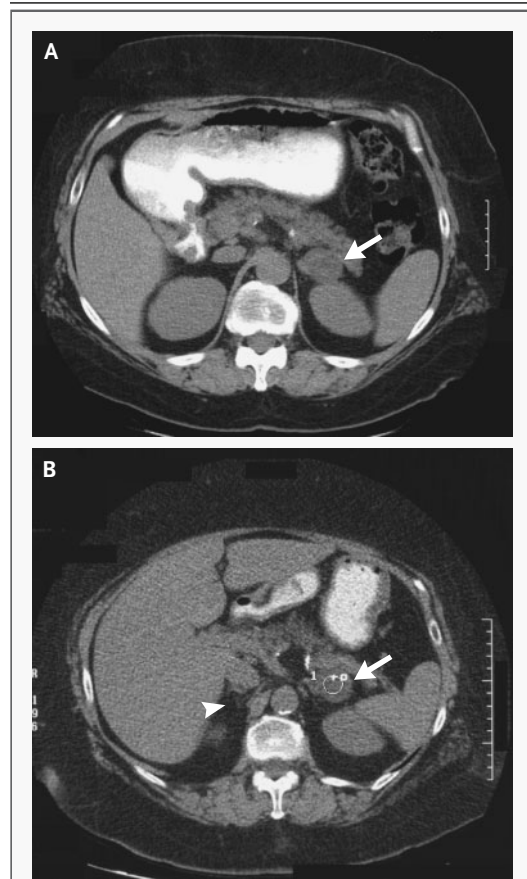


Figure 1. CT Scan of the Abdomen Obtained without the Administration of Intravenous Contrast Material.

A CT scan of the abdomen obtained 17 months before the current evaluation (Panel A) shows a left adrenal mass, 2.5 cm in diameter (arrow), which is well circumscribed and is of low density. A CT scan obtained at the time of this evaluation (Panel B) shows a well-circumscribed, low-density left adrenal lesion that is stable in size and appearance on imaging as compared with the previous image. The density of the left adrenal mass (arrow and circle) is 4 Hounsfield units. The right adrenal gland shows no abnormalities (arrowhead).

es can increase in size over time, a mass that increases in size by more than 2 cm over 6 to 12 months should probably be surgically removed. All of the radiographic data support the diagnosis of a benign adrenocortical adenoma in this patient.

FUNCTIONAL OR NONFUNCTIONAL?

The next consideration is whether the adrenal mass is clinically functional, since surgical removal of the mass could be indicated if there is hormonal hypersecretion. Approximately 70 percent of clinically inapparent adrenal masses are nonfunctional. Since this patient had severe hypertension and physical features that suggested Cushing's syndrome, a unifying diagnosis would be a cortisol-secreting adenoma.

Functional adrenal tumors include pheochromocytomas, cortisol-secreting adenomas, aldosterone-secreting adenomas, and neoplasms that have virilizing or feminizing effects. The first step in patients with clinically inapparent adrenal masses should be to review the history and physical examination, searching for clues to excessive hormone secretion. The presence of hypertension, a history of paroxysmal hypertension, and symptoms and signs of hypersecretion of cortisol and sex hormones should be sought. Even in the absence of these findings, a National Institutes of Health State-of-the-Science Conference recommended that all patients with incidentally discovered adrenal masses be screened for pheochromocytoma and hypercortisolism.¹ Patients with hypertension should also be evaluated for primary hyperaldosteronism.

Catecholamine levels were assessed in this patient with a 24-hour urine specimen, and they were normal (Table 1). Screening for primary aldosteronism is performed by the simultaneous measurement of plasma renin activity and plasma aldosterone. A plasma aldosterone-to-renin ratio greater than 25 to 30 is consistent with autonomous aldosterone secretion.⁴ In this patient, the plasma renin level was not suppressed and was appropriately elevated, a reflection of angiotensin-converting-enzyme inhibition (Table 2). Finally, the level of the adrenal androgen dehydroepiandrosterone sulfate was normal. In summary, I can confidently conclude that the adrenal mass in the patient under discussion was not a pheochromocytoma or an aldosterone- or androgen-producing neoplasm.

To diagnose Cushing's syndrome, the overnight dexamethasone suppression test is preferred. After the administration of 1 mg of dexamethasone at

bedtime, the measurement the next morning of a cortisol level less than 1.8 μg per deciliter rules out Cushing's syndrome.⁵ This criterion results in a test with high sensitivity but a high false positive rate. An alternative test with high sensitivity and specificity is the measurement of free or unmetabolized cortisol in a 24-hour urine specimen. False positive results in either test can occur in patients with depression and chronic alcoholism; however, such patients may not have physical features of Cushing's syndrome. Subclinical hypercortisolism also may occur somewhat frequently in incidentally discovered adrenal masses (so-called preclinical Cushing's syndrome).⁶⁻⁸

The data in this patient are inconsistent. The level of cortisol (2.2 μg per deciliter) the morning after the dexamethasone suppression test was probably normal. However, the free cortisol level in the 24-hour urine specimen shows intermittent hypercortisolism, although levels of creatinine excretion are not provided to validate the accuracy of some of the specimens (Table 1). Considering the clinical features that suggested Cushing's syndrome and the possibility of a cortisol-secreting adrenal neoplasm, evaluation was pursued on the basis of the reasoning that adrenal hypercortisolism should be associated with suppressed levels of corticotropin. Early-morning plasma levels of corticotropin greater than 20 pg per milliliter (4.4 pmol per liter) imply a corticotropin-dependent cause, and levels less than 5 pg per milliliter (1.1 pmol per liter) an adrenal-dependent cause; levels between 5 and 20 pg per milliliter are considered indeterminate.⁵ In this patient, the morning levels of corticotropin varied, ranging from 11 to 40 pg per milliliter.

Next, an ovine corticotropin-releasing hormone stimulation test was performed (Table 3). In patients with Cushing's disease secondary to a pituitary microadenoma, the increment in levels of corticotropin above the baseline level exceeds 50 percent; ectopic corticotropin-secreting tumors usually fail to respond to stimulation with corticotropin-releasing hormone.^{5,9} In this patient, the baseline level of corticotropin more than doubled, but the absolute peak level of 40 pg per milliliter at 30 minutes is at the low end of the responses in normal subjects. The cortisol levels appropriately followed the changes in corticotropin. Taken together, the data are probably best interpreted as showing intermittent hypercortisolism with incomplete suppression of pituitary secretion of corticotropin.

The expression of ectopic hormone receptors

in the adrenal cortex could explain the varied biochemical data in this patient.^{10,11} This phenomenon is usually seen in patients with bilateral macronodular adrenal hyperplasia, but cases of unilateral adrenal adenomas with ectopic hormone receptors have been reported.⁴ Ectopic receptors that can be expressed include gastric inhibitory polypeptide,^{12,13} luteinizing hormone,¹⁴ and catecholamines.¹⁵ The hypercortisolism in patients with adrenal ectopic receptor expression may be episodic — for example, occurring after meals — and in most cases the corticotropin levels are frankly suppressed. However, adrenal neoplasms with intermittent food-related hypercortisolism and incomplete suppression of corticotropin have also been reported.¹⁶

I conclude that the hypercortisolism in this patient is corticotropin-independent and that the left adrenal adenoma is secreting cortisol episodically. The secretion of cortisol is at a level that is sufficient to produce the clinical features of Cushing's syndrome but it is insufficient to suppress corticotropin levels completely. The episodic nature of the secretion best fits the characteristics associated with food-dependent Cushing's syndrome; the measurement of cortisol levels after a meal could have been an appropriate diagnostic test. Alternatively, there could be intrinsic episodic secretion by the tumor or expression of another ectopic receptor.

To confirm the diagnosis, the function of the contralateral adrenal gland could be assessed with the use of scintigraphy with radiolabeled iodocholesterol. This test shows exclusive uptake in the gland with the tumor and no visualization of the contralateral gland in patients with hypercortisolism due to an adenoma.^{17,18} An alternative test would be bilateral adrenal-vein sampling to document lateralization of cortisol secretion on the side of the adenoma.

Dr. Nancy Lee Harris (Pathology): Dr. Grinspoon, can you tell us what your thinking was as you evaluated this patient?

Dr. Steven K. Grinspoon (Endocrinology): This patient had a 2.5-cm adrenal mass that had been stable in size for 17 months. She did not show many of the typical stigmata associated with Cushing's syndrome and, on the basis of the physical examination, could have been considered to have simple obesity. The results of the biochemical testing were equivocal: in the overnight 1-mg dexamethasone test, her morning cortisol level was suppressed to

2.2 µg per deciliter, but three of four measurements of free cortisol levels in the urine were increased. Her level of corticotropin, although low, was not entirely suppressed. On the corticotropin-releasing hormone test, she had increases in cortisol and corticotropin that were more consistent with a pituitary source (Cushing's disease) than with an adrenal source. However, because she had an adrenal nodule and her corticotropin level was on the low side of the normal range, I elected to perform a rarely used test, an iodocholesterol scan, which was done at New England Medical Center.

CLINICAL DIAGNOSIS

Cortisol-secreting adrenal adenoma and Cushing's syndrome.

DR. ROBERT G. DLUHY'S DIAGNOSIS

Cortisol-secreting adrenal adenoma and Cushing's syndrome.

PATHOLOGICAL DISCUSSION

Dr. Harris: Dr. Maher, would you show us the imaging study?

Dr. Maher: In iodocholesterol scintigraphy, a radiopharmaceutical agent is injected on day 1, and peak levels are usually achieved within the adrenal gland within two days. There is a lot of background activity at this time, so the best window in which to obtain an image is between four and five days, when background activity decays. The images from the scan obtained on day 5 (Fig. 2) show that there is increased uptake of the radiopharmaceutical agent in the left adrenal gland. There is no activity in the right adrenal gland. The findings suggest a functional left adrenal adenoma.

Dr. Grinspoon: This test indicated that the patient had an autonomous adrenal nodule, but it did not entirely rule out the simultaneous occurrence of a pituitary source of corticotropin and an autonomously functioning nodule. Imaging of her head did not reveal a pituitary tumor, although this would not rule out the more common source of excess corticotropin from a very small tumor. Nonetheless, I referred her for adrenal surgery.

Dr. Chin-Lee Wu: A left adrenalectomy was performed. The adrenal gland contained a well-circumscribed, smooth-surfaced mass that was 3 cm in di-

imeter and weighed 20 g. The cut surface is yellow, smooth, homogeneous, and well demarcated from the residual normal adrenal cortical tissue (Fig. 3A). On microscopical examination, the cells form nested and trabecular patterns and contain abundant lipid-rich, clear cytoplasm, with small nuclei and no mitoses (Fig. 3B), and they resemble the cells seen in the zona fasciculata of the normal adrenal cortex.

With the increasing use of imaging methods, the incidental findings of asymptomatic adrenal tumors provide diagnostic challenges for pathologists as well as clinicians. The main pathological differential diagnosis of these tumors includes adrenal cortical hyperplasia, adenoma, carcinoma, metastatic cancer, and less commonly, myelolipoma, lipoma, and nonfunctional pheochromocytoma. It is not usually possible to distinguish functional from nonfunctional adrenal cortical tumors on the basis of the pathological findings.

When a single adrenal cortical mass is found, the differential diagnosis consists of adrenal cortical adenoma and carcinoma. Grossly, adrenal cortical adenomas are small (the median size is 2 cm, the median weight 10 g) and well circumscribed, with a smooth cut surface, and no necrosis or hemorrhage.¹⁹ Adrenal cortical carcinomas are large (the

median size is 14 cm, the median weight 510 g), with an ill-defined border, nodular coarse cut surface containing necrosis, and hemorrhage.²⁰

When viewed microscopically, adrenal cortical carcinomas usually contain atypical mitoses, show signs of vascular and capsular invasion, and extend into adjacent adipose tissue.²⁰ The nine histologic features used to distinguish carcinoma from adenoma are a high mitotic rate (≥ 5 per 50 high-power fields), atypical mitoses, venous invasion, a high nuclear grade (Fuhrman grade 3 to 4; on a scale from 1 to 4, with grade 1 indicating the best prognosis and grade 4 the worst), an absence of cells with clear cytoplasm (< 25 percent of the cells), a diffuse growth pattern (in more than one third of

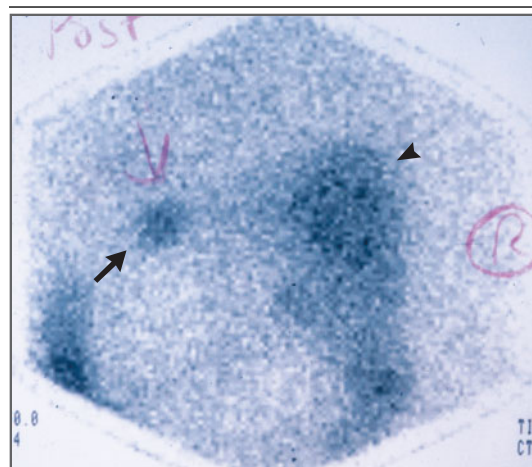


Figure 2. Posterior Views Obtained by Iodocholesterol Scintigraphy, Five Days after Intravenous Administration of a Radiopharmaceutical Agent.

There is increased uptake of the radiolabeled material seen in the left adrenal mass (arrow) and no uptake in the right adrenal gland. There is background activity in the liver (arrowhead).

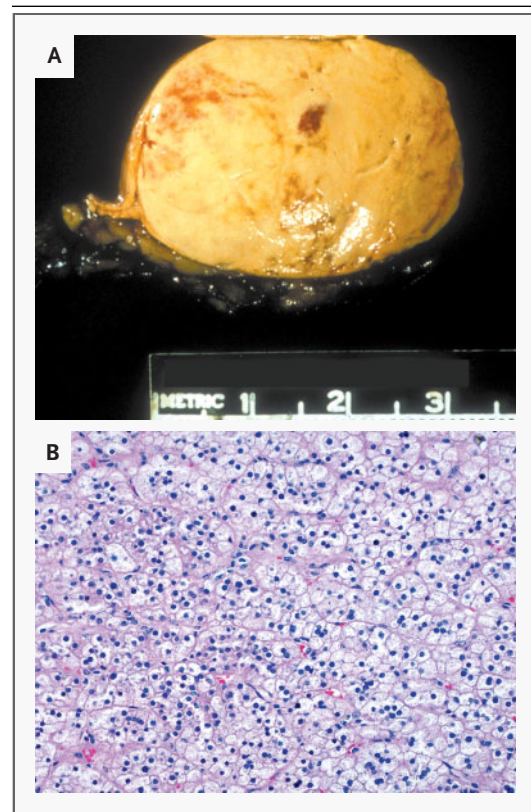


Figure 3. Tumor of the Adrenal Gland.

A gross photograph (Panel A) shows that the tumor is well circumscribed, with a yellow-tan, smooth, homogeneous cut surface; it is well demarcated from the residual normal adrenal cortical tissue. On microscopical examination (Panel B), the tumor consists of cells arranged in nested and trabecular patterns and contains abundant lipid-rich, clear cytoplasm. The cells are similar to those in the zona fasciculata of the normal adrenal cortex.

the tumor), necrosis, sinusoidal invasion, and capsular invasion.²¹ If three or more of these histologic features are present, a diagnosis of adrenal cortical carcinoma is made, whereas adrenal cortical adenomas contain two or fewer of these histologic features.^{21,22}

Fine-needle aspiration biopsy may be useful in the diagnosis of adrenal incidentaloma after appropriate testing to rule out pheochromocytoma. Such a biopsy can be useful in distinguishing metastatic tumors from primary adrenal tumors. When adrenal cortical tissue is identified, the differential diagnosis includes hyperplasia, adenoma, and carcinoma. It is not possible to distinguish between hyperplasia and adenoma on fine-needle aspiration biopsy. Features such as atypia and mitotic activity suggest adrenal cortical carcinoma. If the features of an obvious cancer are found, immunophenotyping studies can help to distinguish primary cancer from metastatic cancer in the adrenal gland.

The adrenal cortical tumor in this case was small and well circumscribed, with no necrosis or hemorrhage; histologically, the tumor cells contained clear, lipid-rich cytoplasm, and no mitoses or other features of adrenal cortical carcinoma were present. Thus, the pathological diagnosis was adrenal cortical adenoma.

Dr. Harris: Dr. Grinspoon, could you tell us about the patient's postoperative course?

Dr. Grinspoon: Hypoadrenalism developed after removal of the nodule, thereby indicating that the adrenal nodule was the source of her cortisol excess. She was treated with a low-dose glucocorticoid for three months, and over this time period her adrenal function recovered. Her arthritis symptoms flared up after the cure of her Cushing's syndrome. For 15 months after the operation, she required no antihypertensive medications, but her blood pressure rose again and was stabilized in the normal range with the administration of lisinopril at 10 mg daily.

Dr. Dluhy: There is a risk of adrenocortical insufficiency after adrenalectomy for a cortisol-secreting tumor, owing to the suppression of the contralateral adrenal gland. It should be the standard practice to administer supplemental or stress doses of cortisol intraoperatively and perioperatively, and the patient should be discharged from the hospital on a regimen of replacement cortisol therapy. After tapering and discontinuation of replacement treatment, a cosyntropin stimulation test can be useful to document recovery of the suppressed adrenal cortex.

ANATOMICAL DIAGNOSIS

Functional adrenal cortical adenoma.

REFERENCES

1. Grumbach MM, Biller BM, Braunstein GD, et al. Management of the clinically inapparent adrenal mass ("incidentaloma"). *Ann Intern Med* 2003;138:424-9.
2. Mantero F, Terzolo M, Arnaldi G, et al. A survey on adrenal incidentaloma in Italy. *J Clin Endocrinol Metab* 2000;85:637-44.
3. Barzon L, Scaroni C, Sonino N, Fallo F, Paoletta A, Boscaro M. Risk factors and long-term follow-up of adrenal incidentalomas. *J Clin Endocrinol Metab* 1999;84:520-6.
4. Dluhy RG, Lawrence JE, Williams GH. Primary mineralocorticoid excess states. In: Larsen PR, Kronenberg HM, Melmed S, Polonsky KS, eds. *Williams textbook of endocrinology*. 10th ed. Philadelphia: W.B. Saunders, 2003:573-6.
5. Raff H, Findling JW. A physiologic approach to diagnosis of the Cushing syndrome. *Ann Intern Med* 2003;138:980-91.
6. Reincke M, Nieke J, Krestin GP, Saeger W, Allolio B, Winkelmann W. Preclinical Cushing's syndrome in adrenal "incidentalomas": comparison with adrenal Cushing's syndrome. *J Clin Endocrinol Metab* 1992;75:826-32.
7. Rossi R, Tauchmanova L, Luciano A, et al. Subclinical Cushing's syndrome in patients with adrenal incidentaloma: clinical and biochemical features. *J Clin Endocrinol Metab* 2000;85:1440-8.
8. Tsagarakis S, Roboti C, Kokkoris P, Vasilioi V, Alevizaki C, Thalassinou N. Elevated post-dexamethasone suppression cortisol concentrations correlate with hormonal alterations of the hypothalamo-pituitary-adrenal axis in patients with adrenal incidentalomas. *Clin Endocrinol (Oxf)* 1998;49:165-71.
9. Giraldi FP, Invitti C, Cavagnini F. The corticotropin-releasing hormone test in the diagnosis of ACTH-dependent Cushing's syndrome: a reappraisal. *Clin Endocrinol (Oxf)* 2001;54:601-7.
10. Lacroix A, Ndiaye N, Tremblay J, Hamet P. Ectopic and abnormal hormone receptors in adrenal Cushing's syndrome. *Endocr Rev* 2001;22:75-110.
11. Mircescu H, Jilwan J, N'Diaye N, et al. Are ectopic or abnormal membrane hormone receptors frequently present in adrenal Cushing's syndrome? *J Clin Endocrinol Metab* 2000;85:3531-6.
12. Lacroix A, Bolté E, Tremblay J, et al. Gastric inhibitory polypeptide-dependent cortisol hypersecretion — a new cause of Cushing's syndrome. *N Engl J Med* 1992;327:974-80.
13. N'Diaye N, Hamet P, Tremblay J, Boutin J, Gaboury L, Lacroix A. Asynchronous development of bilateral nodular adrenal hyperplasia in gastric inhibitory polypeptide-dependent Cushing's syndrome. *J Clin Endocrinol Metab* 1999;84:2616-22.
14. Lacroix A, Hamet P, Boutin J-M. Leuprolide acetate therapy in luteinizing hormone-dependent Cushing's syndrome. *N Engl J Med* 1999;341:1577-81.
15. Lacroix A, Tremblay J, Rousseau G, Bouvier M, Hamet P. Propranolol therapy for ectopic β -adrenergic receptors in adrenal Cushing's syndrome. *N Engl J Med* 1997;337:1429-34.
16. Croughs RJ, Zelissen PM, van Vroonhoven TJ, et al. GIP-dependent adrenal

- Cushing's syndrome with incomplete suppression of ACTH. *Clin Endocrinol (Oxf)* 2000;52:235-40.
17. Barzon L, Scaroni C, Sonino N, et al. Incidentally discovered adrenal tumors: endocrine and scintigraphic correlates. *J Clin Endocrinol Metab* 1998;83:55-62.
18. Gross MD, Shapiro B, Francis IR, et al. Scintigraphic evaluation of clinically silent adrenal masses. *J Nucl Med* 1994;35:1145-52.
19. Adrenal cortical adenoma. In: Lack EE. Tumors of the adrenal gland and extra-adrenal paraganglia. 3rd series. Fascicle 19. Washington, D.C.: Armed Forces Institute of Pathology, 1997:91-122.
20. Adrenal cortical carcinoma. In: Lack EE. Tumors of the adrenal gland and extra-adrenal paraganglia. 3rd series. Fascicle 19. Washington, D.C.: Armed Forces Institute of Pathology, 1997:123-52.
21. Weiss LM. Comparative histologic study of 43 metastasizing and nonmetastasizing adrenocortical tumors. *Am J Surg Pathol* 1984;8:163-9.
22. Weiss LM, Medeiros LJ, Vickery AL Jr. Pathologic features of prognostic significance in adrenocortical carcinoma. *Am J Surg Pathol* 1989;13:202-6.

Copyright © 2005 Massachusetts Medical Society.

SLIDE SETS FOR THE CASE RECORDS AVAILABLE IN DIGITAL FORMAT

Any reader of the *Journal* who uses the Case Records of the Massachusetts General Hospital as a teaching exercise or reference material is eligible to receive digital images, with identifying legends, of pertinent radiographic, neurologic, and cardiac studies, gross specimens, and photomicrographs. The images on the CD for each case are in both PowerPoint and 300 dpi jpg format. For some cases, additional images that have not been selected for publication will be included on the CD. These images, which illustrate the current cases in the *Journal*, are mailed from the Department of Pathology to correspond to the week of publication and may be retained by the subscriber. Each year approximately 250 images from 40 cases are sent to each subscriber. The cost of the subscription is \$450 per year. Application forms for the current subscription year, which began in January, may be obtained from the Lantern Slides Service, Department of Pathology, Massachusetts General Hospital, Boston, MA 02114 (telephone 617-726-2974) or Pathphotoslides@partners.org. Images from individual cases may be obtained at a cost of \$35 per case.