OLLSCOIL NA hÉIREANN, CORCAIGH
THE NATIONAL UNIVERSITY OF IRELAND, CORK
COLÁISTE NA hOLLSCOILE CORCAIGH
UNIVERSITY COLLEGE CORK, CORK

Innovative Strategies for Teaching Anatomy to Dental Students

Thesis presented by

Mutahira Lone (BDS, MFDS, MDPH)

Under the supervision of

Dr. André Toulouse, Dr. Eric J. Downer, Dr. Joseph P. McKenna and

Prof. John F. Cryan

For the degree of

Doctor of Philosophy

July 2017

Department of Anatomy and Neuroscience

Head of the Department: Prof John F. Cryan

TABLE OF CONTENTS

Contents

Declaration

This submitted thesis is my own work and has not been submitted for another degree at University College Cork or elsewhere.

Author Contribution:

The author conducted all of the work in this thesis with the exception of the following:

-Ms Margaret Cole, UCC provided statistical assistance for chapter 2 and 3.

-Miss Tamara Vagg, UCC created the cranial nerve animation and tooth morphology quiz application.

-Dr Antonios Theocharopoulos, CUDSH scanned the extracted/plastic teeth.

Where the work of others has been used to augment my thesis it has been referenced accordingly.

Signed: __M.Lone_____ **Date:** _____14.06.17_____

Acknowledgments

First and foremost I would like to thank my supervisors, Dr André Toulouse, Dr Eric J. Downer, Dr Joseph P. McKenna and Professor John F. Cryan for their valuable time and supervision over the last 3 years- their support, guidance and mentorship was invaluable.

I would also like to thank Dr Antonios Theocharopoulos and Miss Tamara Vagg for collaborative work on the research projects. I am grateful to Cork University Dental School and Hospital for their generous funding for the research projects.

I couldn't have finished this thesis without my support system: *My colleagues*: Johnny O'Mahony, Aaron Stirling, Orla Duggan, Joy Balta, Ahmad Sheikh and Muhammad Asim. Thank you guys for proof reading my thesis and for all the friendly banter. I have thoroughly enjoyed my time at UCC and made friends for life. *My countless friends*: Amita, Tamara, Saba and Salma. You all kept me sane through the years and encouraged me to keep going. *My big Pakistani family:* My siblings and in-laws who provided moral support thought-out these years-helping me cross the finish line. *My childminders*: Sonoo I am so glad you were there with me in this journey-I don't know what I would have done without you. Also Talha, Saba, Ali and Asim for providing childminding support.

I would also like to thank all the dental students and educators who participated in my research projects and provided invaluable data. I would like to express my sincere appreciation to the technical staff of the Anatomy FLAME laboratory, Michael Cronin for his unwavering help and support and Carrie O'Flynn for helping me take the cadaveric images. I would also like to thank Sue Grenham, Deidre Kelleher and David O'Brien. A special thanks to Wayne Sheehan for leaving chocolate bars for me on Friday evening *'to keep me going'*. I would also like to thank Miss Bereniece Riedewald, Miss Miriam Dorgan and Miss Mary Moynihan for providing technical assistance and support.

I would like to express my sincere gratitude towards those who donated their bodies to the Department of Anatomy and Neuroscience in University College Cork for medical science and education. Without their generosity this work could not have been achieved.

Lastly, a special thanks to my parents for their love and support in all aspects of my life, and to the four very important men in my life; my husband and my sons for their love, patience, support and understanding.

List of Publications

PAPERS:

Published:

- Lone M, McKenna JP, Balta JY, O'Mahony SM, Cryan JF, Downer EJ and Toulouse A (2017) 'Assessment of Thiel-Embalmed Cadavers as a Teaching Tool for Oral Anatomy and Local Anesthesia', Journal of Dental Education, 81(4), pp. 420-426.

Submitted/In preparation:

- Lone M, McKenna JP, Cryan JF, Vagg T, Toulouse A and Downer EJ (2017) 'Development of an animation tool to supplement dental student study of the cranial nerves', European Journal of Dental Education, Accepted December 2017.

- Lone M, McKenna JP, Cryan JF, Downer EJ and Toulouse A (2017) 'A Survey of Tooth Morphology Teaching Methods Employed in the United Kingdom and Ireland', European Journal of Dental Education, Accepted December 2017.

- Lone M, McKenna JP, Cryan JF, Downer EJ and Toulouse A (2017) 'Teaching Practices in Anatomy Education: A Dental Perspective' To be submitted to Anatomical Sciences Education.

- Lone M, Vagg T, Theocharopoulos A, Cryan JF, Downer EJ, McKenna JP and Toulouse A (2017) 'Development and assessment of an online tooth morphology quiz to enhance dental student learning' To be submitted to Anatomical Sciences Education.

Conference Publication:

- Lone M, Vagg T, Theocharopoulos A, Cryan JF, Downer EJ, McKenna JP and Toulouse A (2017) 'Development of an online tooth morphology 3D quiz to enhance dental student learning'. 11th annual International Technology, Education and Development Conference, 6-8 March. Valencia, Spain: IATED, 6153-6160.

- Lone M, Vagg T, Cryan JF, McKenna JP, Downer EJ and Toulouse A (2017) 'A pipeline to create educational animations for third level education '. 11th annual International Technology, Education and Development Conference, Valencia, Spain, 6-8 March: IATED, 6227-6233.

Oral presentation:

- Lone M, McKenna JP, Cryan JF, Vagg T, Toulouse A and Downer EJ, 'Will the use of animation lead to enhanced learning of the cranial nerves?' Annual Research Day of the Irish Division of the International Association of Dental Research, Cork 2016, Ireland.

- Lone M, McKenna JP, Cryan JF, Downer EJ and Toulouse A 'Thiel-embalmed cadavers as clinical teaching tools: a pilot study' Annual Research Day of the Irish Division of the International Association of Dental Research, Cork 2016, Ireland.

Posters Presented:

- Lone M, McKenna JP, Cryan JF, Vagg T, Toulouse A and Downer EJ, 'Effectiveness of an Animation Tool in Enhancing Student Learning of the Cranial Nerves'. New Horizons in Medical Research, December 2015, University College Cork, Cork.

- Lone M, McKenna JP, Cryan JF, Vagg T, Toulouse A and Downer EJ, 'Can a cranial nerve animation enhance Dental student learning? Employing an innovative teaching aid in the classroom' Experimental Biology Meeting, April, 2016, San Deigo.

- Lone M, McKenna JP, Cryan JF, Vagg T, Toulouse A and Downer EJ, 'Development of a cranial nerve animation to enhance dental student learning', New Horizons in Translational Research, December 2016, University College Cork, Cork.

- Lone M, McKenna JP, Balta JY, O'Mahony SM, Cryan JF, Downer EJ and Toulouse A, 'Assessment of Thiel-embalmed cadavers as a teaching tool for oral anatomy and local anesthesia', New Horizons in Translational Research, December 2016, University College Cork, Cork.

- Lone M, Vagg T, Theocharopoulos A, Cryan JF, Downer EJ, McKenna JP and Toulouse A 'Assessment of a 3D tooth morphology quiz for dental students', Anatomists on the Edge Conference, June 2017, Galway, Ireland.

List of Figures

List of Tables

List of Abbreviations

ANOVA: Analysis of Variance

APP: Application

BDS1: First Year Direct Entry Dentistry

BDSG1: First Year Graduate Entry Dentistry

CAD: Computer-Aided Design

CAI: Computer Aided Instructions

CAL: Computer-Aided Learning

CAM: Computer-Aided Manufacturing

CN: Cranial Nerves

CRP: Context Rich Problems

CTML: Cognitive Theory of Multimedia Learning

CUDSH: Cork University Dental School and Hospital

DDH1: First Year Dental Hygiene

DVD: Digital Versatile Disc

ECTS: European Credit Transfer System

FDI: Fédération Dentaire Internationale

NBDE: National Board Dental Examination

PBL: Problem Based Learning

Ph.D.: Doctor of Philosophy

SD: Standard Deviation

SEM: Standard Error of Mean

SPSS: Statistical Package for Social Scientists

SREC: Social Research Ethics Committee

TEC: Thiel Embalmed Cadaver

TMJ: Temporo Mandibular Joint

TMQ: Tooth Morphology Quiz

UCC: University College Cork

UK: United Kingdom

VLE: Virtual Learning Environment

VR: Virtual Reality

2D: Two Dimensional

3D: Three Dimensional

4D: Four Dimensional

Abstract

Anatomy education is an integral component of the undergraduate and postgraduate dental curriculum. A detailed understanding of anatomy is a pre-requisite before examination, diagnosis and clinical treatment of patients in all aspects of the healthcare systems. Anatomy teaching is undergoing pioneering changes. Traditional Vesalius' dissection-based teaching has evolved to include didactic lectures and nowadays incorporates digital teaching, e-learning and a wide range of 3D images and models. Furthermore, the current generation of dental students are using devices like smartphones and laptops for educational purposes.

The focus of this PhD was to assess the efficacy of innovative teaching aids for teaching anatomy to dental students. We hypothesized that innovative tools are effective in enhancing students learning experience and improving academic performance. Firstly, a cranial nerve animation was developed and results show an increase in student's knowledge of the topic after watching the animation (Chapter 2). The teaching of clinical skills was assessed using a soft-preserved cadaver (Chapter 3) which showed promising results. Furthermore, to aid in teaching tooth morphology a 3D quiz application was developed (Chapter 5) and results show that it was effective in teaching tooth morphology to dental students. Additionally, a survey was also undertaken to assess the staff involved in teaching tooth morphology to dental students in the UK and Ireland and the teaching aids employed for teaching and examination of tooth morphology (Chapter 4). Students' feedback and perceptions were also gathered at the end of each study.

The results show that innovative teaching aids can supplement the traditional teaching methods. Furthermore, students benefitted from using the innovative teaching

aids and reported it as a positive learning experience. Hence, accepting the above stated alternate hypothesis that innovative tools were effective in enhancing students learning experience and improved their academic performance.

In summary, the principles of anatomy are best taught through traditional teaching methods which are reinforced by the various innovative supplemental teaching aids available. A blended teaching model has been recommended with traditional methods complimented by innovative pedagogies. The introduction of these innovative technologies is vital in providing educational support to students and are successful when delivered alongside taught lectures and the use of the traditional teaching methods.

CHAPTER 1

General Introduction

Lone M[1], McKenna JP[2], Cryan JF[1], Downer EJ[3] and Toulouse A[1]

[1]Department of Anatomy and Neuroscience, University College Cork, Cork.
[2]Cork University Dental School and Hospital, University College Cork, Cork.
[3]School of Medicine, Discipline of Physiology, Trinity College Dublin, Dublin.

Part of the chapter to be submitted as a review paper to *Anatomical Sciences Education.*

1. Teaching Anatomy to Dental Students

The definition of dental or dentistry students has changed over time and now includes not only students undertaking a dental science degree (bachelor or doctorate depending on the country), but also students working towards dental hygiene, dental therapy or dental nursing qualifications (McHanwell, 2015; Bakr *et al*., 2016). These students will perform oral examination, dental scaling, restorations and minor surgical procedures on patients in the early years of their degree (Brennan and Spencer, 2005; Obrez *et al*., 2011). Anatomical knowledge is therefore an important component of early training to ensure safe clinical practice (Olowo-Ofayoku and Moxham, 2014; Rafai *et al*., 2016). The anatomical subjects generally covered in the first two years of a dental study programme include gross anatomy, neuroanatomy, embryology, histology and dental anatomy (including tooth morphology) (Guttmann, 2003; McHanwell et al., 2007; Gould et al., 2014; ADEE, 2016; Bakr et al., 2016). This perspective has been further supported by the Association for Dental Education in Europe (ADEE) (ADEE, 2016). These anatomy courses are typically delivered on a standalone basis or integrated within the structure of other courses (Guttmann *et al*., 2003). Furthermore, co-teaching of students from the various disciplines has been suggested as a way to increase communication skills and team-work capacity as the students will work together as part of the dental care team (Bakr *et al*., 2016; Amin *et al*., 2017).

An integrated dental curriculum has been widely recommended (Field and Jeffcoat, 1995; Postma and White, 2017). Teaching basic science subjects with clinical skills and problem-based learning has been recommended (Kassebaum *et al*., 2004; Crawford *et al*., 2007; Nadershahi *et al*., 2013), as it introduces vertical integration into the dental curriculum (Snyman and Kroon, 2005; Manogue *et al*., 2011). In institutions where horizontal integration is applied, anatomy is taught in parallel to physiology,

pathology, biochemistry, microbiology and immunology, timing the delivery of topics to provide the learners with a broad overview across several academic disciplines (Snyman and Kroon, 2005). Positive student perceptions on horizontal and vertical integration of pre-clinical skills in the dental curriculum have also been reported (Postma and White, 2017). The European Credit Transfer System (ECTS) drafted in 2006, endorses the vertical and horizontal integration of basic sciences into the dental curriculum (Plasschaert *et al*., 2006). While vertical integration of anatomy is recommended, a recent survey demonstrates that the majority of students (78%) reported an adequate level of anatomy delivered during the initial years of their dental degree, and hence providing sufficient knowledge for the clinical years (Macluskey *et al*., 2012).

A core anatomy syllabus has been developed and published for medical (Tubbs *et al*., 2014) and dental students (Hendricson, 2012; Best *et al*., 2016) to ensure that important anatomical topics are taught to these students.

In the next sections, we aim to ascertain the various anatomy modules taught to dental students, identify the traditional teaching methods commonly used and focus on the innovative pedgogies currently employed to teach dental students.

1.1 Gross Anatomy

Dental students usually study gross anatomy in the first two years of their dental course with a particular emphasis on detailed knowledge of head and neck anatomy (Guttmann *et al*., 2003) and anatomy of the thorax and upper limb (Snelling *et al*., 2003; McHanwell, 2015; ADEE, 2016). Gross anatomy of the head and neck is commonly taught alongside relevant surface anatomy and imaging, to supplement student understanding of important topics related to dentistry, such as the face, neck, temporomandibular joint and the oral cavity (Kondrashova *et al*., 2016). Dental students

benefit from integrated, system-based teaching (Field and Jeffcoat, 1995), and therefore anatomy teaching should be supplemented with physiology and pathology whenever possible (ADEE, 2016).

It is recommended that dental students should be taught together with a focused dental curriculum, as distinct from a general medical anatomy curriculum (Smith *et al*., 2016). This is due to the fact that the anatomical topics, their clinical significance and therefore their relevance to a dental course, would vastly differ from a medical course (Manogue *et al*., 2011; Amin *et al*., 2017). This will also result in distinct teaching pedagogies being used to deliver tailored learning outcomes (Moxham, 2012; Moxham *et al*., 2014).

1.1.1 Anatomy of the oral cavity

As part of a vertically integrated curriculum, dental students commence examining patients early on in their undergraduate training and hence are expected to have acquired an excellent grasp of anatomy and its associated clinical application (Guttmann et al., 2003). Enhanced student knowledge and better learning experience has been reported when students are taught anatomy alongside it's clinical significance and the relevant clinical examinations (Rafai et al., 2016).

1.2 Dental Anatomy

Dental anatomy and tooth morphology are modules normally delivered in the first or second year of a dental science degree (Kilistoff *et al*., 2013). Tooth morphology is taught to dental science students, dental therapy students, dental technicians and dental nurses as these students are expected to identify teeth and develop the ability to recognize and recreate damaged or lost tooth morphology in laboratory and clinical work (Abu Eid *et al*., 2013; Bakr *et al*., 2016). The aims and learning objectives of such modules are to provide basic knowledge on topics including dental terminology, dental

anatomy and dental development, in order to provide a good foundation for the clinical years. Dental students study the morphological features of the teeth to assist in correct identification (Obrez *et al*., 2011). Knowledge of the characteristic anatomical and morphological features of the teeth also assists in the identification and diagnosis of dental anomalies, and furthermore assists in treating dental pathologies (Obrez *et al*., 2011; Bakr *et al*., 2016).

Traditional methods of teaching tooth morphology include studying extracted or plastic teeth with museum specimens and clinical photographs; drawing teeth; tooth carving and wax-ups (simulated tooth repair with wax) (Obrez *et al*., 2011). These activities reinforce the development of psychomotor skills that can later be implemented and utilized in the clinical setting to restore the morphology of the tooth (Abu Eid *et al*., 2013; Lam *et al*., 2015). In addition, innovative pedagogies are being developed to enhance tooth morphology teaching (Salajan *et al*., 2015). Knowledge of root anatomy is also important for performing endodontic procedures and surgical extractions (Ng *et al*., 2008). While students are often eager to learn this taught module, its application is not until the later clinical years (Obrez *et al*., 2011), thus creating a gap between the learning and the application of the knowledge which has been termed as ‘decontextualized technique learning ’ (Obrez *et al*., 2011; Magne, 2015).

1.2.1 Tooth morphology for dental students

Tooth morphology requires visualization (Wallen *et al*., 1997), understanding of the 3D features of the various teeth (Obrez *et al*., 2011), and knowledge of their dynamic interactions with each other (Cantín *et al*., 2015). Dental students need detailed tooth morphology knowledge to aid in identifying the teeth and reproducing and replacing lost tooth structure (Obrez et al., 2011; Bakr et al., 2016).

1.3 Histology/Oral Histology

General histology content is commonly delivered as part of anatomy and/or physiology modules in the first year of a dental degree programme with specialized dental histology (e.g. tooth development, amelogenesis and dentinogenesis) usually taught in the second year of the course (MacPherson and Brueckner, 2003; Johnson *et al*., 2015).

Burk *et al*., (2013) conducted a survey to assess how histology was taught in North American dental schools. Data from the survey shows that approximately half (54%) of primary academic staff teaching histology were based in medical or graduate schools and were non-dental staff (Burk *et al*., 2013), similar to neuroanatomy staff for dental students (Gould *et al*., 2014). Furthermore, the survey reports that the majority of histology content is taught to dental students alone, with a small number of dental students studying histology combined with medical or graduate students. Although, results from the survey report that total hours for teaching histology have reduced overall, histology is still usually taught as a standalone module (Burk *et al*., 2013). Data analysis of the results also demonstrates that the use of microscopes has reduced with the concurrent increased use of virtual or digitized microscopy. Histological topics of oral and basic tissues including tooth histogenesis, enamel, dentine and pulp are very important for dental students and are covered in detail, whereas topics such as twinning and microscopic techniques are covered briefly, if at all (Burk *et al*., 2013). A recent study reports similar results with students failing to perceive the relevance of general histology to their dental career and preferring to use electronic teaching aids to study (Johnson *et al*., 2015).

An interactive histology software presenting high-resolution images of basic and oral histology was provided to first year dental students to evaluate and compare it to

the other histology teaching aids. Students reported a positive learning experience of using the histology software and would recommend it to other students. However, students reported preference for using the traditional teaching methods for performing histology laboratory work (Rosas *et al*., 2012). In contrast, another study reports students as receptive and very interested when introduced to a self-directed, interactive tool for learning histology. Students identified the quiz module as one of the best features of the programme, and stated that the histology programme allowed self-paced individualized learning that was time-effective (MacPherson and Brueckner, 2003).

A recent transition of an oral histology course from traditional lecture format to an online hybrid format demonstrates promising results. Indeed in this study, students had access to online lectures and resources while the examination was conducted on campus, thus formulating a 'hybrid teaching design' (Gadbury-Amyot *et al*., 2013). Results from the study indicate that this approach was a positive learning experience for the students, with the students in the hybrid format performing better in examinations than the students in the previous lecture format. An analysis of the National Board Dental Examination (NBDE) scores revealed that the new method did not have an adverse impact on the students' knowledge and the hybrid system was not detrimental to the learning process. Additionally, academic staff reported increased student interest and engagement in the hybrid format teaching (Gadbury-Amyot *et al*., 2013).

1.4 Oral Embryology

Dental students' embryological education incorporates study of the pre- and post-natal development of the head and neck to understand and appreciate the physiological changes and developmental anomalies (ADEE, 2016). Results from a recent survey assessing embryology teaching in North American dental schools demonstrates that approximately half (54%) of the primary academic staff teaching

embryology were non-dental staff. Embryological topics such as development of the head and neck, including development of the pharyngeal arches and pouches, face, palate, nasal cavity and tongue, along with tooth development and eruption, are clinically relevant for the dental course and are covered in detail by most dental schools (Burk *et al*., 2013).

A survey was conducted by Sperber (2003) to assess embryology teaching in North American dental schools. The low response rate, in the author's opinion, reflects the low level of academic interest in embryology teaching. Some dental schools did not offer any embryology courses, while others offered it as an elective course. Conversely, some schools reported 32-37 hours of embryology modules. Sperber states that the recent scientific developments in gene therapy and stem cell research further reinforces the need for teaching relevant detailed embryology to dental students (Sperber, 2003). He strongly endorses the inclusion of embryology into the dental curriculum and has proposed a recommended list of topics that should be taught (Sperber, 2003). Dudlicek *et al*., (2004) reports similar results regarding genetics education in dental schools in the United States (US). Study of genetics is vital in understanding normal growth and development. Most of the dental schools do not teach genetics while only 15% reported teaching a formal genetics course (Dudlicek *et al*., 2004). Moreover, some schools reported teaching genetics as an integrated course. The importance of embryology and genetic education, developmental conditions and their clinical implications are highly relevant to dental careers (Sperber, 2003; Dudlicek *et al*., 2004).

Indeed, when medical and dental students are exposed to case-based learning or 'patient educators', and are taught the clinical significance of embryology, it motivates them to appreciate the value of genetics and dental embryology in their careers (Renard *et al*., 2015; Moxham *et al*., 2016).

1.5 Neuroanatomy

Dental students are taught neuroanatomy topics including the cranial cavity, neuronal pathways, function of cranial nerves, pain pathways and coordinated movement of the jaw. This is in order to facilitate a deeper understanding of the anatomy and physiology of functional concepts of mastication, swallowing, speech and taste, and how these could be affected in different diseases/conditions (Guttmann *et al*., 2003; McHanwell, 2015). Furthermore, neuroanatomy modules should be integrated with gross anatomy modules covering the head and neck to facilitate a better understanding of their relationship. This teaching approach will promote student interest in learning neuroanatomy and emphasize the clinical relevance of neuroanatomy in their dental practice (Klueber, 2003).

Gould *et al*., (2014) conducted a survey to determine how neuroanatomy was taught in North American dental schools. They found that the neuroanatomy and neuroscience modules delivered were usually merged and integrated as a component of another taught module rather than as a standalone subject. Computer-aided instructions (CAI) were utilized in about half the dental schools. Surprisingly, more than half of schools surveyed stated that neuroanatomy was not taught by an academic in the dental school, but rather by non-dental staff hired to teach neuroanatomy to dental students. This study expressed concern about the possibility of lecturers emphasizing neurosciences topics to the dental students which would be of little clinical relevance to dental practice (Gould *et al*., 2014). This is also supported by Moxham *et al*., (2015) who stated that although dental students require significantly less knowledge of basic neuroanatomy than medical students, there are certain important topics greatly relevant to clinical dental practice. The anatomy of the cranial nerves, their clinical examination and related pathologies are very important for dental students (Klueber, 2003; Moxham,

2012). Furthermore, topics such as craniofacial pain, dental and periodontal innervation, taste sensation and the neurological control of mastication, deglutition and speech, are greatly significant for the dental practice (Moxham *et al*., 2015). Currently, no core neuroanatomy syllabus exists for dental students and hence Moxham *et al*., (2015) recently devised and presented a potential neuroanatomy core syllabus for dental students (Moxham *et al*., 2015).

1.5.1 Teaching cranial nerves to dental students

Cranial nerves are a very important topic for dental students. These nerves have a complex pathway (Nowinski et al., 2012) and are difficult to envision (Sheth et al., 2009). Dental students are required to acquire indepth understanding of the anatomy of these nerves, the relevant clinical examinations and also the ability to diagnose related pathologies (Klueber, 2003).

2. Traditional Methods of Teaching Anatomy to Dental Students

Traditional methods of teaching anatomy encompass various modalities including lectures and practical sessions employing dissection skills, prosection materials, anatomical models and extracted/plastic teeth (Fig 1.1). Anatomy of the jaw and teeth, along with detailed knowledge of the temporomandibular joint, infra-temporal fossa and oral cavity are important topics for the dental students (Moxham *et al*., 2014). Lecturers are required to teach head and neck anatomy, with emphasis on structures clinically relevant for dental students (Guttmann *et al*., 2003). However, there is a shortage of qualified staff with the necessary specialist knowledge available to teach anatomy to dental students (McHanwell, 2015). Communication and interaction

between anatomy staff and dental specialists can ensure vertical integration and teaching of clinically relevant anatomical topics (Manogue *et al*., 2011).

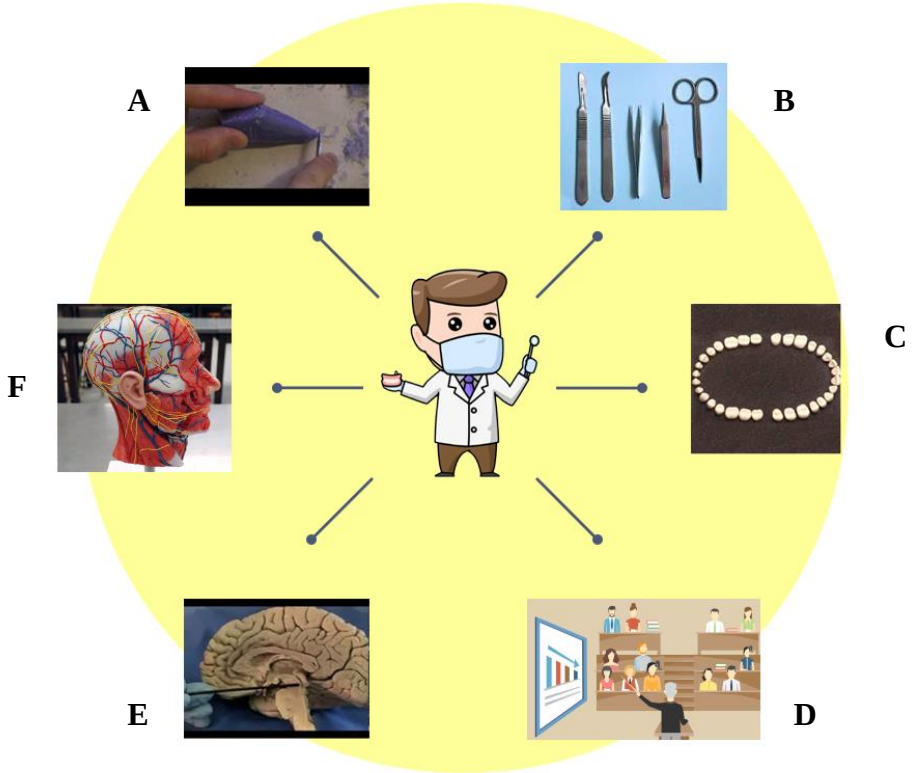

Figure 1.1: Traditional modalities used for teaching anatomy to dental students. A, Carving teeth; B, Dissection skill teaching; C, Studying with extracted/plastic teeth; D, Lecture; E, Prosection teaching; F, Anatomical models.

2.1 Lecture

Traditionally, didactic lectures (Johnson *et al*., 2012; Schonwetter *et al*., 2016) using prepared slides (Shigli *et al*., 2016) are used for delivering anatomy teaching. Bacro *et al*., (2013) used lecture recording, commonly available in lecture theatres, to record lectures of gross anatomy and neuroanatomy (Bacro *et al*., 2013) for dental students. Students' preference of learning styles was assessed at the start of study. Lectures were placed online and student access was monitored. Results show that more than half the students were not accessing the lectures at all, or that fewer than 10 lectures were watched in total. However, a significant co-relation was determined

between the auditory learners, multiple viewings of lectures and their grades (Bacro *et al*., 2013). The study authors suggest that lecture recording could potentially benefit audio learners (Bacro *et al*., 2013).

Park and Howell (2015) introduced a flipped classroom approach for teaching dental anatomy to second year dental students at Harvard School of Dental Medicine. Traditional lectures were replaced with a blended learning model. Instead of a didactic lecture, online course material was provided to students for viewing before class, followed by small-group peer teaching and team discussions under faculty supervision. This blended learning method incorporates e-learning and promotes active student learning (Park and Howell, 2015). Students accessed the foundation information placed online beforehand while the class time was utilized in interactive and engaging discussions and activities. The authors concluded that this method of teaching promoted long-term retention and recall of information and was consistent with the upper levels of Bloom's taxonomy of learning (Park and Howell, 2015). However, the study did not gather data regarding student examination scores and made no comparison of this teaching method to the traditional lectures. Furthermore, the students themselves raised concerns about validity of information provided by their peer and included in this method of learning. It is also recommended that faculty will need to be trained in this particular teaching method (Park and Howell, 2015).

2.2 Dissection- and Prosection-based Teaching

There is an on-going debate about the use of dissection- and prosection-based practical sessions for teaching anatomy. Dissection-based teaching involves the progressive dissection of cadaveric specimens by students, whereas prosection-based teaching focuses on using previously dissected specimens prepared by specialist staff. Learning gross anatomy with dissections/prosections provides visual stimuli and assists

in dental students' acquisition of a better understanding of anatomy (Snelling *et al*., 2003). Dissection-based anatomy has previously been considered the best teaching tool (Aziz *et al*., 2002), while prosection-based teaching is preferred by dental students themselves (Snelling *et al*., 2003; Olowo-Ofayoku and Moxham, 2014). Dissection of head and neck structures can be very tedious and technically demanding, leading to dental student preference of using prosections (Snelling *et al*., 2003). In addition, a recent survey reported that dental students consider tutorials, prosections and textbooks as valuable teaching aids to study anatomy (Snelling *et al*., 2003).

The decision for dissection- or prosection- based teaching is dependent on the availability of healthy cadavers donated for educational purposes (Sugand *et al*., 2010). Number of bodies donated varies across medical schools in different countries with University of Dundee, UK reporting 50 bodies donated per year (Eisma *et al*., 2013), while University of Otago, New Zealand (McClea, 2008) and University College Cork, Ireland (Medical Council, 2017) reporting 40 and 28 bodies donated per year, respectively. The Human Tissue Act in UK aims to regulate all activities involved with human tissue handling including the removal, storage, retention and even use of human tissues and organs for educational purposes (Bell, 2006). An important prerequisite for body donation is full informed consent from the donor. Decision to use a dissection- or prosection- based laboratory is also dictated by the available space and significant cost involved with embalming and running an anatomy laboratory (Robbins *et al*., 2008; Eisma *et al*., 2013) with Philadelphia University quoting a total cost of $200,000 for creating and setting up a new gross anatomy dissection laboratory (Goldman, 2010).

A recent study by Redwood *et al*., (2011) investigated Australian dental students' perceptions during a dissection course. Students' perception of their professionalism, anatomical knowledge and emotional response related to dissection

was assessed at the start, and subsequently at eight-ten weeks into the dissection course. Analysis of data demonstrated that there was no significant change in perception of professionalism of dental students during the dissection course. However, anatomical knowledge and positive emotional responses of the dental students revealed a statistically significant increase during the course (Redwood and Townsend, 2011). Data also indicated that while the majority of students enjoyed dissection, approximately 40% of the student cohort felt that prosections could replace dissection. This is in contrast with the previously mentioned study by Snelling *et al*., (2003) that found that dental students preferred studying using prosections due to the difficulty in dissecting regions of the head and neck (Snelling *et al*., 2003; Redwood and Townsend, 2011). Interestingly, the authors note that the difference in preference may be related to students' relative interest/disinterest in a surgical career (Redwood and Townsend, 2011). Based on these findings, the study concludes that dissection should remain a fundamental part of the dental curriculum as it assists student development into clinicians (Redwood and Townsend, 2011).

2.3 Anatomical Models

Anatomical models are widely used to teach anatomy. Models are easy to use and store, offer long shelf-life and can be used repeatedly (Sugand *et al*., 2010; Johnson *et al*., 2012). Models are frequently used to teach topics such as the cranial nerves (Dickson and Stephens, 2015), which are very difficult to view on prosections (Richardson-Hatcher *et al*., 2014). While models display the superficial and deep anatomical structures, they do not demonstrate anatomical variation and are not a very realistic haptic teaching model (Sugand *et al*., 2010).

2.4 Extracted /Plastic Teeth

Traditionally, extracted teeth are used to study tooth morphology and identify features of the tooth (Mitov *et al*., 2010). Commercial high quality plastic teeth are also available and used to teach tooth morphology (Abu Eid *et al*., 2013). However, plastic teeth are all alike and do not demonstrate detailed tooth anatomy and their variations (Obrez *et al*., 2011). Students, themselves, prefer to study the anatomical morphology using extracted teeth (Abu Eid *et al*., 2013).

An improvement in the oral health of the older generation in most countries has led to a reduction in the number of tooth extractions (McCaul *et al*., 2001; Muller *et al*., 2007; Bernabe and Sheiham, 2014; Kassebaum *et al*., 2014). This improvement in oral health can be attributed to various factors including smoking cessation (Dietrich *et al*., 2015) and oral health literacy programmes (Guo *et al*., 2014). The reduction in tooth extractions creates problems with procuring healthy extracted teeth for teaching purpose (Obrez *et al*., 2011).

Moreover, traditional methods to teach tooth morphology are currently being augmented by innovative teaching methods (Nagasawa *et al*., 2010; Salajan *et al*., 2015) to provide visualization and 3D understanding of the morphological anatomy (Allen *et al*., 2015; Cantín *et al*., 2015).

2.5 Carving Teeth

Carving of tooth models using different mediums, e.g. wax, chalk or soap (Mitov *et al*., 2010) complements the acquisition of detailed tooth morphology knowledge (Obrez *et al*., 2011). It also aids in developing manual dexterity, necessary for building and replacing lost tooth structure to restore dental aesthetics and function (Schroeter, 1959; Abu Eid *et al*., 2013; Lam *et al*., 2015). Eid *et al*., (2012) conducted a study with first-year graduate entry dental students at the University of Aberdeen and

introduced wax tooth carving practical sessions for students, along with tutorials and online resources. Results of the study indicate that students (82%) agreed that carving tasks improved their manual dexterity and found the sessions helpful for understanding the 3D anatomy of teeth (64%) (Abu Eid *et al*., 2013). However, only 55% of the students felt that the carving exercise benefitted their understanding of tooth morphology. The authors also concluded that their graduate entry course is overloaded and hence carving exercises might be optimal for undergraduate courses. The authors recommend carving/recreating only part of a tooth which should not be very time consuming for the students but would still provide them with an opportunity to develop manual dexterity (Abu Eid *et al*., 2013).

A recent study by Kilistoff *et al.,* (2013) focused on introducing and evaluating the effectiveness of a carving exercise for final year dental students. In this study there were three stages to the exercise; pre-test carving with no instructions, followed by practical demonstration from clinical tutors and wax carving under their guidance, and finally a post-test carving exercise without guidance. Three elements were introduced in this pedagogy; “Visual” (pre-practical pictures), “Auditory” (verbal description of the process) and “Kinesthetic” (students performing a wax carving). Data showed that there was a statistically significant increase, with a large effect size, between the pre-test and post-test carving (Kilistoff *et al*., 2013). There was also a medium effect size difference between the participative learning (i.e. with guidance) and the post-test carving (without guidance). This study thus indicates that introducing different learning methods (visual, auditory and kinesthetic) leads to optimal performance by the students (Kilistoff *et al*., 2013).

3. Innovative Methods for Teaching Anatomy to Dental Students

Continuing reductions in the number of teaching hours in anatomy (Drake and Pawlina, 2014) have led to an increase in the use of self-directed learning and small group exercises. Of these approaches, computer-aided learning (CAL) has been found to be both cost effective and extremely accessible (Yeung *et al*., 2011). Medical students are routinely taught with innovative educational methods that have been developed, assessed and are being used in conjunction with traditional teaching methods (Rizzolo and Stewart, 2006; Johnson *et al*., 2012). Furthermore, the widespread access to, and adoption of, technological adjuncts to teaching has strengthened the case for their inclusion in dental curricula (Maggio *et al*., 2012). Dental students have access to the latest electronic learning aids and gadgets (Redwood and Townsend, 2011). Indeed, a recent study in the School of Dentistry at the University of Birmingham found that laptops and smartphones were the devices of choice for dental students, assisting them to study and also to self-test their knowledge (Khatoon *et al*., 2014). What follows is a review of the current literature exploring the use of innovative tools for teaching anatomy to dental students (Fig 1.2).

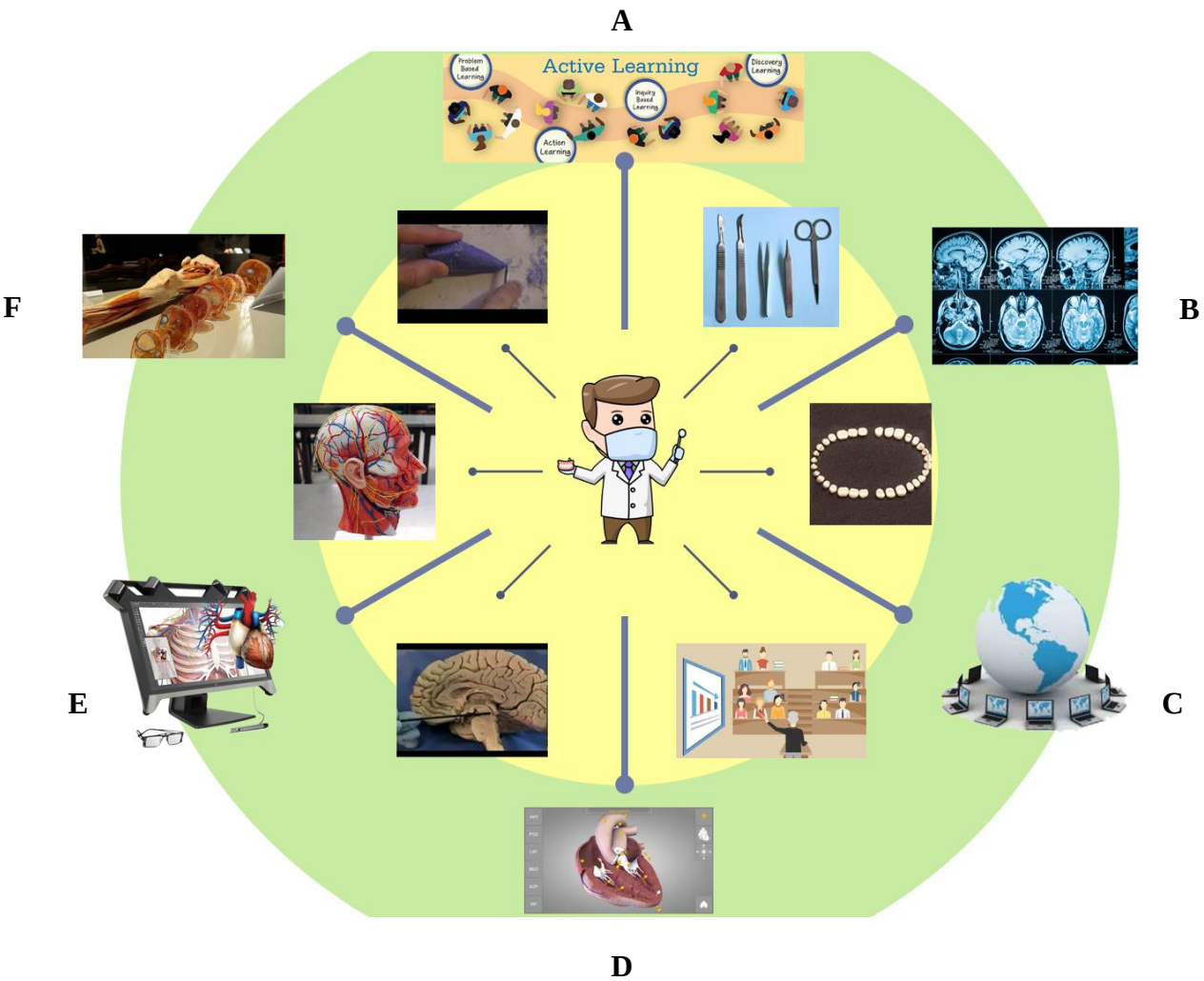

Figure 1.2: Innovative tools supplementing traditional methods to teach anatomy to dental students. A, Problem-based learning; B, Imaging; C, E-learning; D, Animation; E, 3D/Virtual teaching; F, Plastination.

3.1 E-learning

E-learning is a broad term and includes computer-assisted teaching aids (CD and DVDs), online courses and web-based learning (Wright and Hendricson, 2010), amongst others. E-learning offers various advantages; increased access to a greater variety of learning materials, flexibility of learning, control over the pace and sequence of learning, and better visualization. It also provides teachers with a multimedia platform for interactive teaching which is easy to update and improves learning outcomes (Bogacki *et al*., 2004; Wright and Hendricson, 2010; Maggio *et al*., 2012).

Recent advances in technology have facilitated the incorporation of e-learning into the dental curriculum (Mitov *et al*., 2010; Manogue *et al*., 2011) with students preferring to study with online resources (Abu Eid *et al*., 2013). Blended learning techniques are useful for students with different learning styles and have been shown to provide better results (Pereira *et al*., 2007), with improved student satisfaction (Reissmann *et al*., 2015) and improved communication between students and teachers (Wright and Hendricson, 2010).

3.1.1 Web-Based Learning

Dental students have reported smartphone and laptop usage when searching for online educational information (Khatoon *et al*., 2014). When students were asked to choose the top two applications that would be most useful on their smartphones, they chose a dictionary for dental education and multiple-choice questions. More than half the students also reported that having internet on their phones had a positive effect on their studies (Khatoon *et al*., 2014).

Rosenburg *et al*., (2003) developed and introduced an electronic, self-directed histology tutorial for first-year dental students. Results of the study, when compared to the previous students who had studied histology using traditional teaching methods, showed that the intervention led to improved student learning, better results and higher student satisfaction (Rosenberg *et al*., 2006).

3.1.2 Computer Aided Learning

The use of computer-aided design (CAD) and computer-aided manufacturing (CAM) technology has been shown to effectively improve student learning to restore and perform wax-up of teeth (Douglas *et al*., 2014). Bogacki *et al*., (2004) conducted a randomized controlled study, testing the efficacy of a computer-assisted learning programme ‘Tooth Morphology’ against traditional lectures for teaching tooth

morphology. Results indicate that 'Tooth Morphology' was statistically equal to traditional teaching lectures in a cohort of first year dental students at Virginia Commonwealth University (Bogacki *et al*., 2004). Results from this study have led to the replacement of traditional lectures with 'Tooth Morphology' and interactive classroom meetings, as they were perceived to be more interactive and provided students with active control over their learning with regards to the time and pace of learning. Furthermore, it also provided the faculty with increased opportunity to interact with students, provided assistance and reiterated the clinical relevance of dental anatomy (Bogacki *et al*., 2004).

Computer software can also be used to assess students' wax-up of teeth, thus combining traditional and innovative teaching. In a study undertaken by Garret and colleagues (2015), dental students performed dental wax-up which were assessed by the student themselves, the respective faculty and a software-based evaluation tool, and the results obtained were compared. Results suggest that dental students can self-assess their practical work along with faculty supervision. Moreover, the use of evaluation software ensures objective results from the faculty (Garrett *et al*., 2015).

Wright *et al*., (2010) reported results on their study assessing students' use of an interactive tooth atlas DVD. The DVD was offered to first-year, second-year and third-year dental students at University of Texas Health Centre at San Antonio, and provided a comprehensive collection of photographs, radiographs and CT scans of all the teeth. The DVD could be used while studying external and internal features of the tooth, tooth-skull relationship and reviewing anatomy before periapical and implant surgeries. A very low number of students (14%) requested and downloaded the DVD to their laptops. Additionally, after the additive incentive to include atlas-related questions to the examination, this number increased to 43% (Wright and Hendricson, 2010).

Furthermore, the study authors concluded that the atlas was used predominantly by third-year dental students, possibly because they were in their clinical years and could appreciate the relevance of anatomical information provided (Wright and Hendricson, 2010).

3.1.3 Social Media

Social networking websites can help facilitate teaching. Facebook (Arnett *et al*., 2013), YouTube (Knosel *et al*., 2011; Mukhopadhyay *et al*., 2014) and Twitter (Gonzalez and Gadbury-Amyot, 2016) are among the social media websites currently being employed to teach dental students.

Arnett *et al.*, (2013) performed a survey to gather information regarding dental faculty's use of various social media platforms. Data was collected from 221 faculty members from four US dental colleges and one Canadian dental college. The results showed that Facebook was the most commonly used social media network followed by Skype, YouTube, LinkedIn, Twitter, Flickr, Hashable and Digg. Surprisingly, 37% of respondents did not use any social media (Arnett *et al*., 2013). According to the respondents, barriers preventing the use of social media for education were primarily time and privacy concerns, followed by lack of expertise in implementation and uncertainty about the usefulness of social media for teaching. Based on these findings, the study authors suggest that faculties should receive training in using social media for teaching, to complement dental student education (Arnett *et al*., 2013).

YouTube is another media currently being utilized to teach dental students (Mukhopadhyay *et al*., 2014), although its use is underdeveloped and underestimated (Knosel *et al*., 2011). Knösel (2011) assessed the dental videos found on YouTube and separated them on the basis of education with further sorting done on the basis of relevance and most viewed. A large number of dentistry-related videos are currently

available on YouTube including videos on education, advertising and entertainment (Knosel *et al*., 2011). The videos falling under the category of education had suitable information for general public and even dental professionals including dental students. Knösel (2011) concluded that YouTube is a valuable medium offering educational opportunities (Knosel *et al*., 2011). Mukhopadhyay *et al*., (2014) also explored YouTube as an educational forum and created forty videos on the content of anatomy, physiology and pharmacology of local analgesia. These videos were uploaded to YouTube to gather data about their viewings. Data indicated that the videos were watched nearly 71,000 times over an eighteen-month period and accessed primarily by viewers from the US and Australia followed by developing countries (Mukhopadhyay *et al*., 2014). Results also showed that videos demonstrating innervation of the oral cavity, dental syringe, function of local analgesia and dental needles, were watched repeatedly and accounted for 65% of total views, hence showing topics of interest for students. Dental videos available on YouTube can thus be used as an auxiliary tool to access and teach a widespread audience (Mukhopadhyay *et al*., 2014). However, great care must be taken while utilizing the social media forum for teaching medical and dental students (Bosslet, 2011) to ensure authenticity of information and credibility of authors (Knosel *et al*., 2011; Mukhopadhyay *et al*., 2014).

Gonzalez *et al*., (2016) introduced Twitter in a second-year dental radiology course at the University of Nebraska to evaluate students' use and perception of this technology for learning dental radiology. The majority of respondents (95%) in the study did not have a Twitter account prior to the radiology course with only 55% creating an account for the course. The two reasons, indicated for not creating a Twitter account for the duration of the study was the availability of the educational content even without an account and not wanting another online account. The students reported the

Twitter sessions as helpful and providing a platform for interaction with academics (Gonzalez and Gadbury-Amyot, 2016).

3.2 Problem-Based or Enquiry-Based Learning

Problem-based learning (PBL) is defined as an approach in which a problem serves as a stimulus for active student learning (Bassir *et al*., 2014). Teaching basic science subjects with a PBL approach enables students to correlate basic knowledge with clinical scenarios, allowing vertical and horizontal integration of knowledge and leading to better results (Kieser *et al*., 2008; Obrez *et al*., 2011). Guttman (2003) conducted a survey to assess anatomy teaching in dental schools of the US and Canada and found that the majority of schools employ the use of traditional teaching methods to teach anatomy with a few schools using PBL. Guttman (2003) concluded that PBL allows the student to assimilate information and thus provides an in-depth understanding of the problem (Guttmann, 2003). Dental students greatly value the clinical significance of taught anatomy (Olowo-Ofayoku and Moxham, 2014). In a study by Obrez *et al.*, (2011) to improve cognitive and psychomotor skill development of dental students while learning tooth morphology, a revised module was introduced for dental anatomy at University of Illinois at Chicago College of Dentistry. Didactic lectures and tooth morphology practicals were replaced with a new curriculum consisting of digitized material, small-group discussions between the instructor and student and a laboratory exercise developed around the clinical application of restoring the teeth (Obrez *et al*., 2011). The students' academic performance was evaluated and compared to results of the cohort of students who studied with didactic teaching methods. Although there was no statistical difference in cognitive learning as evaluated by final written examinations and objective structured clinical examination (OSCE), there was however, a statistically significant increase in students' psychomotor skill

development and performance as evaluated by their final tooth morphology waxing project (Obrez *et al*., 2011).

McHarg and Kay (2008) introduced PBL or 'enquiry-based learning' as an innovative blended learning environment designed for dental students in the Peninsula Dental School. Students were divided into small groups and provided with case scenarios with a facilitator to guide and direct them. These sessions were self-directed with students 'decoding' the scenario and deriving learning objectives/topics that each individual in the group would research (McHarg and Kay, 2008). At subsequent meetings, each student presented knowledge and information obtained about each aspect of the case. Furthermore, at the end of the meeting, students were presented with an additional case with similar learning objectives. It was expected that the students' knowledge should be applicable to the new case. Educational assessment was two-fold: the student's own learning assessment and the facilitator's assessment of student knowledge. However the student's results were not stated or analyzed although the authors anticipated that the innovative learning method will lead to a cohort of dental students who will be multi-talented, highly skilled and have a better knowledge of dental topics (McHarg and Kay, 2008).

Guttman (2003) provides information about the innovative changes introduced in three North American dental schools to improve student interest in gross anatomy and promote relevance of teaching the anatomy of the thorax and abdomen for dental students. In each school, gross anatomy courses were modified to include one of the following: CAL, integration of the clinical significance of dental anatomy, introduction of student presentations and formative spot examinations. The author states that all three schools included innovative methods in teaching gross anatomy to assist student understanding of the clinical relevance of anatomy in dental practice. Course

evaluations demonstrated student satisfaction with innovative teaching. Students' scores in the anatomical sciences section of the NBDE part 1 also improved (Guttmann, 2003). Moreover, it is expected that the introduced innovations in the teaching curriculum will assist the dental student in appreciating the relevance of gross anatomy in their clinical years and future career (Guttmann, 2003).

Kieser *et al*., (2008) introduced story telling in the clinical dental anatomy component of oral biology course for third-year dental students. This course was taught with interactive lectures, seminars and a PBL component entitled Context Rich Problems (CRP). Story-telling was introduced into the CRP component of the course for half the class while the other half received CRP only. Feedback questionnaires were collected from both groups at the end of the course and the group with story-telling reported statistically higher satisfaction with the course than the other group. The authors concluded that story-telling enabled students to relate to the story/clinical case presented, analyse it better and assists in a real-life learning framework while providing autonomic thinking and reflective learning (Kieser *et al*., 2008).

Miming was introduced to teach cranial nerves to biomedical science students in Victoria University, Australia. The students were given a didactic lecture on cranial nerves followed by a miming lecture. Results show that pre- to post- test improvement was better after the miming lecture than the didactic lectures. Furthermore, the students found miming lectures to be more interactive, engaging and effective in teaching than the didactic teaching method (Dickson and Stephens, 2015).

3.3 3D and Virtual Learning

Recent advances in technology have integrated traditional and innovative teaching pedagogies. There are various advantages associated with using innovative teaching tools including simultaneous visualization by multiple users/students and its

applicability in teaching different topics/modules (Nagasawa *et al*., 2010). Another comparative advantage is using it for educational and clinical training simultaneously (Nagasawa *et al*., 2010). Latest developments in technology have led to teaching dental students via a virtual tooth (de Boer *et al*., 2015), 3D tooth atlas (Nagasawa *et al*., 2010), 3D interactive tooth atlas (Wright and Hendricson, 2010), online 3D tooth atlas module (Salajan *et al*., 2015), development of 3D atlas of teeth using CT and micro CT scanning (Nagasawa *et al*., 2010; Cantín *et al*., 2015) and 3D visualization of the pulp with the layers of enamel and dentine removed (Nagasawa *et al*., 2010; Salajan *et al*., 2015).

The application of fluoride gel (El Tantawi *et al*., 2013) and difficult anatomical topics like cranial nerves (Richardson-Hatcher *et al*., 2014) can be taught to the dental students using avatars and Second Life (El Tantawi *et al*., 2013; Richardson-Hatcher *et al*., 2014). Furthermore, clinical skills can also be taught to the dental students using 3D simulation (Curnier, 2010; Perry *et al*., 2015) including patient simulation (Suvinen *et al*., 1998), dental implant and restoration of 3D simulated tooth (Perry *et al*., 2015). Similarly, Mitov (2010) introduced 3D tooth teaching via *MorphoDent* to the second year dental students at the University of Saarland in Homburg, Germany. 3D models were created by scanning extracted teeth normally used for teaching. Students' perception and effectiveness of the 3D teaching tool was assessed by providing the teaching tool to the students two weeks before the examination. Students were also examined on 3D tooth models along with their traditional examination using extracted teeth. Data from the study showed that while students enjoyed learning with *MorphoDent,* no statistical difference was reported between the results of both examination methods (Mitov *et al*., 2010).

Magne (2015) redesigned the dental morphology and occlusion module at Herman Ostrow School of Dentistry, University of Southern California. Dental morphology teaching with 2D-3D-4D concepts was introduced, implementing learning essential practical and clinical skills. It included drawing 2D images of teeth, followed by performing 3D partial and full wax-up of teeth. Finally, the concept of 4D was introduced with concepts of histoanatomy of enamel and dentine replicated using layered acrylic mock-ups and resin restorations materials. The authors state that the new innovative module introduced a practical and advanced learning method, incorporating dental tissues such as enamel and dentine along with their morphology and function. The author reports increased student and staff satisfaction with the redesigned module and anticipates that it will help students develop deep clinical appreciation for dental morphology, function and aesthetics (Magne, 2015).

Virtual Reality (VR) is defined as computer-generated medical simulation of a 3D image or environment with which a learner interacts in a seemingly real or physical way (Perry *et al*., 2015). Perry *et al*., (2015) reviewed the use of simulation in dentistry and found that haptic enhanced VR simulators are currently being used for assessing periodontal disease, implant preparation, maxillofacial surgery and restoration of 3D simulated teeth. Advantages of using VR for the dental student include clinical skill development before patient exposure and the ability to repeatedly practise procedures until a defined skill set is developed. Further development of VR and haptic-enhanced VR simulations will ensure easier access to this cost-effective teaching modality (Perry *et al*., 2015).

3.4 Newer Preservative Techniques

Formalin is the most commonly and widely used embalming solution but is known to be a known carcinogenic agent (Hammer *et al*., 2012; Swenberg *et al*., 2013).

Newer preservative techniques have therefore been developed which are less toxic (von Hagens *et al*., 1987; Hammer *et al*., 2015) and include plastination (Neha *et al*., 2013) and Thiel embalming technique (Eisma *et al*., 2013).

Plastination is a technique of tissue preservation developed to allow prosections or human material to act as dry, odourless and durable specimens (von Hagens *et al*., 1987). Such specimens represent detailed anatomical structures and are of high instructional value (Neha *et al*., 2013). Plastinated prosections are being used to teach gross anatomy to medical students (Riederer, 2014; Latorre *et al*., 2016) but their use in dentistry is not well documented. Baker *et al*., (2013) replaced traditional methods of teaching anatomy with dissection and introduced plastinated prosections at the New York Dental College for first-year dental students. The plastinated prosections included a large number of cross-sectional slices allowing students to obtain 3D spatial understanding of the anatomical structures while studying in small numbers (Baker *et al*., 2013). Use of the plastinated specimens also allowed students to study in small groups. Improved student satisfaction and better long-term retention of anatomical knowledge were shown, evidenced by improved NBDE scores for dental students when compared to previous years. Baker *et al*., (2013) suggests the use of plastinated specimens to teach gross anatomy, particularly for dental students (Baker *et al*., 2013).

Thiel-embalmed cadavers (TEC) are soft-tissue cadavers with musculoskeletal and haptic properties similar to a fresh frozen cadaver (Eisma *et al*., 2013). Oral tissues including the gingiva, alveolar bone along with neurovascular bundles are well preserved and thus provide an excellent opportunity for dental teaching and research (Holzle *et al*., 2012). TEC have been used to teach various oral surgical techniques like ultrasound guided fine-needle aspiration of the tongue (Meacham *et al*., 2012),

mandibular reconstruction utilizing an iliac crest graft (Grohmann *et al*., 2013) and implants (Peuker *et al*., 2001; Holzle *et al*., 2012).

Recently, TEC were also used to teach tooth extraction to second-year dental students at University of Dundee Dental School in Scotland (Hanson *et al*., 2016). The study was done over a period of four years with students randomly assigned to perform tooth extractions on TEC or on commercially available mannequins. Data from the study showed that the majority of students (92%) felt advantaged for performing tooth extractions on TEC. The majority of students (73%) agreed that tooth extraction on cadaver was more difficult than on mannequin, with 95% of students agreeing that patient tooth extraction was much more difficult in comparison to cadaveric tooth extraction (Hanson *et al*., 2016). Students who performed extractions on TEC reported higher self-confidence levels than students in the mannequin group. The study authors also report that TEC offer a realistic model of teaching clinical procedures to dental students prior to patient interaction (Hanson *et al*., 2016).

Traditional embalming with formalin is relatively easy to perform and a cheaper alternative (Eisma *et al*., 2013). However, formalin is a carcinogenic agent (Swenberg *et al*., 2013) and hence alternative preservation techniques are now available which include soft-preserved techniques. One soft-preservation technique is Thiel embalming which was developed by Walter Thiel (Thiel, 1992) and preserved the tissue colour and texture to closely resemble the living anatomy (Holzle *et al*., 2012). Thiel solution uses a relatively small amount of formalin as compared to regular formalin embalmed cadavers (Eisma *et al*., 2013). However the embalming process is relatively expensive, technique sensitive and time consuming (Wolff *et al*., 2008; Hammer *et al*., 2012). The plastination technique of tissue preservation was developed by Gunther Von Hagens in 1978 (von Hagens *et al*., 1987) and consists of replacing the water and lipids in tissues

with curable polymers leading to hard, odourless and durable teaching specimen while maintaining the intricate anatomy (Sugand *et al*., 2010).

Using alternative preservative technique for embalming allows the students to study anatomy without exposure to high levels of formalin. Plastination offers detailed viewing of the anatomical structures in addition to small group learning. Use of TEC for teaching anatomy and especially clinical procedures ensures the students are confident before they enter the clinical settings (Hanson *et al*., 2016).

3.5 Animation

The use of graphics has been shown to assist understanding, learning and recollection of a theory or concept (Tversky et al., 2002b). Both static (pictures, diagrams and images) and dynamic (videos and animations) teaching modalities are important in simulating and creating an enhanced teaching and learning environment (Wilson, 2015b). Animations have a dual role in teaching: affective as well as cognitive. The affective component of an animation maintains the attention of the viewer, in addition to acting as a motivational tool. In contrast, the cognitive component of an animation is affiliated with understanding (Lowe, 2004a). Students have reported enthusiasm when it comes to the use of technology-based learning courses or modules regardless of their results (Kesner and Linzey, 2005b; Vuchkova et al., 2012).

Animation and multimedia learning resources have been developed to teach dental students topics of histology (Brisbourne *et al*., 2002), temporomandibular joint and inferior alveolar nerve block (Guttmann, 2000) and the morphology of the teeth (Wallen *et al*., 1997). 3D animated teeth were found to be useful for teaching tooth morphology (Mitov *et al*., 2010).

3.6 Imaging (Radiology/ Ultrasonography)

Radiotherapy and radiology are usually taught in the clinical years of dental degrees but the introduction to radiology begins in the first two years of the course (McHanwell, 2015). Radiology is an essential and important diagnostic aid routinely used in dental practice (Baghdady *et al*., 2014). Radiology taught in combination with anatomy offers students the ability to apply basic anatomical knowledge, interpret 2D images and attain 3D visualization and spatial understanding (Baghdady *et al*., 2014). A dentist must learn to identify the normal anatomical features on the radiological film, to successfully differentiate them from pathological changes and reach a correct diagnosis (Vuchkova *et al*., 2012).

A recent study conducted by Ivanusic (2010) introduced ultrasonography to medical, dental and science students while studying cardiac anatomy. During a practical session, a tutorial on ultrasound imaging was delivered followed by an ultrasound of the heart on a student volunteer. Results from a Likert-based questionnaire about the learning experience shows that the majority of the students were enthusiastic while watching this 'living anatomy' and found it beneficial for their learning. Students reported that watching the ultrasound of the heart was an innovative teaching method that reinforced the lecture material and simulated their interest in this subject (Ivanusic *et al*., 2010). Although cardiac anatomy is not clinically relevant for the dental students, this study introduced an innovative 'hands on' teaching method for the students (Ivanusic *et al*., 2010).

Vuchkova *et al* (2010) introduced a computer-oriented dental radiology teaching tool and compared it to the conventional dental radiology textbook. The study included second year and fifth year dental students. Results indicated that a greater number of second year dental students (75%) preferred to use the digital tool over the textbook as

compared to fifth year students (50%). It is stated that second-year students preferred the digital teaching aid as they had not studied the topic whereas the fifth-year students have already studied from textbook and so preferred the textbook. Qualitative data collected shows that the digital tool was interactive, engaged the students and enhanced the learning process for students (Vuchkova *et al*., 2012).

Radiology taught concurrently with anatomy spurs students' interest while also offering a 3D spatial understanding (Baghdady *et al*., 2014).

A summary of the studies employing innovative teaching aids/tools and their major findings are listed in Table 1.1.

Table 1.1: Summary of studies employing innovative tools for teaching anatomy to dental students.

Pedagogy	Intervention	Participants	Major findings	Reference
Web-based learning	Students' use of electronics for learning.	First, second, third and fourth year dental students	Laptops and smartphones were most commonly used for educational purpose.	Khatoon *et al.*, 2014
	Electronic, self-directed histology tutorials.	First year dental students	Comparison to previous cohort of students shows higher satisfaction, improved learning and results.	Rosenberg *et al.*, 2006
Computer Aided Learning	'Tooth morphology'-assessed.	First year dental students	'Tooth morphology' statistically equal to lectures.	Bogacki *et al.*, 2004
	Comparison of student's, faculty's and software's assessment of wax-up of teeth.	First year dental students	Students can self-assess their wax-up. Using evaluation software ensures objective results.	Garret *et al.*, 2015
	3D Interactive Tooth Atlas, Version 4.0.	First, second and third dental students	Request to download DVD was low. DVD used mostly by third year students.	Wright *et al.*, 2009
Social media	Use of social media platforms by dental faculty.	Dental school faculty	Facebook used for personal use. Lack of time, expertise, privacy concerns are reasons for not using social media for teaching.	Arnett *et al.*, 2013
	Assessment of dental videos currently available on YouTube.	NA	Large number of dental videos currently available on YouTube for education, entertainment and advertising purposes.	Knosel., 2011
	Dental videos on local analgesia recorded and uploaded on YouTube.	NA	Videos watched 71,000 times over an 18 month period.	Mukhopadhyay *et al.*, 2014
	Twitter used for oral radiology teaching sessions.	Second year dental students	Students found the Twitter sessions useful and interactive.	Gonzalez *et al.*, 2016
Problem Based Learning	Traditional teaching replaced by a new design curriculum.	First year dental students	No difference in cognitive learning but improvement (p=0.002) in students' psychomotor skill development.	Obrez *et al.*, 2011
	PBL / enquiry based learning introduced in the dental curriculum.	First year dental students	Student results not stated but anticipated that the students will be multi-talented, highly skilled with better understanding.	McHarg and Kay., 2008
	Innovative teaching for gross anatomy.	First year dental students	Clinical relevance of anatomy was appreciated with improved NBDE examination scores.	Guttman *et al.*, 2003
	'Story telling' in clinical dental anatomy teaching.	Third year dental students	Students satisfaction was higher in story telling group ($p<0.001$).	Kieser *et al.*, 2008
Virtual/ 3D learning	'MorphoDent' compared to traditional teaching methods.	Second year dental students	Students found it helpful. No difference in Morphodent and traditional examination methods.	Mitov., 2010
	Review of using simulation in dental education.	NA	VR currently used for assessing periodontal disease, implant, maxillofacial surgery and restoration of 3D simulated teeth.	Perry *et al.*, 2015
	'2D-3D-4D' concept introduced.	Not specified	Increased student and staff satisfaction.	Magne., 2015

Newer preservation techniques	Plastinated prosections replaced cadaver use.	First year dental students	Improved student satisfaction and improved NBDE score.	Baker *et al*., 2013
	TEC used for teaching tooth extraction	Second year dental students	Students who performed extractions on TEC reported better self-confidence.	Hanson *et al*., 2016
Radiological imaging	Ultrasound of heart performed	First year dental students	Students supported using 'living anatomy' and 'hands-on' approach	Ivanusic., 2010
	Computer-oriented dental radiology compared to a dental radiology textbook.	Second year and fifth year dental students	Digital tool was found to be interactive. Second year students preferred the digital tool whereas fifth years preferred the textbook for studying dental radiology.	Vuchkova ., 2010

CAL, Computer aided learning; DVD, Digital versatile disc; NA, Not applicable; NBDE, National Board Dental Examination; PBL, Problem-based learning; TEC, Thiel-embalmed cadaver; VR, Virtual reality; 3D, Three dimensional.

An exhaustive search of the recent literature identified limitations in current research (Table 1.2). Recent advances in technology have paved the way for future research for inculcation of improved innovative teaching methods for further enhancing dental students' learning experience. Such employment of inventive and novel teaching aids will further promote blended teaching approaches for delivering the undergraduate dental curriculum.

Table 1.2: Research gaps identified in literature.

Research area	What has been done	What is required
Anatomy animations for dental students.	Animations of the TMJ and dental mandibular nerve block were developed (Guttmann, 2000).	Animations are required to aid the visualization of difficult anatomical concepts.
Use of soft-preserved cadavers in teaching pre-clinical dental skills.	Tooth extraction was taught to dental students (Hansen *et al*., 2016).	Recommended model is required for teaching local anaesthesia and other clinical skills.
Staff involved in teaching dental students.	Survey on staff teaching oral histology and embryology in North American dental schools (Burk *et al*., 2013).	Assess staff teaching tooth morphology to dental students.
Applications for tooth morphology teaching.	'Tooth morphology'- computer assisted learning programme (Bogacki *et al*., 2004). '3D Interactive Tooth Altas' Version 4.0 (Wright *et al*., 2009). 'MorphoDent'- Web-based learning programme in dental morphology (Mitov., 2010).	An interactive 3D application with quiz and feedback elements to aid in studying tooth morphology.

Research Hypothesis

The hypothesis is that innovative tools are effective in enhancing students learning experience and improving academic performance.

Aims of the Thesis

The overall aim of the thesis was to assess innovative methods for teaching anatomy to dental students. Assessment was based on data obtained about students' knowledge and their learning experience.

Aim 1:

There are very few animations in anatomy specifically for dental students. Cranial nerves are a very important topic for the dental students. Most of the animations, videos and teaching aid currently available for teaching cranial nerves list them in their numerical order. We aimed to develop and assess a cranial nerve animation which was based on a very simple everyday scenario of eating an apple and provided an overview of the twelve cranial nerves. Importantly, the nerves listed in the animation were not in numerical order, rather their order was dictated by the scenario of the animation.

Aim 2:

The literature search showed that there is no recommended model for teaching clinical skills to dental students. Learning clinical skills before patient interaction ensures confidence in the students and reduces chances of clinical mistakes. Formalin-embalmed cadaver offer a suitable teaching medium for gross anatomy visualization. However, they are not suitable for teaching clinical skills as they are hard-fixed and offer limited flexibility. In contrast, newer preservative techniques offer a soft-preserved cadaver which not only resembles living tissue but also offers flexibility and realistic

haptic properties. We aimed to assess Thiel embalmed cadaver, which are soft-preserved cadavers, for teaching oral cavity examination. We also assessed the suitability of TEC for teaching local anaesthesia to dental students.

Aim 3:

Currently, there is no information available on the staff involved in teaching tooth morphology to dental students. Additionally, numerous innovative aids are being employed for teaching tooth morphology in different dental schools. However, there is no documentation of their use for teaching and examination purposes. We aimed to survey the staff involved in teaching tooth morphology in dental schools across the UK and Ireland. Furthermore, we collected and assessed data about the use of the various teaching aids for educational and examination purposes.

Aim 4:

Tooth morphology provides the basis for the dental career and visualization of tooth anatomy which is vital for understanding and learning this topic. Currently, traditional teaching methods are augmented with innovative teaching tools. While a number of tooth morphology software and applications are available to students, they do not offer an interactive quiz with feedback. Our aim was to develop and assess a tooth morphology quiz app that showed the 3D features of the teeth. Students could rotate and view the teeth and study it before submitting their answer for the quiz. Ten random teeth were selected for the quiz. Feedback was provided at the end of the quiz.

CHAPTER 2

A Pipeline to Create Educational Animations for Third Level Education

Lone M[1], Vagg T[2], Cryan JF[1], McKenna JP[3], Downer EJ[4] and Toulouse A[1]

[1]Department of Anatomy and Neuroscience, University College Cork, Cork.
[2]Department of Computer Science, University College Cork, Cork.
[3]Cork University Dental School and Hospital, University College Cork, Cork.
[4]School of Medicine, Discipline of Physiology, Trinity College Dublin, Dublin.

Paper published in *INTED2017 Proceedings*.

Abstract

Animations are used to successfully teach dynamic processes and enhance learning for wide cohorts of students across various disciplines, including chemistry, biological science, medicine, computer sciences and engineering. It is a relatively expensive teaching pedagogy but acts as a valuable education tool, ensuring that controlled information can be delivered at the pace of the learner. Anatomical knowledge is central to dental practice but certain anatomical topics are considered more difficult than others to understand. In particular, cranial nerves (CN) are a difficult topic to understand as their functions are varied and their course is quite complex. While various methodologies have been proposed to support learners, studies have been met with mixed results. The cognitive theory of multimedia learning offers a framework for the development of multimedia learning tools with emphasis on the dual stimulation of sensory channels (auditory and visual) leading to incremental cognitive processing of the message. Since knowledge of the cranial nerves in essential to dental practice and other medical specialties, we developed an animation of the cranial nerves following the framework proposed in the cognitive theory of multimedia learning. As animations are becoming increasingly available, it is important that their development is designed to meet educational and cognitive objectives as well as budgetary restrictions.

We propose a pipeline to create successful educational animations for third level students. We present a case study where the pipeline was used to create a whiteboard cranial nerve animation for dental students.

This pipeline presents six stages for the creation of an educational animation: identifying problem areas, student workshops, inter-disciplinary development team, pilot testing and feedback, improvements and roll out. Each stage is discussed with reference to the cranial nerve animation case study and highlights other considerations for each area.

It is proposed, based on our animation feedback and the results from pilot data collected from the dental students, that the whiteboard animation produced using the pipeline described herein is effective in teaching the selected topic. Considering the time and effort dedicated to the preparation of such teaching aids, it is important that the story board meets the course learning objectives and that the animation supports this while reducing potential distractions. Most importantly, our results demonstrate that the proposed pipeline allows the design and production of an animation in a streamlined manner, reducing the need for multiple iterations of the animation for corrections while anchoring it within the cognitive theory of multimedia learning.

Keywords: Anatomy, animation, cranial nerves, dental students.

Introduction

Anatomy is a foundation discipline of health professional education and has been traditionally taught through lectures using textbooks, lecture notes or visual presentations, and supplemented with dissection laboratories (Turney, 2007). The study of anatomy is perceived as a difficult subject as in addition to a complex nomenclature, the student must also develop capacity to visualise the 3-dimensional relationship of structures that are described and illustrated in 2 dimensions (Hoyek *et al*., 2014). Technological changes and a shift in learning strategies of novel generations of students have pushed anatomy educators to seek and develop innovative strategies to supplement the traditional teaching methods (Roberts *et al*., 2012). Incorporating innovative visual teaching methods has been shown to facilitate and enhance the transition from 2D anatomy learning to 3D visualisation and assimilation of structural relationships (Trelease, 2016).

Neuroanatomy in general and the course and function of the cranial nerves in particular are a difficult topic for healthcare students. These nerves follow an intricate course through the craniofacial skeleton and detailed knowledge of these nerves and their functions is essential for education, clinical practise and research (Nowinski *et al*., 2012). In recent years, a number of educational tools, some incorporating 3D aspects, have been created to demonstrate the anatomy of the cranial nerves and their pathways and to improve understanding of their function (Nowinski *et al*., 2012; Richardson-Hatcher *et al*., 2014). Animations are a particularly effective teaching tool for difficult dynamic subjects as they perform a dual function by maintaining the learner's attention and motivation in addition to a cognitive component (Lowe, 2004c). Mayer developed a series of key principles that, incorporated with his Cognitive Theory of Multimedia

Learning (CTML), favour cognitive processing and reduce extraneous interference (Mayer and Moreno, 2003). The CTML puts emphasis on the use of dual stimulation (auditory and visual cognitive channels) to enhance content processing and retention of information (Figure 1) (Mayer, 2005). Therefore, the CTML is based on the concept that when the visual and auditory pathways are utilized simultaneously, it reduces the load on a single channel leading to better learning (Mayer, 2002b).

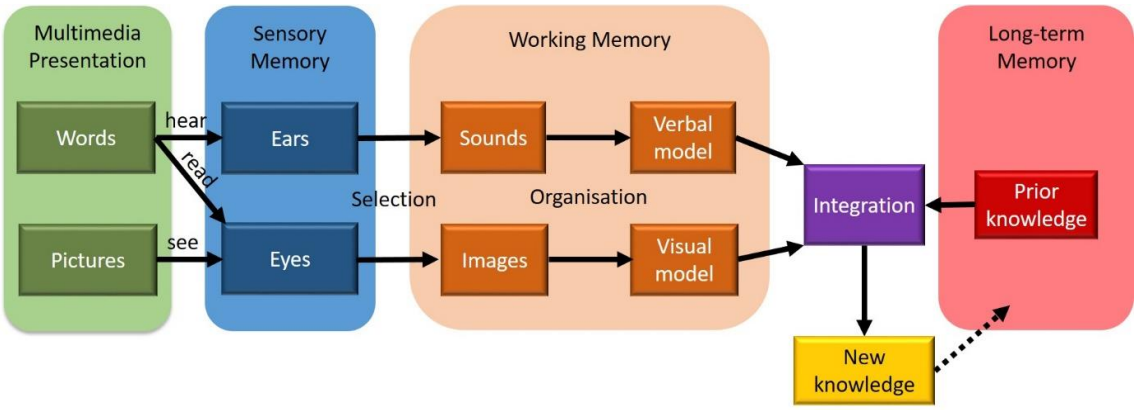

Figure 2.1: Visual summary of the cognitive theory of multimedia learning (adapted from Mayer and Moreno, 2003). Multimedia presentation using language (spoken and written) and pictorial support stimulates both the visual and the auditory processing pathways. Selection and organisation of the auditory and visual cues will form a representation of the content as a visual or verbal model that will be integrated together with previous knowledge stored in long-term memory to generate novel knowledge that will potentially be stored.

Animations based on this theory have been found to be effective tool to teach complex concepts of physiology (Hwang *et al*., 2012), ophthalmology (Glittenberg and Binder, 2006) and even surgery (Bernardini and Davis, 2014).

The aim of our study was to create a simple animation for teaching the anatomy of the cranial nerves. The animation would be based on an everyday life-like scenario incorporating the 12 pairs of cranial nerves. In this paper we propose a pipeline to create a successful education animation for third level students. We also present a case study

where the pipeline was used to create a whiteboard cranial nerve animation for dental students.

Materials and Methods

The process we followed to create our animation can be broken down into a six-stage pipeline. Application of these steps to other educational interventions could simplify animation development and reduce costs. For each step, a case study based on the creation of a cranial nerve animation is also presented.

Identifying problem areas:

Generally, education interventions are created based on the identification of a difficult topic / problem area. These topics / issues can be identified in a number of ways such as reviewing current academic publications, analysing student responses in examinations / tests, end-of-year student feedback or course feedback, and teaching experience. By identifying this problem area / topic correctly and comparing it to the current available teaching modalities, intervention strategies should begin to formulate.

Case Study:

Student feedback is collected at the end of each teaching session to identify areas of difficulty within topics, problems with the course structure or its delivery. A review of the feedback collected for 1st year dentistry students over a number of years revealed that the anatomy of the cranial nerve was constantly identified as a problematic area as students struggled to visualise the course of the nerves and remember their various functions. Review of the literature showed that this topic was highlighted as a difficult topic for dental students (Nowinski *et al*., 2012; Richardson-Hatcher *et al*., 2014). Detailed discussions between the academics involved in teaching this topic led to the decision to develop an animation to supplement the formal delivery of material.

User-driven development workshops:

Feedback and involvement of the target student audience is crucial to the development of a successful teaching intervention. A pilot study introduced miming actions to teach the cranial nerves to biomedical science students (Dickson and Stephens, 2015) and found that the students enjoyed this new and fun learning method where learning changed from instructor demonstration to student participation. A survey done in the University of Cincinnati College of Medicine reported that embryology and renal physiology were the two areas where students repeatedly wanted multimedia tutorials (Marsh *et al*., 2008). Student participation in the early stages of development provide them, the target audience, with an opportunity to direct the intervention and devise means of delivery that are appropriate. These student workshops can take various forms from discussion forums to surveys or one to one interviews

Case Study:

A student workshop was conducted during an anatomy practical session where 1st year dental students were divided into 3 groups and were asked to come up with an everyday life scenario involving all the cranial nerves. Ordinarily the cranial nerves are taught sequentially from 1 to 12. Some of the cranial nerves have complex functions and pathways. For the purpose of this practical students were advised to focus on the primary function of each nerve. Each group was led by an anatomy staff member that did not participate but moderated the discussion. During this session, the staff observed that the students preferentially identified scenarios in which the cranial nerves are not used in the taught sequence but rather according to the use within the situation they depicted. For example, a scenario where a character saw a bakery (CN 2, 3, 4, 6) before

smelling the food (CN 1) and then eating it (CN 5). Each student group was engaged and motivated during this exercise and provided a means of group interaction.

Inter-disciplinary development team:

With a large and rapid increase in scientific knowledge in a wide range of disciplines, there has been a concomitant increase in the need to link these disciplinary fields in order to devise innovative teaching tools to effectively address critical limitations in current teaching designs and facilitate student learning. Hence, there has been a steadily increasing trend within the scientific community; educators, instructional designers and developers to work in liaison with each other and combining their disciplinary skills and perspectives to develop new and innovative teaching methods (Turney, 2007). Such an approach offers a more holistic perspective to the teaching pedagogy, catering for multiple learning styles and allows the tool to address the limitations from a multi-dimensional angle.

Case Study:

For this study, a group including anatomists, dentists and computer science / multimedia experts discussed the topic identified by the feedback analysis and student workshop. This multidisciplinary group also discussed the logistics of the scenario and the feasibility of creating the animation for the topic of cranial nerves. A whiteboard animation type was discussed and approved for this particular animation. It was decided to use a very simple everyday life-like scenario involving all the 12 pairs of cranial nerves functioning not in their numerical order but rather related to the scenario, as shown from the workshops. A storyboard was devised around a scenario incorporating

the 12 pairs of cranial nerves (Figure 2.2). It was further decided to base the animation on the Cognitive Theory of Multimedia Learning.

Time	Focus	Text	Illustration	Snapshot
0.50-1.03 n	Optic nerve	*Stomach growling(sound bite for this)! I'm hungry!Hmm apples* ... The second cranial nerve (optic) carries the sense of vision from retina to the brain.	The Optic nerve fires from retina to the brain,sensory nerve.	
1.04-1.19 n	Occulomotor, T	*Hmmm, Now which apple should I have* ... The various eye movements are a combination of these nerves working together. These nerves run from the brainstem to the muscles of the eye. The occulomotor (the third nerve), the trochlear (the fourth nerve) and the abducent which is the sixth cranial nerve are responsible for the movement of the eye.	The 3 nerves (Occulomotor, Trochlear and Abducent) fire from eye to the brain,motor nerves.	
1.20-1.32 n	Facial nerve	*Ah the perfect red apple.* The seventh cranial nerve (facial) arises in the brainstem and innervates the muscles of facial expression.	Facial nerve fires from the brain to face and in opposite direction,mixed nerve.	

Figure 2.2: Example of the development of the storyboard. Once a general scenario was agreed upon, the focus of each sequence was determined, including the actions and the potential story lines. The animation was designed and the timing and snapshots were incorporated within the storyboard. As modifications were made to the animation, new versions of the storyboard were generated.

Pilot testing and feedback:

Pilot testing and feedback collection are essential to the development of an effective learning tool. Information collected from a focus group of students will provide invaluable initial data and information that could potentially enhance and improve the intervention. Pilot testing could identify potential future problems with the study. Pilot testing also allows initial or trial testing of a particular research intervention such as a questionnaire or interview schedule. Results from the pilot data and feedback should be considered carefully and incorporated if deemed necessary.

Case study:

Following the development and review of the storyboard, the initial draft of the animation was presented to a group of medical demonstrators and anatomists involved in teaching anatomy to a wide cohort of third level education students. The educators

reviewed the animation and provided feedback. The storyboard and animation were revisited and recommended changes incorporated in both.

Students' feedback was also obtained. At the end of an anatomy laboratory session, the animation was presented to the dental students and feedback obtained. There was no audio with the animation at this stage and thus the majority of the students suggested having audio and sound bites (like smelling, stomach growling, chewing, taste) with the animation. The students reported that the animation was well developed; life scenario was easy to understand and follow. Preliminary data collected indicated that the students enjoyed watching the animation and suggested that it should be placed online for easy access as it would help them understand and study for the cranial nerves.

Improvements:

Feedback and pilot data collected during the initial stages of the study help to identify and rectify problems that could potentially arise and limit the usefulness of the animation. Data and feedback obtained should be carefully assessed, considered and where deemed possible incorporated into the study design or intervention. In particular, attention should be paid to Mayer's principles of multimedia learning to curtail any superfluous information or stimulation and optimize the learning experience (Mayer and Moreno, 2003). Once the final draft is ready, the audio tracks should be completed.

Case Study:

Feedback obtained from the anatomists, dental experts and dental students were all discussed with the multimedia specialist and after careful consideration the final animation design was agreed upon (Figure 3). For example, user feedback suggested including musical sound bites to emphasize the action of the auditory nerve. While

Mayer's principles suggest removing extraneous stimulation, this was considered as a reinforcing stimulus and was incorporated into the final version of the animation. Once all modifications were made to the animation, an audio recording of the text was prepared and mixed to the video track. Once again, following Mayer's key principles, we opted for a friendly conversational style rather than a professional style voice over.

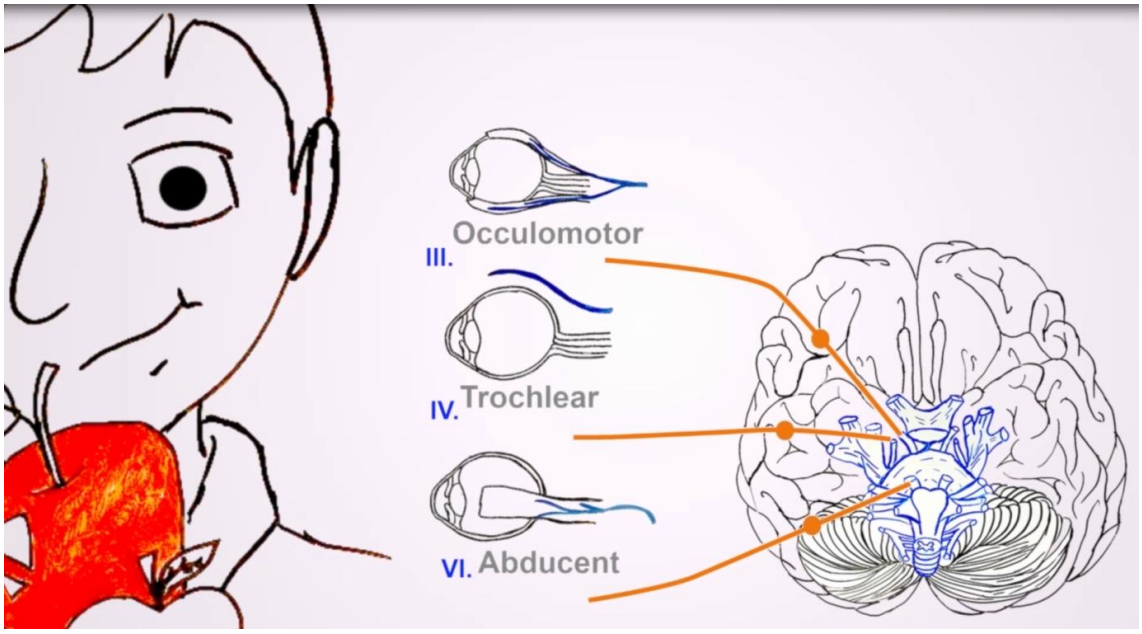

Figure 2.3: Screenshot of the white board animation showing groups of nerves functioning together.

Implementation/ Roll out:

Before full implementation within a teaching curriculum, an animation should be assessed to ensure that it meets its intended educational goal. Obviously, various study designs are possible depending on the objectives and type of information to be collected. Any questionnaires required for the study should be requested or developed and validated. Ethical approval for the study should also be obtained from the required

institution. Participants should be given detailed information about the study and its aims before consent obtained. Following analysis of the data collected, the animation can be fully implemented within the curriculum delivery either as a supplemental aid or to replace traditional delivery.

Case Study:

Two questionnaires were developed to collect pertinent data about cranial nerve knowledge before and after watching the animation. The questionnaires also examined the attitudes of the learners towards multimedia learning and this animation in particular. Students were provided information about the purpose of the study and informed consent was obtained. It was decided to show the participants the animation once in a lecture room and then place it online with open access for two weeks. The animation did not require any plugins and hence was easy to watch. Simple actions like pause, skip, rewind and forward actions could also be performed.

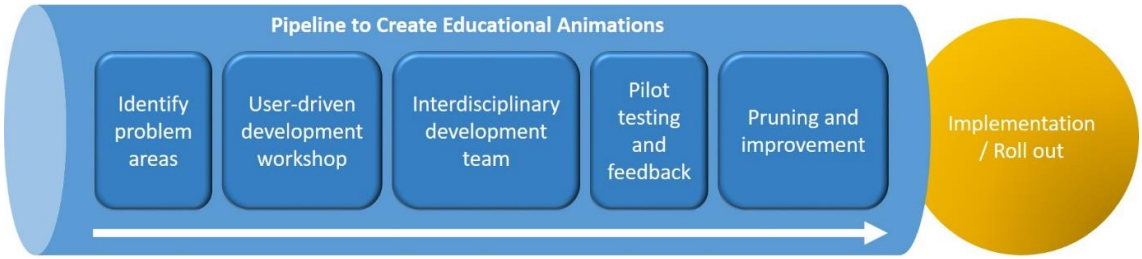

Figure 2.4: Schematic illustration of the pipeline for the creation of an educational animation. The white arrow indicates the directional flow of the process leading to the implementation and roll out of the animation to supplement teaching.

Results

A pilot study was conducted during an anatomy practical session with first year dental students (n=55). Ethical approval for the study was obtained from Social Research Ethics Committee (SREC), University College Cork. Students were provided details about the aim of the pilot study. Participation was voluntary and informed consent was obtained. Participants were shown the animation after which data was collected.

Data collected from the pilot study show that 34 students (62%) agreed that the cranial nerves were a difficult topic to visualize and remember. The majority of the students (n=38; 69%) agreed with the statement that the animation improved their understanding of the cranial nerves. Twenty-eight students (51%) agreed that the animation was easy to understand and 25 (45%) agreed that the pace of the animation easy to follow. Moreover, 29 students (53%) felt that the animation motivated them to learn more about the cranial nerves. More than half the students strongly agreed that the animation can aid the teaching of dental anatomy (n=32, 58%) and should be placed on blackboard as a supplemental teaching aid (n=36, 65%) respectively. Thirty-one students (56%) also agreed that this animation would offer a better understanding of the cranial nerves compared to other neuroanatomy resources and that their dental anatomy knowledge would benefit from integration of the animation.

Discussion

Novel teaching methods can help improve student learning and interest. Our qualitative pilot data shows that dental students enjoyed watching the cranial nerve animation and agreed that it would help them study a difficult topic. The animation can be used in lectures and practical sessions to provide an overview of the cranial nerves with their primary functions. The animation can also be placed online on university web portals thus allowing students to learn the topic at their own pace. Benefits of the animation include its easy availability, provision for repeated viewing and plausibility of the animation.

Conclusion

The aim of this study was to develop a simple animation based on an everyday life scenario presenting an overview of the cranial nerves, as a learning aid for undergraduate dental students. In doing so, we identified key steps in the development process that we consider can form the basis of a pipeline for the efficient development, assessment and implementation of educational supplements. We present results from a pilot study showing that an animation can be effectively used as a supplemental teaching tool and can greatly help the students visualize a difficult or dynamic topic. While there are initial costs associated with creating an animation, it has multiple functions: it can be used during lectures, practical sessions and can be placed online for students to view at their own pace. Further research needs to be conducted to assess the effectiveness of the animation for detailed learning of the cranial nerves.

CHAPTER 3

Evaluation of an Animation Tool Developed to Supplement Dental Students' Study of the Cranial Nerves

Lone M[1], McKenna JP[2], Cryan JF[1], Vagg T[3], Toulouse A[1] and Downer EJ[4]

[1] Department of Anatomy and Neuroscience, University College Cork, Cork.
[2] Cork University Dental School and Hospital, University College Cork, Cork.
[3] Department of Computer Science, University College Cork, Cork.
[4] School of Medicine, Discipline of Physiology, Trinity College Dublin, Dublin.

Accepted for publication in *European Journal of Dental Education.*

Abstract

Introduction: The structure/function of the cranial nerves is a core topic for dental students. However, due to the perceived complexity of the subject, it is often difficult for students to develop a comprehensive understanding of key concepts using textbooks and models. It is accepted that the acquisition of anatomical knowledge can be facilitated by visualization of structures. This study aimed to develop and assess a novel cranial nerve animation as a supplemental learning aid for dental students.

Materials and Methods: A multidisciplinary team of anatomists, neuroscientists and a computer scientist developed a novel animation depicting the cranial nerves. The animation was viewed by newly enrolled first-year dental students, graduate entry dental students (year 1) and dental hygiene students (year 1). A simple life-scenario employing the use of the cranial nerves was developed using a cartoon-type animation with a viewing time of 3.58 minutes. The animation was developed with emphasis on a life scenario. The animation was placed online for 2 weeks with open access, or viewed once in a controlled laboratory setting. Questionnaires were designed to assess the participants' attitude towards the animation and their knowledge of the cranial nerves before and after visualization. This study was performed before the delivery of core lectures on the cranial nerves.

Results: Our findings indicate that the use of the animation can act as a supplemental tool to improve student knowledge of the cranial nerves. Indeed, data indicates that both a single viewing of the animation, in addition to two-week access to the animation, can act as a supplemental learning tool to assist student understanding of the structure and function of cranial nerves. The animation significantly enhanced the student's opinion

that their cranial nerve knowledge had improved. From a qualitative point of view, the students described the animation as an enjoyable and useful supplement to reading material/lectures, and indicated that the animation was a useful tool in understanding the cranial nerves.

Conclusion: Overall, these findings indicate that an animation demonstrating the cranial nerves in a simple, everyday functional scenario, may act as a learning aid in the study of cranial nerves.

KEYWORDS: anatomy education; animation; cranial nerves; dental students; undergraduate education; undergraduate teaching methods.

Introduction

Anatomists are consistently devising innovative strategies for delivering anatomy modules (Hoyek *et al*., 2014), and the conventional methods of teaching anatomy, using both lecture and cadaveric dissection, are becoming supplemented with multimodal teaching techniques such as imaging, computer models/programmes, videos, animations and simulation models (Trelease, 2002; Sugand et al., 2010; Drake and Pawlina, 2014; Wilson, 2015a). Indeed, such developments continue to facilitate the transition of anatomical teaching from two-dimensional (2D) to three-dimensional (3D) (Trelease, 2002), which is important given that visualization is a vital component in education (Pandey and Zimitat, 2007). In particular, data indicates that animation tools are particularly useful in explaining complex dynamic processes or actions (Bodemer *et al*., 2004). Indeed, animations have a dual role in teaching; an affective component that maintains the attention of the student and acts as a motivational tool, in addition to a cognitive component that is affiliated with understanding. The key principles of animation development set out by Mayer favour the retention of information by optimising cognitive processing and reducing extraneous load (Mayer and Moreno, 1998; Mayer, 2002b; Allen et al., 2016).

Data indicates that the use of animations in medical education is essential, not only in teaching, but also in assisting the development of clinical skills (Mehrabi *et al*., 2000; Houck *et al*., 2002), delivering procedural information to patients (Bernardini and Davis, 2014), and promoting horizontal, as well as vertical, integration into curriculum design (Ward *et al*., 2001). Several studies indicate that animations can be employed as supplementary teaching aids of both anatomical and physiological concepts. Indeed, Carmichael and Pawlina (2000) demonstrate that the use of animated PowerPoint™ slides enhances the students' understanding of both gross and developmental anatomy

(Carmichael and Pawlina, 2000). Furthermore, a recent study by Hwang *et al*., (2012) employed the use of animations as a teaching aid to explain dynamic physiological concepts at molecular levels to physiology students, and indicate promising findings (Hwang *et al*., 2012). In support of this, 3D computer animations have been shown to significantly improve the efficiency of demonstrating complex topics in periodontology (Cleeren *et al*., 2014), ophthalmology (Glittenberg and Binder, 2006) and surgery (Bernardini and Davis, 2014). While studies using animations as described above have traditionally targeted well-defined topics and generally demonstrated positive results, other studies have investigated the use of multimedia learning tools in anatomy teaching, showing mixed outcomes. Pereira *et al.*, (2007), Hisley *et al*., (2008) and Keedy *et al.*, (2011) demonstrated that the use of purpose built 3D teaching tools is beneficial for the learners, particularly when used in a blended learning environment (Pereira *et al*., 2007; Hisley *et al*., 2008; Keedy *et al*., 2011). On the other hand, Saltarelli *et al.* (2014) demonstrated that the use of a broad distribution anatomy dissection tool provided poorer support to student instruction than cadaver-based teaching (Saltarelli *et al*., 2014). While some debate continues as to the usefulness of 3D tools, the emerging conclusion from the literature is that appropriately designed animation tools are beneficial in supplementing the acquisition and retention of knowledge in medical education (Ruiz *et al*., 2009; Yue *et al*., 2013).

The cranial nerves follow an intricate course through the craniofacial skeleton, and knowledge of the cranial nerves, their nuclei and their anatomical relationship with the surrounding structures in a 3D realm, is vital for the anatomical foundation required for education, clinical practice and research (Nowinski *et al*., 2012). Indeed, an understanding of the anatomy and function of the cranial nerves holds value for many dental and medical specialties. However, the structure and function of the cranial nerves

is a complex topic, which is difficult for students to understand and visualize by exclusively using textbooks and anatomical models as learning tools (Sheth *et al*., 2009; Dickson and Stephens, 2015). A number of 3D educational supplementary teaching aids/tools have been created to demonstrate 3D views of the cranial nerves and their pathways (Kakizawa *et al*., 2007; Nowinski *et al*., 2012; Yeung *et al*., 2012; Allen *et al*., 2016), and these aids/tools benefit student learning and self-assessment in clinical neurology and surgery (Nowinski *et al*., 2012). In support of this, Yeung and colleagues (2011) have shown that the superimposition of 3D pathways of the cranial nerves on the skull, brainstem and thalamus, enhances teaching and visualization of these structures (Yeung *et al*., 2011). Further new teaching modalities, including a Cranial Nerve Skywalk (a 3D animation of the cranial nerves) (Richardson-Hatcher *et al*., 2014) and the use of miming to teach cranial nerves (Dickson and Stephens, 2015), indicates that novel teaching strategies can promote student teaching and interest, which improves the student learning experience in cranial nerve structure and function.

The hypothesis of this study is that an animation demonstrating the function of the cranial nerves in a simple, everyday scenario, would act as a learning aid in the study of cranial nerves. Students have reported enthusiasm regarding the use of technology-based learning courses or modules regardless of their results (Kesner and Linzey, 2005a; Vuchkova et al., 2012). Given previous reports indicating that animations are particularly useful in promoting student learning of complex topics (Bodemer et al., 2004; Lowe, 2004b), including the cranial nerves (Richardson-Hatcher *et al*., 2014), this study aimed to develop a new cranial nerve animation for use by dental students that captures the use of the nerves in an everyday scenario (ie eating an apple). The objectives of the animation were threefold: (a) to demonstrate the sensory and motor function of the twelve pairs of cranial nerves using a simple animated

scenario; (b) to determine whether the animation tool was successful as a supplemental resource in assisting dental students with their understanding of the cranial nerves; (c) to investigate students' perceptions regarding the use of animations to teach the cranial nerves.

Materials and Methods

Animation Production

A multidisciplinary team of anatomists, neuroscientists and a computer scientist developed the core content of the animation using a variety of sources including core textbook content. The animations are time-singular representations according to Ainsworth and VanLabeke (2004), displaying one or more variables at a single instant in time (Ainsworth and Vanlabeke, 2004). To facilitate assimilation of the information conveyed, the animation was developed following the key principles of Mayer's cognitive theory of multimedia learning (Mayer, 2002b). This animation selection allows complex information to be conveyed and involves many interacting elements. In brief, the delivery of the key concepts is strengthened by delivering the information through the simultaneous use of two sensory modalities (visual and auditory in the case of animations). Extraneous cognitive processing was reduced by a thorough review process by repeated viewings by the dentist, anatomist and senior medical demonstrator. Distractors such as superfluous colours, animations and sounds were reduced to a minimum. When distractors were present, these were used to focus the attention of the viewer, such as music playing when discussing cranial nerve (CN) VIII (vestibulocochlear nerve), or differential colouring of sensory, mixed and motor nerves. The scenario and text were kept simple and the description matched the animation. The text were simple words (easy language) used to reinforce visual elements of the animation. Furthermore, the information was organised in short segments, favouring integration of information. The simple life scenario was demonstrated using a cartoon-type animation with a viewing time of 3.58 minutes (https://drive.google.com/file/d/0B4h4_-rrLDa-NmF1eVY3V0dxcnM/view?pli=1). The animation depicted the use of all 12 pairs of CNs while conducting the everyday task of

eating an apple. The scenario involved smelling the apple (CN I; olfactory nerve); moving the eyes to locate the apple (CN III, IV, VI; oculomotor, trochlear and abducens nerve, respectively); observing the apple (CN II; optic nerve); turning the head to pick up an apple (CN XI; accessory nerve); smiling (VII; facial nerve), reaching for the apple and hearing music (VIII; vestibulocochlear nerve); biting (V; trigeminal nerve), tasting (VII, IX, X; facial, glossopharyngeal and vagus nerve, respectively), producing saliva (VII, IX; facial and glossopharyngeal nerve), rolling the bolus around in mouth (XII; hypoglossal nerve), swallowing the apple (IX; glossopharyngeal nerve) and shrugging the shoulders (XI; accessory nerve) (Appendix 1).

The animation was pilot tested by second-year dental students (n=55) at University College Cork. Pilot data was collected during an anatomy practical session with the students asked to come up with an everyday scenario involving all the 12 pairs of cranial nerves. From this pilot study, feedback forms and qualitative data were collected (Appendix 16). Recommendations from the pilot data were subsequently incorporated into the storyboard to improve the animation. Following content development, a script and animation layout was developed. Pictures were drawn on a whiteboard and then photographed for editing. The images were then imported into Explee (Explee, Paris, France) to create the hand drawn effects. The completed animation file was then imported into Adobe Premiere, CS6 (Adobe Systems Inc., San Jose, CA) where short animations created in Adobe Photoshop, CS6 (Adobe Systems Inc., San Jose, CA) were inserted along with audio files produced for the voice over narration using Audacity 2.1.1 (Audacity, Pittsburgh, PA). The animation contained educational segments and commentary from the narrator.

Curriculum and Study Design

A descriptive quantitative longitudinal study design was used. Newly-enrolled first-year dental students undertaking anatomy modules in the Department of Anatomy and Neuroscience at University College Cork, Ireland were invited to participate in this study. The anatomy curriculum taught to first-year dental students within the Department of Anatomy and Neuroscience includes 36 hours of lectures and 32 hours of cadaveric prosection practical laboratory focused on head and neck anatomy and basic neuroanatomy (role and course of the cranial nerves), and this is based over the duration of two semesters. The class typically consists of 14 students from the Diploma in dental hygiene programme, and 50 students from the Bachelor in Dental Surgery (BDS) degree programme. The latter group is divided into graduate entry and direct entry students. The graduate entry programme is a shortened version of the BDS degree targeted at North American graduates with a B.Sc. in a biological sciences programme. In addition to those, the five-year BDS programme typically hosts 25-30 students from the Irish school system, 5-8 students from other countries and 2 mature students. This module is supported by the university's web-based learning portal, which allows student access to lecture/practical laboratory notes, learning resources and announcements are provided to the students prior to attending both lectures and laboratories. The anatomy curriculum delivered to first-year dental students is assessed by a combination of topographical anatomy short-answer questions continuous assessment, topographical anatomy spot examination and formal written examination. Informed consent was obtained from each participant and the study received ethical approval from the Institutional Social Research Ethics Committee (SREC) (Appendix 5). Enrolment in the study was voluntary and participants were informed that participation would have no effect on their academic results as examination was anonymized. All participants were informed

of the purpose and duration of the study (Appendix 6). All students remained in the classroom for the duration of the survey and no student left the classroom early.

A pre-animation questionnaire was completed in a standard lecture room during an academic day at the start of the academic year, at a point when students had no prior knowledge of the topic (Appendix 2). Following completion of the pre-animation questionnaire, the students observed the animation in a standard lecture theatre. Two cohorts of students were assessed. For the first cohort the animation was then placed online for two-weeks with open access. During this period, the students did not undertake lectures or practical classes on any topic pertaining to the cranial nerves. After two-weeks, the study participants were invited to complete the post-animation questionnaire in a standard lecture room during an academic day (Appendix 3). Forty-two students completed both pre- and post-animation questionnaires. In the second cohort, consisting of 60 students, the students viewed the animation once in a practical laboratory setting, without access to any other learning resource. After viewing the animation once, the study participants were immediately invited to complete the post-animation questionnaire in the practical laboratory setting (Appendix 4). Printed questionnaires were handed out to the participating students at the beginning of each assessment and collected at the end of the sessions. Students attempted and self-administered all the questions.

Questionnaire Design

There was no validated questionnaire available for cranial nerve assessment; hence new questionnaires were developed based on the information presented in the animation, and are presented in Appendices A and B. The questionnaires were designed using SurveyMonkey (SurveyMonkey Inc, Palo Alto, CA) by a multidisciplinary team of anatomists, neuroscientists and dentists, all of whom are actively involved in teaching

anatomy. A closed format was used, predominantly utilizing multiple-choice questions for ease of analysis. Rank-style questions, Likert-style statements and binomial (yes/no) questions were also utilized. All questionnaires were approved by SREC. The pre-animation questionnaire comprised a total of 30 questions and data collected pertained to student demographics, cranial nerve knowledge and opinions regarding different anatomical pedagogies. The post-animation questionnaire comprised a total of 38 questions and data collected pertained to the use of the animation, opinions about different teaching pedagogies and cranial nerve knowledge. For validating the questionnaire, invitations were sent to senior medical demonstrators in the Department of Anatomy and Neuroscience at University College Cork, Ireland, to participate in a trial run. A focus group session was also organized with the medical demonstrators to discuss their feedback on the questionnaires. Questions were modified based on the feedback session.

Participants

The demographics of the study population are outlined in Table 3.1. Overall, 102 students completed both the pre- and post-animation questionnaires, and hence were included in statistical analysis. Approximately two-thirds (69.6%) of participants were female, and the mean age of the study participants was 21 years. Of these, 57.8% were of European origin, with students from Canada, the Middle East and Asia accounting for the remainder of the study cohort. Eighty-three of these participants were dental students (64 direct entry, 19 graduate entry) and 19 participants were dental hygiene students. Forty-two participants (41.2%) had previously completed a third level degree and sixty-six (64.7%) students indicated that they had heard of the cranial nerves prior to the study.

Table 3.1: Demographic data on participnts entry to study.

	Two-week open access to animation	Single viewing of animation
n	42	60
Sex (F/M)	27/15	44/16
Age (years; mean ± SEM)	21.2 ± 3.9	21.8 ± 3.8
Region of origin		
Europe n (%)	23 (54.7)	36 (60)
Canada n (%)	8 (19)	15 (25)
Asia n (%)	10 (23.8)	7 (11.6)
Middle East n (%)	1 (2.4)	2 (3.3)
Direct entry dental students n (%)	30 (71.4)	34 (56.7)
Graduate entry dental student n (%)	6 (14.3)	13 (12.7)
Dental hygiene student n (%)	6 (14.3)	13 (12.7)
Education level completed		
Secondary n (%)	25 (59.9)	33 (55)
Third level n (%)	15 (35.7)	27 (45)
Not specified n (%)	2 (4.8)	0 (0)

Number of student responses (n) = 102

Data Analysis

Data were coded and anonymized, and were then entered manually into Microsoft Excel spreadsheets. Data were then exported to the Statistical Package for Social Scientists (SPSS), version 22 (IBM Corp., Armonk, NY). Frequency and percentages were used to summarize the data. Total scores (pre- and post-animation) were computed by determining the percentage of correct answers. Non-responsive data (left blank) was regarded in the same way as those who ticked “don't know”, and was awarded a 0 score. Paired Student’s *t*-test was performed to compare total scores before and after the animation. Data were analyzed using one-way analysis of variance (ANOVA) as appropriate. When analysis by ANOVA indicated significance ($p < 0.05$), the *post hoc* Student Newman–Keuls test was used. Data are reported as means ± standard errors of the mean (S.E.M). Differences with a p value less than 0.05 were considered statistically significant.

Results

Student Use of the Animation to Supplement Understanding of Cranial Nerves

Figure 3.1 demonstrates results from the cranial nerve knowledge questionnaires collated at both an interval of two-weeks (Fig. 3.1A) and after a single viewing (Fig. 3.1B), pre- and post-animation. Following two-week open access to the animation, knowledge of the cranial nerves significantly improved in 6 out of 17 questions gathering information regarding cranial nerve knowledge. Indeed, identification of the number of cranial nerves significantly improved post-animation (73.8% correct answer) when compared to the percentage correct answer prior to watching the animation (16.7% correct answer) ($p < 0.001$; Fig. 3.1A). Similarly, results showed a significant increase in the percentage correct score on questions regarding trigeminal nerve branches (35.7% pre-animation *versus* 61.9% post-animation; $p < 0.05$; Fig. 3.1A), sensation of smell (42.9% pre-animation *versus* 78.6% post-animation; $p < 0.001$; Fig. 3.1A), sensation of balance (38.1% pre-animation *versus* 59.5% post-animation; $p < 0.05$; Fig. 3.1A) and nerve supply to the muscles of the neck (2.4% pre-animation *versus* 16.7% post-animation; $p < 0.05$; Fig. 3.1A). No student indicated the correct response to the question “which nerve(s) supplies the muscles of the eye” prior to observation of the animation (Fig. 3.1A). Interestingly, access to the animation for 2 weeks significantly enhanced the percentage correct score to this question (0% pre-animation *versus* 23.8% post-animation; $p < 0.001$; Fig. 3.1A).

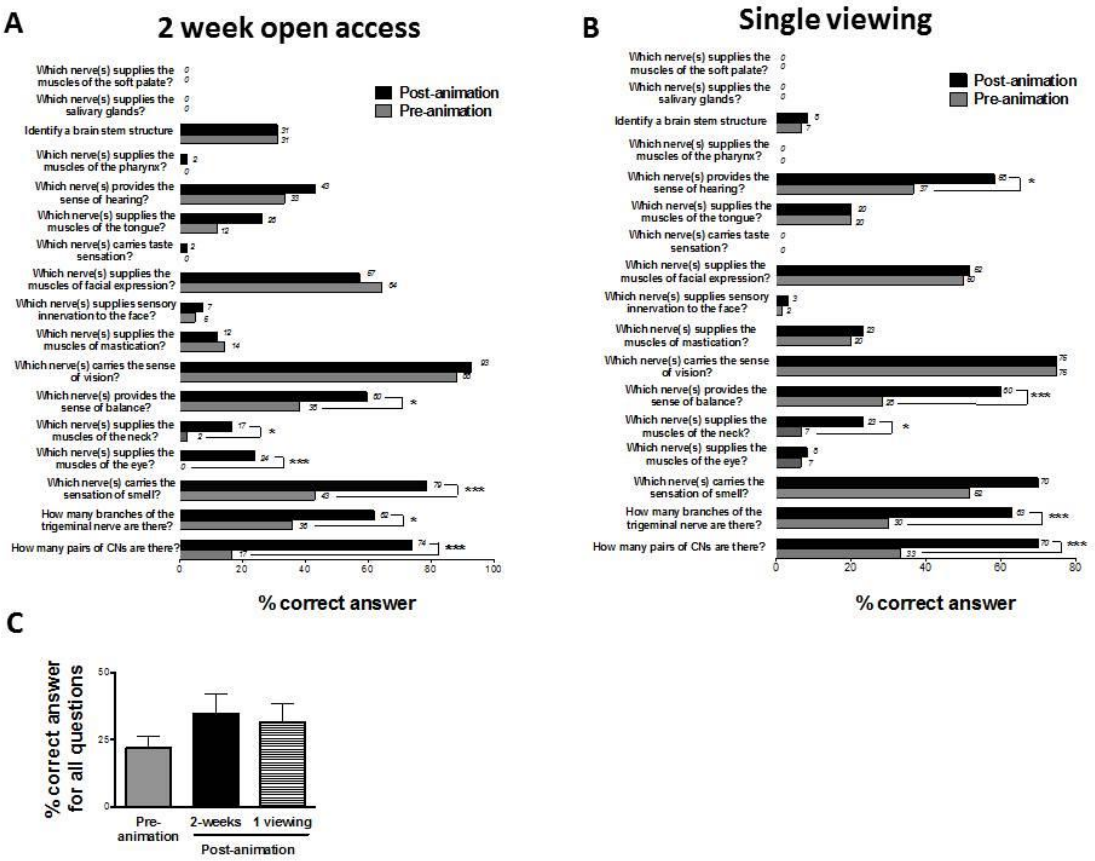

Fig. 3.1. Student knowledge of cranial nerves after watching the animation. (A) Graph demonstrating the percentage correct score (pre- and post-animation) to 17 individual questions relevant to cranial nerve structure and function following open access to the animation for a two-week period. Significant improvements were determined post-animation in terms of identification of the number of cranial nerves and trigeminal nerve branches, neural control of the sensation of smell and balance, nerve supply to the muscles of the neck and nerve supply to the muscles of the eye. (B) Graph demonstrating the percentage correct score (pre- and post-animation) to 17 individual questions relevant to cranial nerve structure and function following a single viewing within a practical laboratory setting. Significant improvements were determined post-animation in terms of identification of the number of cranial nerves and trigeminal nerve branches, neural control of the sensation of hearing and balance and nerve supply to the muscles of the neck. (C) Graph demonstrating the percentage correct score (pre- and post-animation) to all 17 questions (collated together) relevant to cranial nerve structure and function. Data are presented as the mean ± S.E.M. for 102 students. $*p < 0.05$, $***p < 0.001$ compared with percentage correct score pre-animation. CN = cranial nerves.

Data also indicates that a single viewing of the animation can act a supplemental learning tool to assist student understanding of the structure and function of cranial nerves (Fig. 3.1B). Indeed, after watching the animation once in a laboratory setting, knowledge of the cranial nerves significantly improved in 5 out of 17 questions gathering information regarding cranial nerve knowledge. Indeed, identification of the number of cranial nerves significantly improved post-animation (70.0% correct answer) when compared to the percentage correct answer prior to watching the animation (33.3% correct answer) ($p < 0.001$; Fig. 3.1B). Similarly, results showed a significant increase in the percentage correct score on questions regarding trigeminal nerve branches (30.0% pre-animation *versus* 63.0% post-animation; $p < 0.001$; Fig. 3.1B), sensation of hearing (36.7% pre-animation *versus* 58.3% post-animation; $p < 0.05$; Fig. 3.1B), sensation of balance (28.3% pre-animation *versus* 60.0% post-animation; $p < 0.001$; Fig. 3.1B) and nerve supply to the muscles of the neck (6.7% pre-animation *versus* 23.3% post-animation; $p < 0.05$; Fig. 3.1B).

In support of this, the total percentage correct answer across all 17 questions relating to cranial nerve anatomy prior to viewing the animation was 22.1% ± 4.1% (mean ± S.E.M.; Fig. 3.1C). Following access to the animation for two-weeks, the total percentage correct across all 17 questions was 34.6% ± 7.4% (mean ± S.E.M.; Fig. 3.1C). Similarly, the total percentage correct across all 17 questions was 31.5% ± 7.2% (mean ± S.E.M.; Fig. 3.1C) following a single viewing of the animation. This indicates that the percentage correct score improved overall by 12.5% and 9.4% following two-week open access to the animation and a single viewing of the animation, respectively.

Student Use of the Animation Tool During Open Access

In a cohort of 42 students, the animation was posted online for two-weeks and following this period a post-animation questionnaire collated information on the

frequency of use of the animation (Fig. 3.2A), devices used (Fig. 3.2B), location (Fig. 3.2C), time of day (Fig. 3.2D), watching alone or in a group (Fig. 3.2E), and finally, whether they watched the animation before, after or during study (Fig. 3.2F). Overall the vast majority of participants (90.5%) reported watching the animation during this two-week period (Fig. 3.2A). When asked about the frequency of use of the animation, 73.8% of students indicated that they watched the animation once (1.10 ± 0.09 views of the entire animation; mean ± SEM), 14.3% of students indicated that they watched the animation twice, one student indicated that they watched the animation three times, while four students indicated that they did not watch the animation (Fig. 3.2A). When asked about watching clips (sections or subsections of the entire animation) of the animation, 14.3% of students indicated that they watched two or more clips from the animation that included mastication, facial expression, swallowing and the origin/function of the cranial nerves (1.10 ± 0.31 viewings of clips of the animation: mean ± SEM; Fig. 3.2A). Two students watched 9 clips of the animation (Fig. 3.2A). The majority of the students (60.0%) selected a computer as the device to observe the animation, while laptops (27.5%), mobile phones (2.5%), tablets/iPads (7.5%) and other devices (2.5%) comprised the remainder of the platforms used to watch the animation (Fig. 3.2B). Furthermore, the animation was watched mostly on university campus (71.4%), while students indicated that they also watched the animation at home (21.4%) and while commuting (2.4%) (Fig. 3.2C). The majority of the students (75.0%) watched the animation in the morning, while the remaining students watched the animation in the afternoon (12.5%), evening (7.5%) and at night (5.0%) (Fig. 3.2D). Further analysis demonstrates that approximately half the respondents watched the animation alone (52.4%) whereas half (47.6%) watched the animation with classmates and (or) in a study group (Fig. 3.2E). Finally, 67.5% of students indicated that they would watch the

animation before studying for the topic, while students also indicated that they would observe the animation while (17.5%) and after (12.5%) studying the cranial nerves (Fig. 3.2F). Since the animation was watched once in a controlled environment by the second cohort of students, this data is not presented here.

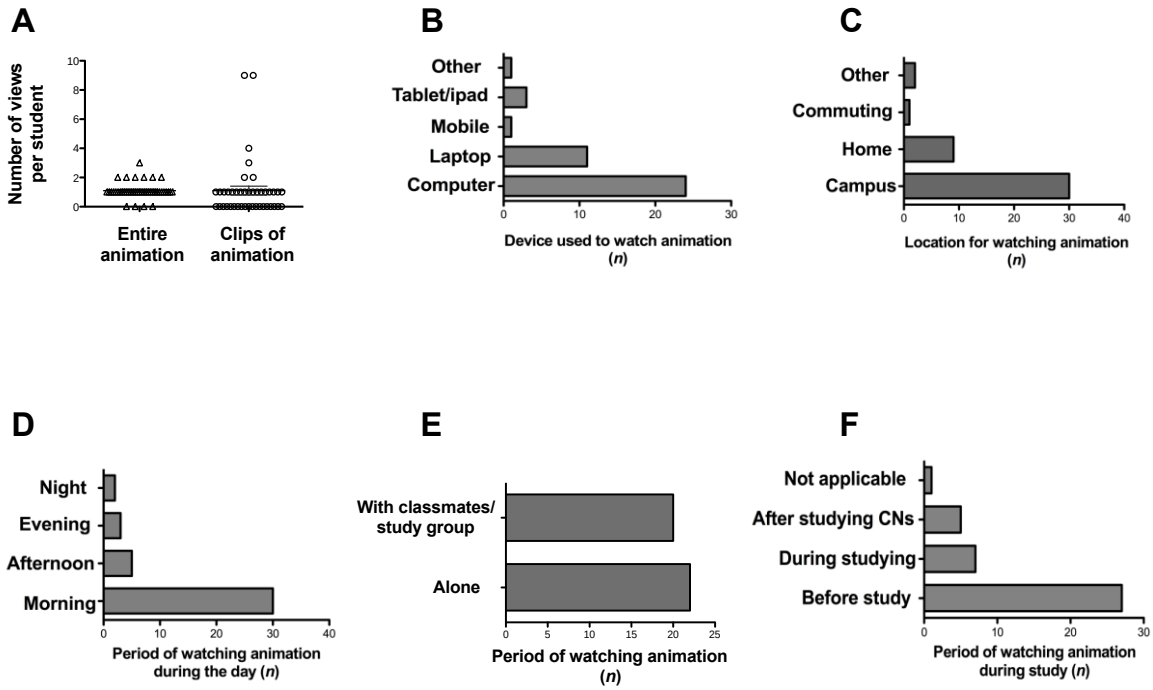

Fig. 3.2. Students' use of the cranial nerve animation tool during an two-week open access period. Graphs demonstrating (A) the frequency of observation of the entire animation or clips of the animation, (B) the device used to observe the animation, (C) the location in which the students watched the animation and (D) the period of day the animation was observed by the study participants. Graphs indicating (E) whether students observed the animation alone or in a study group, and (F) the period of watching the animation relative to the study topic. (A) Data are presented as the mean ± S.E.M. for 42 students. CN = cranial nerves.

Student's Opinion and Perception of the Cranial Nerve Animation as a Supplemental Learning Tool

Study participants were asked to rate their knowledge of the cranial nerves, expressed in a five-point Likert scale (5 = excellent knowledge and 1 = no knowledge), both pre- and post-animation (Fig. 3.3A). Prior to observation of the animation, the majority of students (89.2%) indicated that they had poor or no knowledge of the topic, 8.8% of students reported an average knowledge and 2.0% reported good knowledge of the topic. Data indicates that the animation significantly ($p < 0.001$) enhanced the student's opinion that their cranial nerve knowledge had improved. Indeed, 57.8% of students felt that their cranial nerve knowledge had improved and this is reflected in a significant increase in mean Likert scale score from 1.64 (± 0.07 S.E.M.) pre-animation, to 2.42 (± 0.09 S.E.M.) post-animation ($p < 0.001$; Fig. 3.3A).

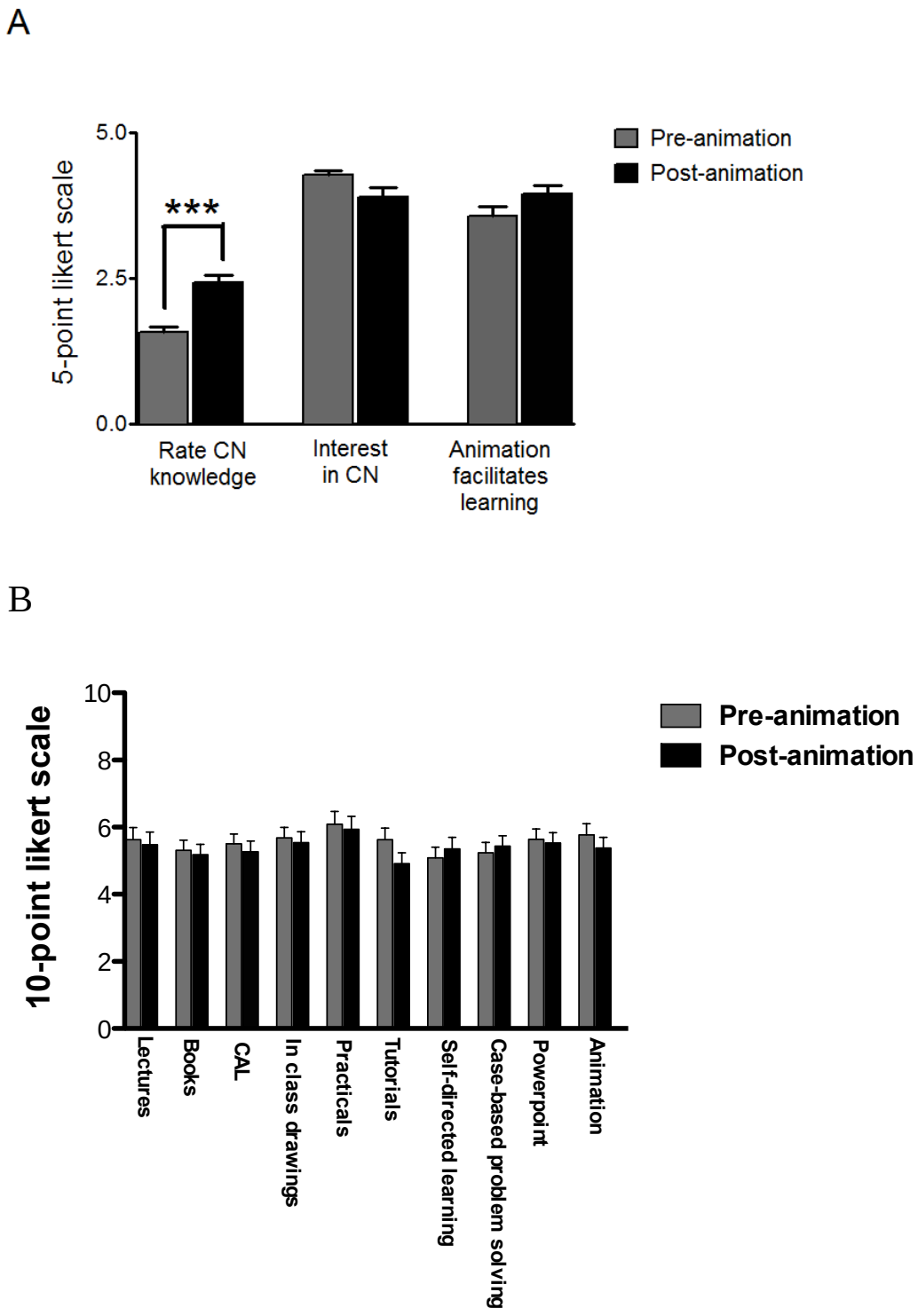

Fig. 3.3. Student's opinion and perception of animation as a learning tool. (A) Study participants were instructed to rate their knowledge and interest of the cranial nerves, in addition to their opinion that animation facilitates learning, using five-point Likert scales. Results expressed in the five-point Likert scores were: excellent knowledge = 5, good knowledge = 4, average knowledge =3, poor knowledge = 2 and no knowledge = 1 or strongly agree = 5, agree = 4, neither agree nor disagree = 3, disagree = 2, strongly disagree = 1. (B) Study participants were instructed to rate the importance of various teaching methods expressed in a ten-point Likert scores were: most important = 10 and least important = 1). All data are expressed as mean ± S.E.M. for 102 students. ∗∗∗$p < 0.001$.

Students were also asked to rate their interest in the role of cranial nerves in dentistry, expressed in a five-point Likert scale (5 = strongly agree and 1 = strongly disagree), collected pre- and post-animation access. Although 86.3% students agree that they are interested in the role of cranial nerves in dentistry, the study indicates that access to the animation tool did not enhance the students' interest in the role of cranial nerves in dentistry as expressed in a five-point Likert scale (mean Likert scale score 4.27 ± 0.08 pre-animation versus 4.09 ± 0.11 post-animation, mean ± S.E.M.; Fig. 3.3A). Finally, study participants rated the role of animation in facilitating learning expressed in a five-point Likert scale (5 = strongly agree and 1 = strongly disagree), collected pre- and post-animation. Although students agree that the animation facilitates learning, there was no significant change in score post-animation (mean Likert score 3.93 ± 0.11 pre-animation *versus* 4.08 ± 0.10 post-animation, mean ± S.E.M.; Fig. 3.3A). Importantly, the majority of respondents (89.2%) indicated that the newly developed animation was a useful tool in understanding the cranial nerves and would also be helpful during lectures (Table 3.2). Indeed, 95.1% of study participants indicated that they would like to see further animations as supplemental teaching tools in anatomy (Table 3.2).

Table 3.2: Student's perception of their learning experience with the animation.

Question (n=102)	Yes (%)	No (%)	No answer (%)
Do you think the animation was useful in understanding cranial nerves?	89.2	8.8	2.0
Do you think it would be helpful to use animations during lectures?	89.2	9.8	1.0
Would you like to see more animations on similar topics of anatomy?	95.1	2.9	2.0

Number of student responses (n) =102 students

Study participants were instructed to rate the importance of various teaching methods including lectures, books, computer-assisted learning (CAL), in class drawings, practicals, tutorials, self-directed learning, case-based problem solving, PowerPoint™ files and animation tools, pre- and post-animation, expressed in a ten-point Likert scale (10 = most important and 1 = least important) (Fig. 3.3B). Data presented in Fig. 3.3B indicates that practical classes (average pre- and post-animation Likert score of 6.08 ± 0.38 and 5.94 ± 0.38, respectively; mean ± S.E.M.) ranked as the most important teaching methods, with use of the new animation tool having no significant impact on student opinion of the importance of the indicated teaching methods (Fig. 3.3B). It is noteworthy that data presented in Fig. 3.3B also indicates that students ranked animation as an important teaching method (average pre- and post-animation Likert score 5.78 ± 0.33 and 5.38 ± 0.32, respectively; mean ± S.E.M.).

Student's Perception of Their Learning Experience with the Cranial Nerve Animation

Following access to the cranial nerve animation, students were instructed to rank their perception of their learning experience with the animation using in a five-point Likert scale (5 = strongly agree and 1 = strongly disagree) (Table 3.3). Overall students enjoyed watching the animation (five point Likert score: 4.26). Students considered that

animation improved their understanding of the cranial nerves, helped with the conceptual understanding of the cranial nerves and helped their understanding of the functions/origins of the cranial nerves (five point Likert scores: 4.12, 4.21 and 4.02, respectively; Table 3.3). Furthermore, the data from the post-animation questionnaires indicate that the animation was of good technical quality (4.11), the animation was easy to understand (4.04) and presented the anatomy (4.15) clearly. Importantly, data indicates that students strongly agree that animations should be made for difficult topics and that it would be helpful to use the animations on similar topics of anatomy (five point Likert scores: 4.49 and 4.40, respectively; Table 3.3).

Table 3.3: Student's perception of their learning experience with the animation.

Question	n	Mean	±SEM
I enjoyed watching the animation	102	4.26	0.104
Cranial nerves are a difficult topic to visualize	102	4.09	0.105
The names of cranial nerves are easy to remember	102	2.71	0.124
The course of the cranial nerves is difficult to visualize	102	3.97	0.088
The functions of the cranial nerves are difficult to understand	102	2.90	0.118
Cranial nerves are an easy topic to memorize	102	2.55	0.133
The animation improved my understanding of the cranial nerves	102	4.12	0.110
The animation was useful in understanding the cranial nerves	102	4.17	0.105
The animation helped me with the conceptual understanding of the cranial nerves	102	4.21	0.097
The animation helped me with the understanding of the functions/origins of the cranial nerves	102	4.02	0.103
The animation explained the concept clearly	102	3.82	0.112
The animation presented the anatomy very clearly	102	4.15	0.310
The animation presented the functions very clearly	102	3.84	0.133
The animation is not a useful learning resource	102	2.07	0.140
The animation was of good technical quality	102	4.11	0.127
The animation was easy to understand	102	4.04	0.103
The pace of the animation was too fast to follow	102	3.82	0.135
The duration of the animation was satisfactory	102	3.76	0.124
It will be helpful to use the animations during the lectures	102	4.20	0.099
It will be helpful to use the animations on similar topics of anatomy	102	4.40	0.077
I think the animations should be used in lectures	102	4.26	0.087
I think the animations should be made for difficult topics	102	4.49	0.081

Student response on a 5-point Likert scale (1 = strongly disagree; 2 = disagree; 3 = neither disagree nor agree; 4 = agree; 5 = strongly agree); mean Likert score, standard error mean (± SEM) are listed.
Number of student responses (*n*) = 102 students.

In support of this, the post-animation questionnaire contained open-ended questions to indicate if the student cohort considered animations as useful teaching tools. The following are some quotations:

- *"It helps visualize what your learning, making it easier to remember"*
- *"They stimulate our visual learning centers and provide helpful material to visualise, understand and appreciate different topics"*
- *"Yes, they keep your attention"*
- *"Yes, it is easier to learn from rather than sitting reading a book/lecture slide"*
- *"Yes, to help visualize topics and structures, while topics are explained"*
- *"Animations help students to visualize concepts better in 3D"*
- *"Yes easier to look at than studying books the whole time"*
- *"Yes as they are a good visual and accessible outside of classes"*
- *"Yes, I absolutely do think so. It would be very helpful to watch animations before the content is presented so that it could prepare us for what is to be introduced in class"*
- *"I remember things when I see them/watch things"*
- *"Yes, could visualize anatomy"*
- *"Yes. They consolidate the topic into a summary of the process, show the inter-relation between different parts of the topic"*
- *"Yes. Help to better visualize the concepts and makes learning less "one dimensional""*

The post-animation questionnaire contained an open-ended question to determine if the student cohort had suggestions for improvement. Hence students had the opportunity to indicate how the animation could be optimised to assist in their learning. The following are some quotations:

- *"The whole animation was a little too fast"*
- *"If dictation was slower I would have had a greater understanding"*
- *"Possibly slow down"*
- *"More videos/animations on other topics such as bones of the skull"*
- *"A more descriptive video, that is not so short"*
- *"Maybe break up cranial nerves into groups so it is easier to recall"*

Data collated overall indicates that students value the learning benefits of animation as a whole, assisting in maintaining attention and visualising the anatomical content. Overall, in terms of future development of the animation the student cohort indicated that the animation would benefit from reducing the speed of delivery of the material.

Discussion

Novel teaching strategies can act as supplemental tools to improve student learning and interest. Knowledge of the cranial nerves is central to the anatomical foundation required for clinical practice, and an understanding of the anatomy and function of the cranial nerves is central for many dental specialties. However, learning the physiology, anatomy, and clinical assessment of the cranial nerves is challenging for the student, given the complex structure, functions and pathways of the nerves. The aim of this study was to develop a new cranial nerve animation based around a simple life scenario, as a learning aid for dental students. Data herein demonstrate that students enjoyed watching the animation and indicated that animation acted as a supplemental tool to assist their study of cranial nerves. Access to the animation (both open access for two weeks and a single viewing) assisted with student understanding of the functions of the cranial nerves. Furthermore, the data indicate that the animation was easy to understand and presented the anatomy and functions clearly.

It is important to note that while the present study did not divide the study population into control and experimental groups, its design introduced a certain number of control points. Firstly, the study was implemented early in the first semester of the first year of the dental programmes, at a time prior to exposure of the students to the concept of cranial nerves. Secondly, of the 104 participants, 41.2% reported having completed a third level education. While we cannot ascertain whether this included neuroanatomy classes, we have more detailed information about 19 participants in this group, the graduate entry dental students. These were admitted to the dental programme on the pre-requisite that they had a background in biological sciences. One of the authors had access to their application form to determine that all had previously covered anatomy/physiology courses with some component of neuroanatomy. However, upon

re-analysis of the data with exclusion of responses from these students, the results pertaining to knowledge of the cranial nerves did not change significantly. Considering these parameters, it is likely that the increase in knowledge was derived from access to the animation.

The cognitive theory of Multimedia Learning is based on the concept that using both the visual and verbal pathways promotes enhanced learning outcomes (Mayer and Moreno, 1998; Mayer, 2002b) and memorization when compared to traditional teaching methods alone (Vernon and Peckham, 2002). The use of graphics has been shown to aid externalization of internal memory, in addition to supporting group memory and recollection of the same idea or concept (Tversky et al., 2002a). Both static (pictures, diagrams and images) and dynamic (videos and animations) teaching modalities are considerably important in simulating and creating an enhanced teaching environment (Wilson, 2015a). Hence, over the last number of years, multimodal teaching methods including videos, computer models and animation tools are being used to supplement standard methods of delivering anatomy in lectures (Trelease, 2002; Sugand et al., 2010; Drake and Pawlina, 2014; Wilson, 2015a). In particular, a body of literature indicates that computer animations enhance the students' understanding in anatomy and physiology, specifically in the topics of musculoskeletal anatomy (Hoyek *et al*., 2014), developmental anatomy (Carmichael and Pawlina, 2000), molecular physiology (Hwang *et al*., 2012) and the oculomotor system (Glittenberg and Binder, 2006). In support of this, Hoyek *et al.*, (2014) have determined that certain topics, such as functional anatomy, require spatial ability for better understanding of 3D animation (Hoyek *et al*., 2014). Furthermore, outside the classroom, 3D computer animations can effectively be employed to train patients to perform peritoneal dialysis (Bernardini and Davis, 2014), reduce patient anxiety related to surgery (Tou *et al*., 2013), improve the recall of

patients knowledge on periodontitis (Cleeren *et al*., 2014), in addition to complementing training in surgical training schemes (Fung *et al*., 2016).

It is clear that certain factors, such as, spatial localization ability and interaction with the animations, will collectively influence the benefits attained from watching a computer animation (Ruiz *et al*., 2009). An added advantage of animations is that they can be readily made available to the students as a supplementary teaching aid. Indeed, web-based animations have the added advantage of increased accessibility and can be watched repeatedly at the convenience of the students (Guttmann, 2000). Indeed, students consider repeated viewings, especially during studying the topic, a crucial contributing factor for their success in examinations (Reindl *et al*., 2015).

The results identify that students perceive cranial nerves as a difficult topic to visualise and memorize, and have difficulty identifying the names of the cranial nerves. Such a pattern of results was expected as previous evidence indicates that students have difficulty in understanding this topic (Sheth *et al*., 2009; Yeung *et al*., 2011; Dickson and Stephens, 2015). As a result, studies elsewhere have employed a range of strategies to engage students in learning the cranial nerves, including gaming avatars (Richardson-Hatcher *et al*., 2014), 3D virtual simulations (Yeung *et al*., 2011; Johnson *et al*., 2012; Nowinski *et al*., 2012), 3D interactive models (Kakizawa *et al*., 2007; Allen *et al*., 2015), drawings (Bolek, 2006) and miming (Dickson and Stephens, 2015). The present study highlights that dental students perceived that the cranial nerve animation was easy to understand and assisted with student learning of human anatomy, indicating that this animation is a good multimedia tool to supplement learning human anatomy. These findings support previous studies indicating that animations are supplementary teaching aids for both anatomical and physiological concepts (Carmichael and Pawlina, 2000; Hwang *et al*., 2012).

The present animation was developed along the principles of the cognitive theory of multimedia learning (Mayer, 2002b), and while careful pruning was performed during the development stages, post-study user feedback revealed that one item may have been overlooked. In their open feedback, a number of students reported that the animation progressed too rapidly. The pre-study feedback had failed to highlight the speed and despite the fact that students had control on the progression of the animation (pause, rewind, play), a number of them felt that it impeded their experience. The animation does not contain free rotation tools, however it is argued that an online animation can act as a tool to assist student understanding of core anatomy content. Firstly, the animation can be visualized on any computer or device with an internet browser, and does not require specialized 3D-rendering software or plug-ins. This significantly facilitates ease of access for viewing, and is reflected in the data indicating the device used to observe the animation (computer, laptop, tablet, iPad), in addition to the location of viewing (commuting, home, campus). Data gathered suggested that the majority of the students enjoyed watching the animation and felt it was a useful teaching and learning aid. The students also felt that the animation was easy to follow and understand. Benefits of the animation included its easy availability, provision for repeated usage and the plausibility of the video. Furthermore, this study incorporated a defined beginning and end into the animation storyboard, providing structure in the delivery of content to the student. Indeed, the animation developed in this study demonstrates all the cranial nerves in a simple, everyday functional scenario. The nerves are grouped according to function e.g. all the eye muscles and nerves are grouped together as they function together. It is noteworthy that 14.3% (of 42 students in the open access cohort) of students indicated that they observed multiple clips of the animation (up to 9 clips) during two-week open access to the animation, and future

studies will determine if the frequency of animation viewing correlates with improvements in knowledge in cranial nerve subtopics (i.e. swallowing, mastication).

This study has several limitations. The study was restricted to targeting specific sensory and motor functions of the cranial nerves in the animation. Indeed, the animation did not reference the autonomic nerve supply (apart from salivation) and hence a detailed review of each cranial nerve and its functions was beyond the scope of this animation. Second, while there are advantages of using animations for teaching such as accessibility outside of teaching hours, there are substantial costs associated with the development of this teaching pedagogy. Furthermore, the study design did not undertake a comparison of the animation with the traditional ways of teaching (e.g. lectures, practicals), and hence the findings indicate that animation tools can supplement, but not replace, traditional teaching modalities. The study did not limit student access (42 students in the open access cohort) to other teaching material for information on cranial nerves (textbooks, internet access) during a two-week period of open access to the animation. However, given that a single viewing of the animation (without access to textbooks and internet resources) in a practical laboratory setting improved student knowledge on several cranial nerve questions, the current study design did distinguish that improved performance was not due to access to textbooks and internet resources. It should also be noted that the study was conducted in the first weeks of academic year 1, when a majority of students would have had no other formal teaching on the cranial nerves. The study was carried out on a small number of participants, learning in year 1 curriculum in a single anatomy unit, at a single University, which limits the generalization of the findings.

Conclusion

The aim of this study was to develop a cartoon-type animation detailing the names, function and anatomy of the cranial nerves, with particular emphasis on an everyday functional scenario, as a learning aid for dental students. The study identified that students strongly rate animations for teaching complex topics in anatomy. Data herein also indicates that the cranial nerve animation acted as a supplemental tool to assist student understanding of the functions and origins of the cranial nerves. Given the complex structure, functions and pathways of the cranial nerves, the present study provides novel insight on the role of animation tools (that incorporate a simple life scenario) as effective supplemental teaching aids to support lectures and practicals in neuroanatomy.

CHAPTER 4

Assessment of Thiel-embalmed Cadavers as a Teaching Tool for Oral Anatomy and Local Anaesthesia.

Lone M[1], McKenna JP[2], Balta JY[1], O'Mahony SM[1],
Cryan JF[1], Downer EJ[3] and Toulouse A[1]

[1]Department of Anatomy and Neuroscience, University College Cork, Cork.
[2]Cork University Dental School and Hospital, University College Cork, Cork.
[3]School of Medicine, Discipline of Physiology, Trinity College Dublin, Dublin.

Published in *Journal of Dental Education*.

Abstract

Objective: We aimed to determine whether Thiel-embalmed cadavers would provide a useful anatomy teaching tool for topics that cannot be approached using formalin-fixed cadavers such as oral cavity examination and maxillary anesthesia.

Methods: The suitability of Thiel–embalmed bodies to perform oral examination was assessed by asking first year dentistry students to identify oral structures on a classmate and on a Thiel-embalmed body. The ease of location was compared in both settings and their quality was assessed on the cadavers. The suitability of Thiel-embalmed cadavers to teach maxillary anesthesia was assessed by performing mock injections at 5 adjacent sites daily for five consecutive days and inspection of the gingival surface by experienced anatomists and dentists.

Results: Most oral structures were more difficult to locate on cadavers. The texture and appearance of the features in the cadavers were found to be neither unrealistic nor realistic. The relative inexperience of the participants, the accumulation of fixative in the oral cavity and discoloration were mentioned as potential confounding factors. Visual analysis of images obtained following repeated injections revealed no deterioration of the tissue. Importantly, the puncture marks appeared to reduce over time, suggesting that the gingival tissue maintains some elasticity following Thiel fixation.

Conclusion: Our findings suggest that Thiel-embalmed cadavers are a useful tool to provide students more time to localize and study aspects of the oral cavity. Likewise,

the recoiling capacity of gingival tissue suggests that Thiel-embalmed cadavers may provide an ideal tool for teaching injection technique of local anesthetics.

KEYWORDS

oral anatomy, Thiel-embalming, local anesthesia, dental education.

Introduction

Dental anatomy courses are traditionally delivered through a combination of classroom lectures, dissection room tutorials using cadaveric material or plastic models, and in recent years, computer-aided learning (CAL) tools (Heylings, 2002; McLachlan *et al*., 2004; Older, 2004; Rizzolo and Stewart, 2006; McHanwell *et al*., 2007; Turney, 2007; Winkelmann, 2007; Bryner *et al*., 2008). Cadaver-based teaching has been a pillar of anatomical teaching since antiquity (Aziz *et al*., 2002; Older, 2004; Rizzolo and Stewart, 2006; Turney, 2007). Following Vesalius' era, anatomical teaching evolved from demonstration-led teaching to experience-based learning (Anderhuber, 1996; Dyer and Thorndike, 2000). Evidence indicates that by proceeding to their own anatomical dissection, students experience the relationship of organs and their dimensional organization (Older, 2004; Turney, 2007; Lin *et al*., 2009; McLaughlin *et al*., 2015). While limited information could be gathered initially due to the rapid decay of organs, the development of fixatives has allowed the preservation and retention of cadavers for extended periods (Brenner, 2014; Balta *et al*., 2015). Indeed, this has facilitated the expansion of medical courses, offering students the opportunity to access, in detail, structural information that would have otherwise been acquired in textbooks and lectures (Lin *et al*., 2009; Bohl *et al*., 2011). However in recent years, curricular pressures (namely time reduction and an increase in student numbers) has forced many institutions to re-orient the delivery of anatomy courses towards a prosection- and / or model-based delivery (Heylings, 2002; Older, 2004; Rizzolo and Stewart, 2006; Drake *et al*., 2009). The introduction of CAL tools has enhanced the student learning experience; however, difficulties with the use of CAL tools in anatomical sciences still exist, particularly with regards to the dimensionality of the human body.

In addition, most fixation methods are associated with difficulties that include loss of coloration, hardening of tissue and loss of joint flexibility (Brenner, 2014; Balta *et al*., 2015). Because of such issues, it has been difficult to provide suitable cadaveric specimens to teach certain topics, such as the anatomy of the oral cavity. While sections of formalin-fixed cadavers have allowed students to visualize some structures, their dimensional relationship, their visual aspect and the difficulties in accessing the oral cavity are not representative of a clinical situation.

In the past 30 years, a number of new fixatives have been developed that preserve some of the features of fresh tissue, such as flexibility, resilience and coloration, allowing the development of teaching aids that could not be implemented using formalin-fixed cadavers (Balta *et al*., 2015; Hayashi *et al*., 2016). The haptic properties and musculoskeletal system in Thiel solution-embalmed cadavers resembles the anatomy of a fresh cadaver closely (Eisma *et al*., 2013; Hammer *et al*., 2015). Indeed, data indicates that oral tissues of the Thiel-embalmed cadaver such as the gingiva, alveolar bone, vessels and nerves, are well preserved and thus could be used for dental teaching and research (Holzle *et al*., 2012). Furthermore, Thiel-embalmed cadavers have been successfully used to demonstrate a number of oral surgery techniques such as ultrasound guided fine-needle aspiration of the tongue (Meacham *et al*., 2012), mandibular reconstruction using iliac crest grafts (Grohmann *et al*., 2013), trans-crestal maxillary sinus augmentation (Kuhl *et al*., 2016), experiments on fractured human mandibles (Steiner *et al*., 2012), herniation of the mylohyoid muscle (Windisch *et al*., 2004) and implants (Peuker *et al*., 2001; Holzle *et al*., 2012). Indeed, undergraduate dental students in a British dental university are currently taught inferior alveolar nerve block and tooth extraction on Thiel-embalmed cadavers, with students reporting improved confidence after performing their first extractions on Thiel cadavers

(Hanson, 2011). Overall, performing these procedures on a cadaver may enhance the clinician's confidence prior to operating on their first patients and furthermore reduce the incidence of complications (Holzle *et al*., 2012).

At University College Cork, first year dental anatomy has traditionally been delivered using formalin-fixed prosections with the ensuing loss of quality described above. Oral cavity examination in patients usually takes place in the student's 2nd year, creating a time lag between the acquisition of anatomical knowledge and clinical application, with potential loss of information (Morris and Chirculescu, 2007). Furthermore, some procedures such as the application of local anesthetics, has traditionally been practiced on classmates, leading to stress and potential complications, such as direct nerve trauma and periosteal injury, resulting in post-procedural pain. The present study aimed to assess the suitability of Thiel-embalmed cadavers as useful teaching tools for the examination of features of the oral cavity and demonstration of the integrity of the gingival tissue following repeated injection to perform superior alveolar nerve blocks.

Materials and Methods

Assessment of Anatomical Features of the Oral Cavity

For this part of the study, participants were recruited from the first year dentistry and dental hygiene classes at University College Cork (Appendix 9). The study was approved by the institutional Social Research Ethics Committee (Appendix 8). Two Thiel-embalmed whole cadavers and two Thiel-embalmed heads were used for assessment of the oral cavity. The whole body cadavers were fixed and maintained following the modified Thiel embalming protocol (Eisma *et al*., 2013; Hammer *et al*., 2015). For the head sections, the parietal bone was cut and the brain removed. Fixation was achieved by immersion in Thiel embalming fluid for a period of 5 months with regular monitoring. The Thiel embalming protocol was developed as a low-formaldehyde alternative to traditional fixatives.

Following the viewing of a video on clinical examination of the oral cavity, the participants were asked to locate and examine 14 anatomical landmarks of the oral cavity (Table 4.1) on a partner and rate their ease of location using a Likert scale (1 = very difficult to locate; 5 = very easy to locate) (Appendix 7). For this part of the study each study participant under examination sat upright on straight chairs and followed instructions from their partners to facilitate the examination. Next, the participants were asked to repeat the same examination on the oral cavity of the Thiel-embalmed cadavers and provide a comparison to their experience on their partner. The participants were randomly assigned to examine the Thiel-embalmed cadavers or fixed heads and results were compiled indiscriminately. All cadavers and heads were placed in the anatomical position during examination. Specifically, the participants were asked to rate the ease of location of the anatomical features using the same Likert scale. Study participants also rated the texture and the appearance of the anatomical features compared to their

experience on their partner using a 5-point Likert scale (1= very unrealistic; 5 = life-like) (Appendix 7).

Table 4.1: Anatomical landmarks examined.

Lips	Hard palate
Labial frenulum	Soft palate
Buccal frenulum	Uvula
Labial mucosa	Pterygomandibular raphe
Buccal mucosa	Tongue (anterior and posterior part)
Free gingiva	Lingual frenulum
Attached gingiva	Sub-lingual fold

Evaluation of Thiel-embalmed Cadavers as a Tool to Teach Maxillary Anesthesia

Two Thiel-embalmed cadavers were used for this part of the study. Disposable dental infiltration anesthetic needles (32 gauge) were used for testing. The alveolar mucosa of the maxillary canine was perforated (without injection of fluid) 5 times daily within a 1 cm^2 area over 5 consecutive days. Images of the mock injection area were taken using a Canon digital SLR camera immediately after injection, and at 3h, 6h and 24h post-injection. The images were assessed by a blind assessor for the presence of mock injection marks at each time point.

Statistical Analysis

Data are presented as the mean Likert score ± S.E.M. and were assessed using a Wilcoxon's ranked test and deemed significant when $p<0.05$.

Results

Assessment of Anatomical Features of the Oral Cavity

Following the projection of a video on clinical examination of the oral cavity in class, students from first year direct entry dentistry (BDS1), first year graduate entry dentistry (BDSG1) and first year dental hygiene (DDH1) at University College Cork, Ireland, were invited to participate in this study. Data was obtained from 57 respondents, but only 54 fully completed forms were analyzed (36 BDS1, 10 BDSG1 and 8 DDH1).

In order to compare the ease of location of anatomical features, the scores obtained for study partners and Thiel-embalmed cadavers were compared using the Wilcoxon paired rank test. Results show that most features of the oral cavity were more difficult to locate on the cadavers than on classmates *in vivo,* with the exception of the lips, the buccal frenulum, the labial mucosa, the hard palate and the tongue (Figure 4.1A). It is interesting to note that posterior features, such as the uvula and the pterygomandibular raphe, yielded the greatest location difficulty in the Thiel-embalmed cadavers (mean Likert score of 2.26 and 2.86, respectively). The accumulation of fixative in the oral cavity of cadavers, in addition to some level of discoloration were identified as potential complicating factors.

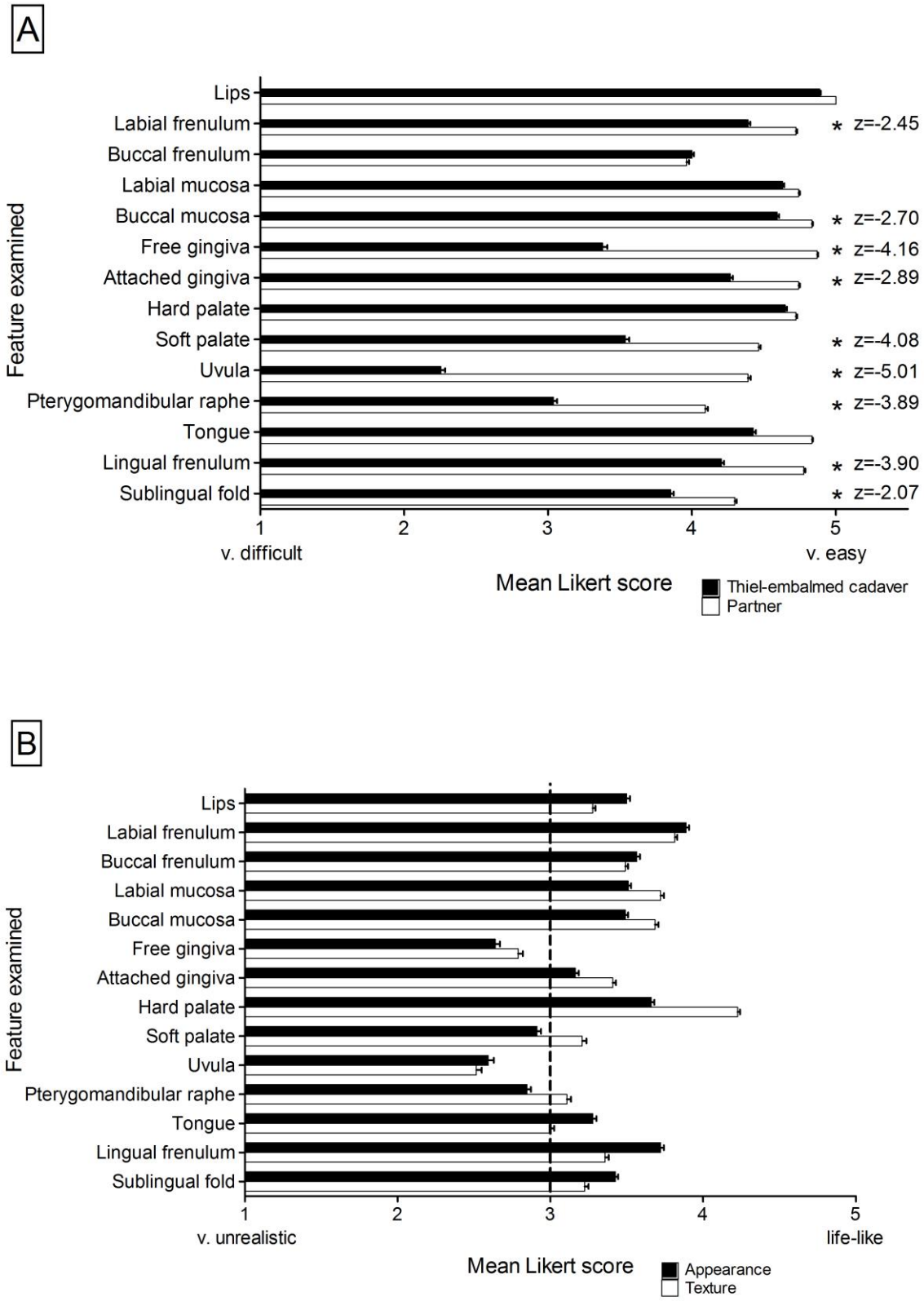

Figure 4.1: Assessment of 14 anatomical structures of the oral cavity. A) The participants were asked to rate the ease of location of the listed features on a partner (white bars) and on a Thiel-embalmed cadaver (black bars) using a Likert scale where 1= very difficult to 5= very easy). The data represent the mean Likert scale scores ± S.E.M. collected from 54 participants. The data was compared using a Wilcoxon's paired-rank test with $*p < 0.05$. B) The participants were asked to rate how life-like the appearance (black bars) and texture (white bars) each anatomical feature was in a Thiel-embalmed cadaver. The dotted line indicates the median of the scale, neither realistic nor unrealistic.

After rating the ease of location of the anatomical features, the study participants were asked to compare the "life-likeness" of these features on Thiel-embalmed cadavers when compared to their experience on a partner (Figure 4.1B). The average Likert scores collected for the appearance of the 14 features revealed that all features were rated as neither realistic nor unrealistic by the participants. The features that were ranked as the most realistic visually were the labial (3.89) and lingual (3.72) frenula, followed by the hard palate (3.67). With regards to texture, the participants indicated that the hard palate felt realistic (4.23), followed by the labial frenulum (3.81), and the labial and buccal mucosae (3.72 and 3.69, respectively).

Evaluation of Thiel-embalmed Cadavers as a Tool to Teach Maxillary Anesthesia

Five simulated maxillary injections were performed daily in a 1 cm^2 area for 5 consecutive days (25 injections total). Images were taken immediately following the mock injections and then at 3h, 6h and 24h. Visual inspection by a trained anatomist revealed very little deterioration of the tissue after repeated pricking, and although most of the injection marks are still visible after 5 days, the majority of puncture marks demonstrate a reduction in size. This suggests that the gingival tissue has preserved some elasticity after fixation (Figure 4.2).

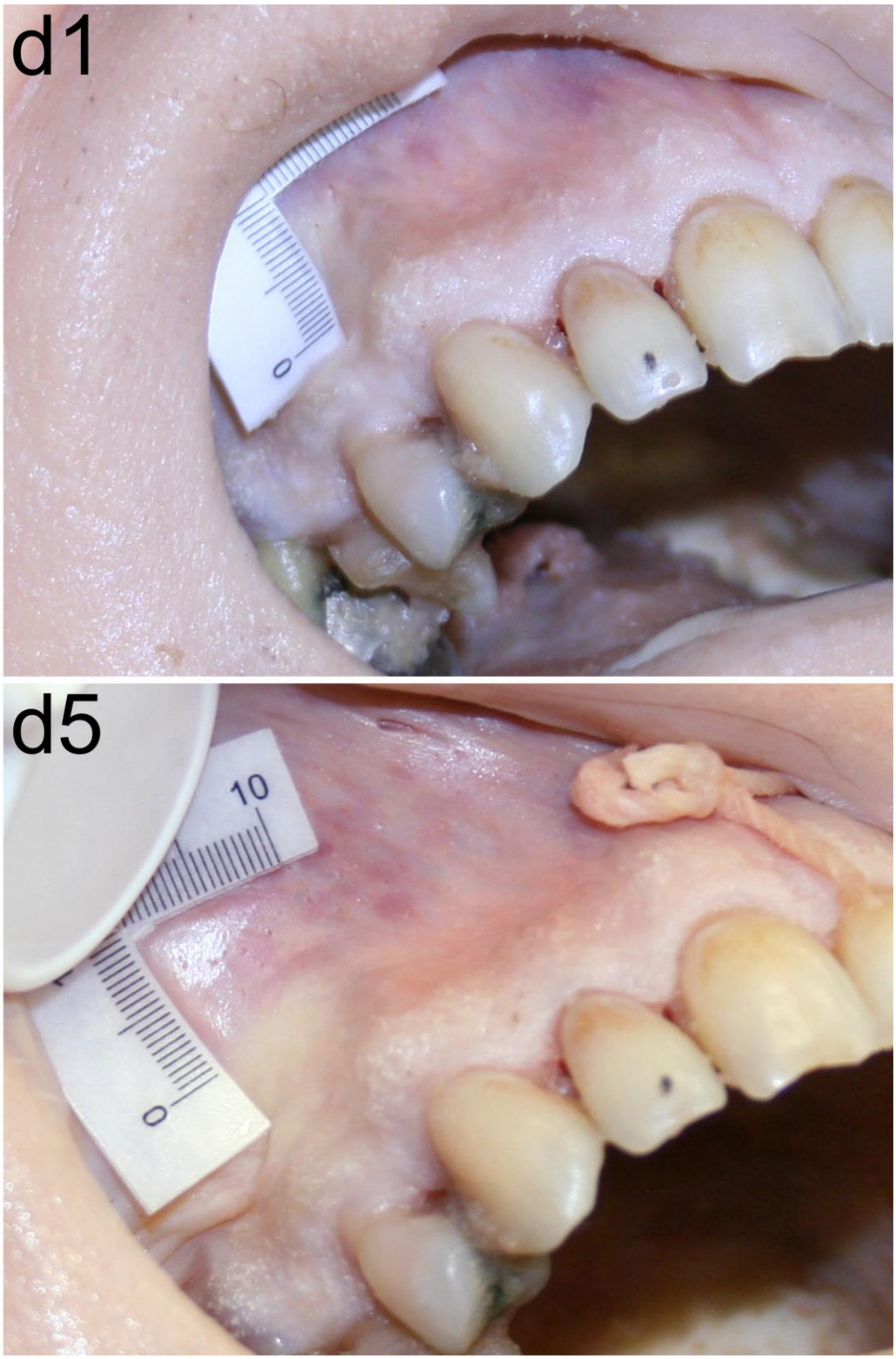

Figure 4.2: Assessment of Thiel-embalmed mucosal tissue after repeated injection. The superior alveolar mucosa of a Thiel-embalmed cadaver was pricked 5 times daily using a 25 gauge needle in a 1 cm^2 area and images were taken at 0h, 3h, 6h and 24h. The images represent the gingival tissue at d1 after the initial five punctures and at the end of the 5 day experiment.

Discussion

Due to the very limited flexibility of formalin-embalmed cadavers, dental anatomy teaching has been limited by the availability of appropriate sections demonstrating features of the oral cavity. When sections are available, they do not preserve texture and appearance of living tissue, leading to a learning bias. The Thiel method for the soft preservation of human tissue was developed in the early 1990's and has been used in a variety of settings including medical and surgical teaching. In particular, Hölzle *et al.* reported that the colour, structure and haptic properties of the gingival and mucosal tissue are comparable to fresh tissue (Holzle *et al*., 2012). Thiel-embalmed cadavers have been used to teach a number of oral surgical technique (Holzle *et al*., 2012), but their usefulness as a teaching tool for dental anatomy and procedures has seldom been assessed.

The results indicate that Thiel-embalmed cadavers are a reliable study tool for features of the oral cavity. Developing competency in assessing oral health and delivery of anesthetics is a process that requires time and repetition. In the dentistry degree programme at University College Cork, content regarding the assessment of oral health and delivery of anesthetic is applied at clinical level (year three onwards), resulting in a disconnect between anatomy and clinical teaching. In addition, a number of limitations will restrict the acquisition of clinical competency such as the availability / willingness of study partners as well as a clear knowledge of anatomical landmarks.

Importantly, our results demonstrate that most of the features under study, with the exception of the pterygomandibular raphe and the uvula, could be readily located in the cadavers. While the positioning of partners and cadavers differed during examination, most features were more easily identified on the study partner, suggesting that it may have had an influence. However, considering that the position of the

cadavers is more conducive to full examination of the oral cavity, it suggests that other factors may have influenced the difference in ease of location. The appearance and texture of these features was rated as neither realistic nor unrealistic, with the exception of the free gingiva and uvula, which were rated the lowest. Feedback from the participants highlighted that the presence of fixative in the posterior part of the oral cavity hampered their effort at assessing the pterygomandibular raphe, the uvula and the soft palate. Feedback also suggested the provision of a suction tool to remove excess fluid prior to examination. In addition, some of the participants indicated that their cadaver had no teeth, negating the identification of the free gingiva. The relative inexperience of the participants must also be taken into consideration. While all the participants had previously attended lectures and dissection room demonstrations, this was their first attempt at identifying these structures on partners and cadavers. In particular, the clinical importance of the pterygomandibular raphe, in addition to the difficulties associated with identifying the raphe, highlight the need for an appropriate anatomical model.

The findings indicate that repeated perforation of the gingival tissue did not induce deterioration of the tissue's integrity. Importantly, the needle marks appear to reduce in size after 3 hours, suggesting that the tissue preserved sufficient elasticity to partly mask the presence of puncture marks. As the goal of the study was to measure surface deterioration following repeated puncture of the gingival tissue, it is important to note that fluid injection was not part of this study, given that fluids are not readily absorbed in cadavers. While further studies will determine if Thiel-embalmed cadavers can be used to teach local anesthetic injection, the results show that in the absence of bleeding and inflammation, the gingiva of soft-preserved cadavers can be repeatedly perforated with an injection needle with little deterioration of the tissue. The findings

also show that Thiel-embalmed cadavers may act as a useful tool to teach needle placement in the application of local anesthetics. In contrast, the first application of local anesthetics is regularly performed on classmates, leading to stress and potential complications.

Two qualified dentists and one anatomist present during the survey identified that the temporomandibular joint (TMJ) in three of the four cadavers had excessive range of movement on opening and lateral excursion, suggesting a relaxation or degradation of the structures of the joint (Hammer *et al*., 2015). Therefore, while the model offers easy access to the oral cavity, it must be noted that the range of motion is greater than *in vivo*.

It is clear from the results presented herein that Thiel-embalmed cadavers offer key advantages. The preservation of tissue flexibility and resilience, as well as natural coloration, offers a good model for dental education. In addition, the Thiel embalming solution contains reduced amounts of formaldehyde, reducing the overall toxicity of the process. However, this is counterbalanced by the need for prolonged immersion in the embalming solution for completion of the fixation process. In addition, the costs associated with this process make it a relatively expensive model that may not be easily rolled out.

Conclusion

In conclusion, our results show that Thiel-embalmed cadavers provide a useful tool for dental anatomy teaching. Whether it is for examination of the oral cavity or simulation of a local anaesthetic injection technique, this model provides a reliable teaching aid to build learner's confidence and develop their skills and anatomical knowledge prior to clinical scenarios.

CHAPTER 5

A Survey of Tooth Morphology Teaching Methods Employed in the United Kingdom and Ireland

Lone M[1], McKenna JP[2], Cryan JF[1], Downer EJ[3] and Toulouse A[1]

[1]Department of Anatomy and Neuroscience, University College Cork, Cork.
[2]Cork University Dental School and Hospital, University College Cork, Cork.
[3]School of Medicine, Discipline of Physiology, Trinity College Dublin, Dublin.

Accepted in *European Journal of Dental Education.*

Abstract

Tooth morphology is a central component of the dental curriculum and is applicable to all dental specialities. Traditional teaching methods are being supplemented with innovative strategies to tailor teaching and accommodate the learning styles of the current and future generation of students. An online survey was compiled and distributed to the staff involved in teaching tooth morphology in the UK and Ireland to assess the importance of tooth morphology in the dentistry curriculum and the methodologies employed in teaching. The results of the survey show that tooth morphology constitutes a small module in the dental curriculum. It is taught in the first two years of the dental curriculum but is applicable in the clinical years and throughout the dental career. Traditional teaching methods, lecture and practical, are being augmented with innovative teaching including e-learning via Virtual Learning Environment (VLE), tooth atlas and IBooks leading to blended learning. The majority of the schools teach both normal anatomy and morphologic variations of dental anatomy and utilize plastic teeth for practical and examination purposes. Learning the 3D aspects of tooth morphology was deemed important by most of the respondents who also agreed that tooth morphology is a difficult topic for the students. Despite being core to the dental curriculum, overall minimal time is dedicated to the delivery of tooth morphology, creating a reliance on the student to learn the material. New forms of delivery including computer-assisted learning tools should help sustain learning and previously acquired knowledge.

Introduction

The study of tooth morphology is a basic and major component of the curriculum taught to dental and dental hygiene students (Kato and Ohno, 2009). This field comprises teaching the anatomical and morphological features of the deciduous and permanent teeth, followed by examination which requires accurate identification of the teeth (Obrez *et al*., 2011). Traditional methods of teaching tooth morphology include lectures (Bogacki *et al*., 2004), practical elements involving wax carving (Wallen *et al*., 1997; de Azevedo Rde *et al*., 2015), studying with extracted teeth (Mitov *et al*., 2010), plastic teeth (Obrez *et al*., 2011) and drawings various images / views of the teeth (Abu Eid *et al*., 2013). However, some limitations were noted with these teaching methods, particularly human extracted teeth. The Human Tissue Act in the United Kingdom and the Anatomy Act in Ireland as well as ethical and safety implications are making it increasingly difficult to obtain and retain teeth. Another important prerequisite with utilizing the human tooth for teaching is its requirement to be caries free. These factors have led to a shift towards the use of plastic teeth models. While plastic teeth are hygienic, lack ethical issues and are caries free, they also lack the variations observed with extracted human teeth (Obrez *et al*., 2011). Another important factor noted, was the lack of inclusion of the different learning styles in traditional teaching methods, and the consequent decline in student interest (Bogacki *et al*., 2004).

The more recent cohorts of students are regularly referred to as “digital natives” or the “YouTube generation” (Farnan *et al*., 2008; Azer, 2012), and are usually comfortable with using and learning with technology (Maggio *et al*., 2012), thus suggesting that the incorporation of e-learning elements into the dental curriculum may be appropriate (Mitov *et al*., 2010). Online tests / quizzes have been shown to motivate students and can be invaluable in preparing the student for examination (Bogacki *et al*.,

2004). Innovative teaching strategies are being developed and used for teaching tooth morphology such as 3D simulation (Curnier, 2010; Perry *et al*., 2015), dentistry applications (Khatoon *et al*., 2013; Khatoon *et al*., 2014) and Moodle (El Tantawi *et al*., 2015). Furthermore, recent development in computerized tomography (CT) and micro-CT scanning has allowed the visualization of the root morphology (Verma and Love, 2011), development of a tooth atlas (Nagasawa *et al*., 2010), three-dimensional visualization of the pulp chamber (Nagasawa *et al*., 2010; Salajan *et al*., 2015), determination of the position of the inferior alveolar nerve (Massey *et al*., 2013) and even construction of virtual teeth (de Boer *et al*., 2015). An advantage of using atlases and 3D software is simultaneous viewing by larger numbers and its applicability in multiple areas (Nagasawa *et al*., 2010). Utilizing these strategies to support the traditional teaching method ensures the inclusion of various learning styles (Bogacki *et al*., 2004).

The aim of this manuscript was to assess the education tools and methods employed in teaching tooth morphology in an increasingly digital environment. We surveyed 17 teaching institutions in the United Kingdom and Ireland offering professional dental qualification courses.

Materials and Methods

An online questionnaire was designed to collect data regarding the delivery of tooth morphology teaching in dental schools in the Republic of Ireland and the United Kingdom (Appendix 10). LimeSurvey was used to design the questionnaire. An introductory page briefly described the aims of the study and described the conditions of consent and withdrawal as well as the opportunity to review and discuss the participant's involvement with the study lead.

The questionnaire was comprised of 19 questions grouped in 2 sections. The first section consisted of 6 questions and included questions regarding the respondents' general background and their teaching experiences. The second section addressed 13 questions regarding the respondents' teaching commitments, teaching modalities used and their opinions on different anatomy pedagogies. The questionnaire was validated by the participation of the senior medical demonstrators in the Department of Anatomy and Neuroscience at University College Cork. A focus group session was conducted to discuss feedback on the questionnaire. Ethical approval for the study was obtained from our institution's Social Research Ethics Committee (Appendix 11).

A list of academic staff teaching tooth morphology in universities and dental schools located in the Republic of Ireland and the United Kingdom was created by searching through departmental websites and by personal correspondence. Emails were used to send invitation to respondents. The invitation email included a short description of the research being conducted and a link to the online questionnaire. Invitations were sent to the academic staff delivering tooth morphology teaching within the various dental schools. A total of twenty invitations were sent. Data was compiled using the LimeSurvey statistical package.

Results

A total of 18 teaching institutions, including our own, were identified in the United Kingdom and Ireland. Individual staff involved in the delivery of tooth morphology teaching were invited to participate in the survey. One institution declined to participate. Some institutions had more than one person teaching tooth morphology and 21 invitations were sent to the 17 teaching institutions that agreed to participate in the study. Sixteen fully completed questionnaires were returned yielding an individual response rate of 76%, representing 14 out of the 17 institutions (82.3% response rate). There was usually a single response per institution with the exception of one institution where 3 tutors responded.

Participant's Background

When questioned about their qualifications, the majority of respondents reported having a minimum of a dental degree (*n*=11), with additional qualifications such as a Masters (*n*=6) and / or a Ph.D. (*n*=8). Three respondents reported other qualifications such as higher diplomas (Figure 5.1A). Importantly, two of the respondents did not report holding a dental degree but reported being titular of a Ph.D.

Of the participating educators, 2 (12.5%) stated having a leading role within their departments while 10 (62.5%) respondents had a senior teaching position including a senior clinical teacher and a jointly appointed consultant oral surgeon and lecturer. Furthermore, 4 (25%) reported having a teaching position (Figure 5.1B).

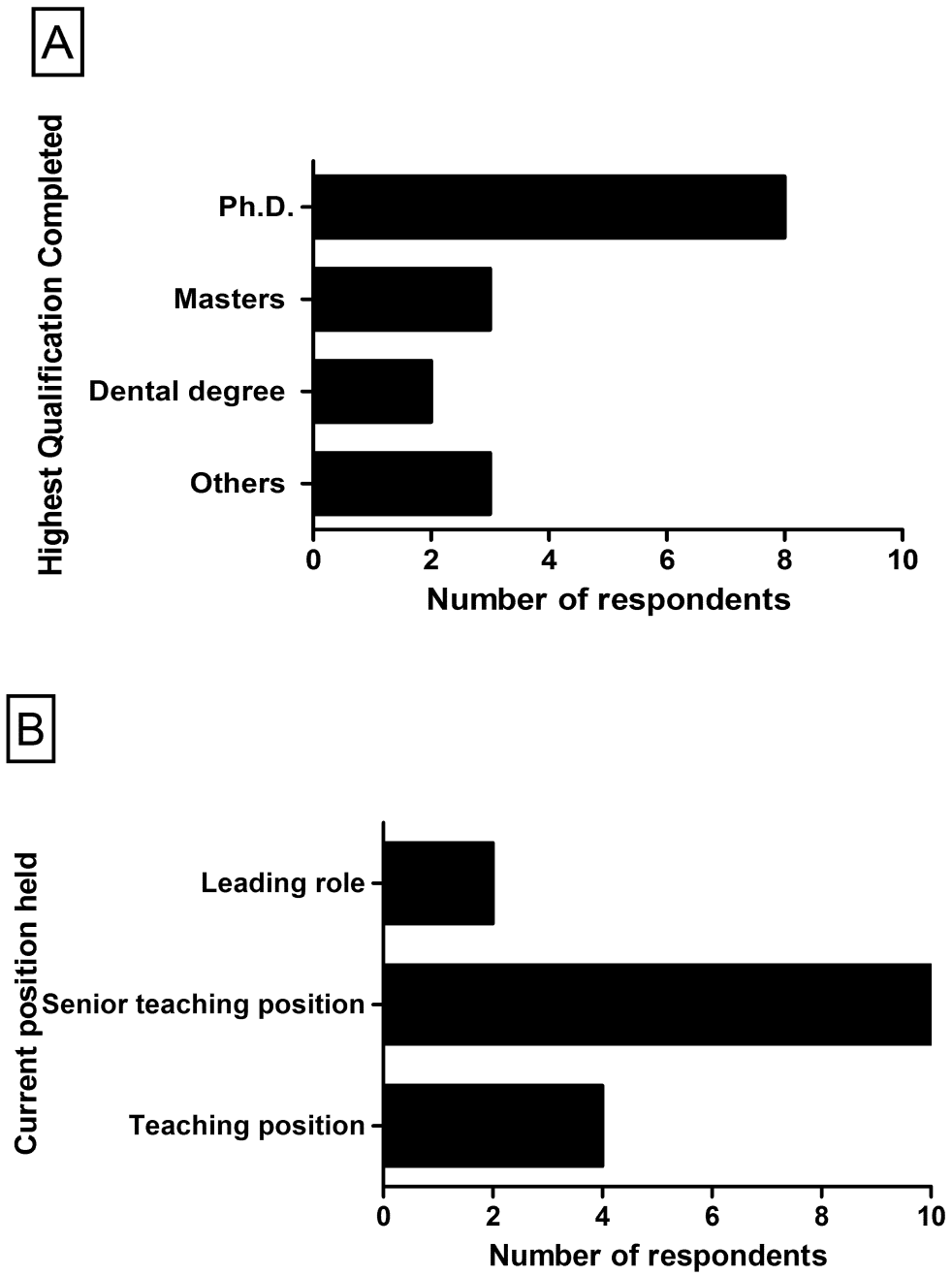

Figure 5.1: Participants profile A) Highest qualification achieved by the respondents. B) Current position held by the participants within their host institution. The values are indicated as number of respondents in each category (*n*=16).

When asked about time committed to teaching duties, 10 respondents (62.5%) reported teaching full time whereas 6 respondents (37.5%) reported part-time teaching. When asked to describe the groups of students that they teach, the majority of respondents (*n*=14, 87.5%) reported teaching dental students while other students taught included dental hygiene students (*n*=9, 56.25%), graduate entry dental students (*n*=7, 43.75%) and dental technician or dental nursing students (*n*=1, 6.25% each). Finally, 3 respondents reported teaching other groups (18.75%, Figure 5.2). When asked specifically about tooth morphology teaching, 14 respondents (87.5%) revealed teaching only undergraduate students while 2 taught both undergraduate and post-graduate students (Fig. 5.2).

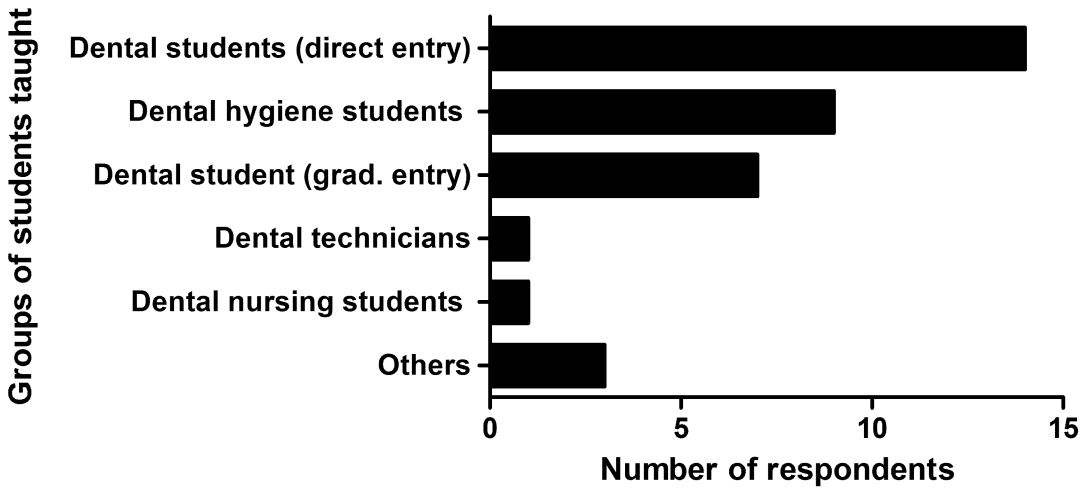

Figure 5.2: Description of the combined teaching profile of the various institutions. The values are indicated as number of respondents in each category (*n*=16).

Tooth Morphology Teaching

When questioned about tooth morphology teaching modalities, response analysis showed that 12 respondents (75%) teach lecture and practical sessions, one of whom also reported delivering tutorials. Two of the participants (12.5%) reported teaching practicals only, whereas one respondent (6.25%) reported other modalities that included online teaching on a web e-learning programme for multiple usages by students. One participant reported being module coordinator for a tooth morphology module but no teaching modalities.

Participants were questioned about the number of lecture hours they deliver on tooth morphology annually. Thirteen respondents (81.25%) lectured 0-10 hours / year whereas 2 participants (12.5%) average 11-20 hours of lectures per annum. Finally, one respondent reported teaching 21-30 hours every year on tooth morphology. When participants were questioned about the number of hours dedicated to tooth morphology practical sessions, the majority (12, 75%) of the respondents reported up to 10 hours of practicals per year, while 3 participants (18.75%) reported that practicals ran for 11-20 hours / year. Only one participant (6.25%) reported having allocated 21-30 hours / year for tooth morphology practicals (Figure 5.3).

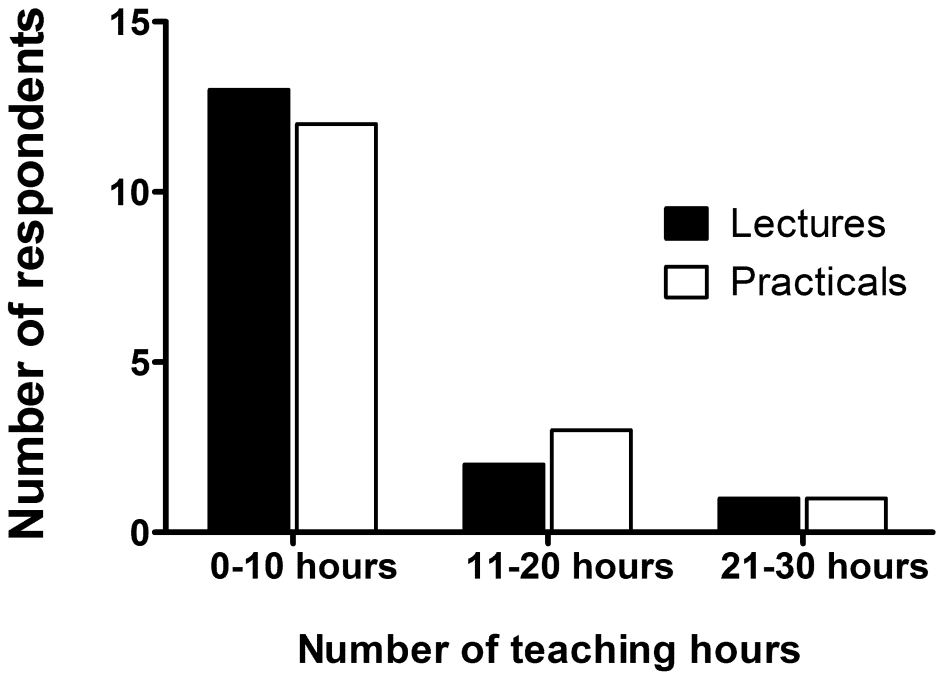

Figure 5.3: Time dedicated to tooth morphology education. The number of hours dedicated to tooth morphology lectures (black bars) and practicals (white bars) is indicated as the number of respondents in each category (*n*=16).

The next questions investigated the use of supporting material in lectures, practicals and examination. Unsurprisingly, all 16 respondents reported using PowerPoint to support their lectures with 15 participants (93.75%) making their notes available to students through their institutional virtual learning environment. One participant reported also making video recordings of the lectures available through the VLE in addition to the notes. Ten respondents (62.5%) reported using models in lectures while 6 respondents (37.5%) use videos and 5 (31.25%) more use animations. In ‘others’, 4 participants (25%) included online 3D models, blended learning materials and student handheld response keypads as additional technologies used in lecture settings (Figure 5.4A).

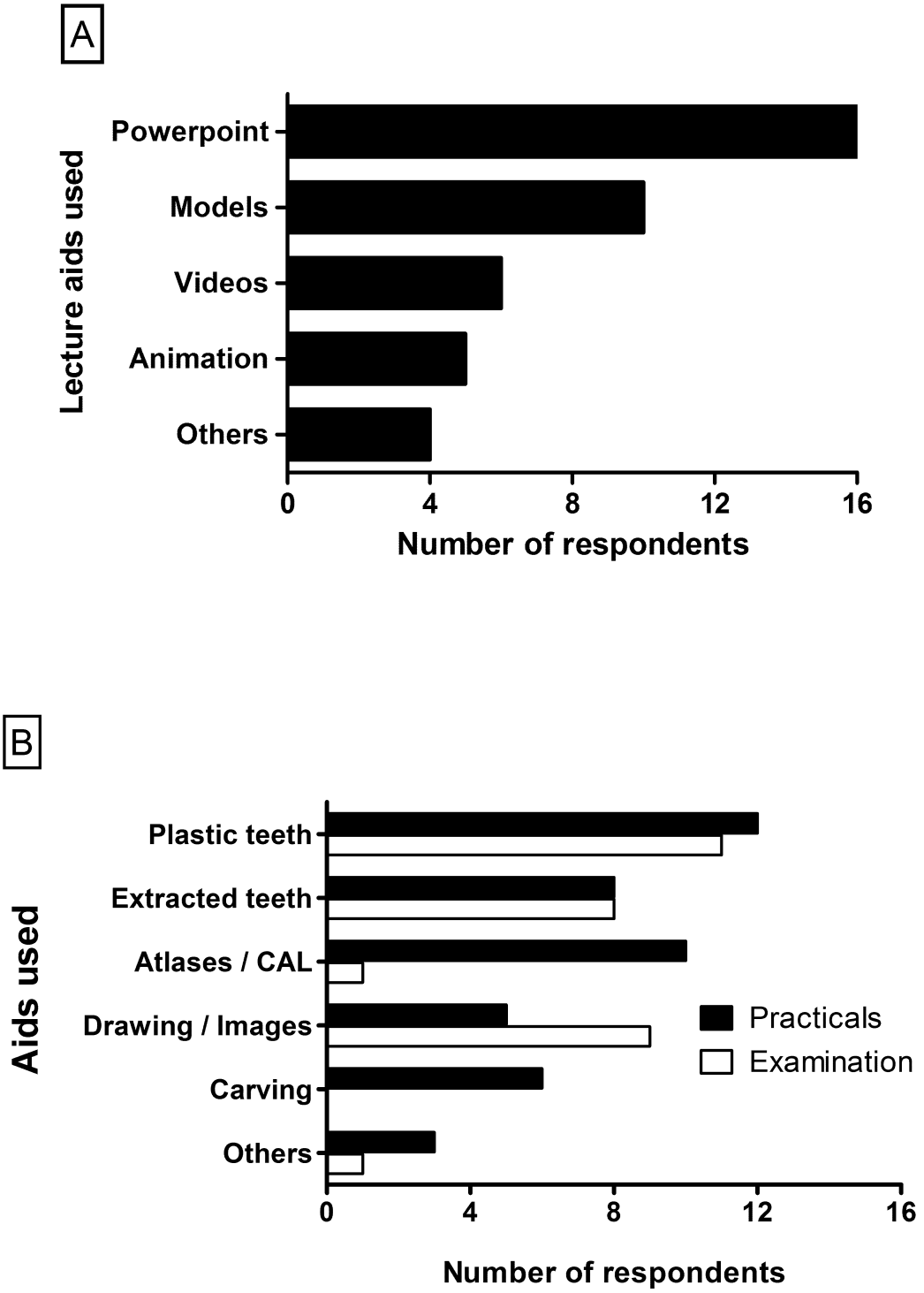

Figure 5.4: Teaching aids used in tooth morphology education. A) Teaching tools used in lecture delivery B) Supplemental aids used in practicals (black bars) and examination (white bars). The values are indicated as number of respondents in each category (*n*=16).

The participants were also asked if their institution offered e-learning to their students. Ten of the fourteen institutions (71.4%) reported offering some form of e-learning but comments revealed that the definition of e-learning may be quite variable. One respondent elaborated to clarify that although e-learning was not offered in their department, students were recommended several e-learning websites. The e-learning tools described (see below) ranged from institutional VLE to fully developed web-based or computer-based tools.

- *All PowerPoint's are available on Blackboard*
- *Material on VLE and supporting videos*
- *Lecture power points, recordings of lectures, videos, self-assessment questions*
- *Blackboard*
- *In house developed iBook delivered by iPads*
- *Blackboard VLE, You Tube video, SketchFab 3D models and Interactive quizzes via Kahoot*
- *We have an interactive tooth recognition web based programme*
- *10 step online guide to learning tooth anatomy*
- *e biolabs*
- *On line MCQs with feedback*

When questioned about the teaching aids they used in their tooth morphology practical delivery, only 8 participants (50%) reported using extracted human teeth whereas 12 respondents (75%) reported using plastic teeth. Furthermore, 10 respondents (62.5%) used tooth atlases and computer-aided learning (CAL). Interestingly, 6 respondents (37.5%) employed wax carving of teeth and 5 more

(31.25%) used tooth drawing exercises to develop student knowledge. Three respondents (18.75%) commented on 'other' teaching tools to mention that they request that students perform examination of the oral cavity on classmates, complete quizzes and workbook exercises (Figure 5.4B).

Respondents were asked to indicate the teaching tools they used for the purpose of student assessment in their tooth morphology module. Data presented in Fig 4.4B indicates that extracted human teeth were used by 8 respondents (50%) whereas 11 respondents (68.75%) used plastic teeth. Images were used by 9 respondents (56.25%) and tooth atlases / computer images were used by only 1 respondent (6.25%). Additionally, 1 respondent (6.25%) reported using plaster teeth for examination purpose (Figure 5.4B).

When further questioned about their curricular content, 12 respondents (75%) reported teaching normal tooth morphology, variations and anomalies, whereas 3 taught normal tooth morphology (18.75%) only and 1 (6.25%) respondent delivered lectures on variations and anomalies only. Respondents were then asked if in their experience, it was important for the students to learn the 3D aspects of tooth morphology. All agreed or strongly agreed. Study participants were also asked if they thought tooth morphology was a difficult topic based on their experience. Twelve respondents (75%) agreed whereas 4 (25%) disagreed with tooth morphology being a difficult topic. Three respondents in agreement and two in disagreement offered additional comments. Comments from the respondents are shown in the table below.

In agreement:

- *Our ethos is an enquiry based self-directed approach.*

- *The intricacies of studying 3D morphology for the first time, plus having to remember a number of cogent facts is difficult for students that only carry small amounts of factual information through from A-level, and when faced with memory accumulation struggle to develop this skill, as most of their prior experiences are memory dump to gain marks and get required grades*
- *At first, but they see it as very relevant so engage well and perform very well in assessments*

In disagreement:

- *The students just find it tedious and don't take it all in until they can apply their knowledge in the phantom head situation where they can begin to understand the importance of understanding morphology*
- *Tooth morphology has to be taught in conjunction with the clinical implications on the acquired knowledge*

Discussion

Fundamental and thorough knowledge of tooth morphology is relevant to all aspects of a dental career (Obrez *et al*., 2011; de Azevedo Rde *et al*., 2015; Myhrer *et al*., 2016). Tooth morphology equips students with the knowledge required to identify the teeth and to differentiate between normal teeth and those presenting anomalies, thus providing students with the ability to diagnose and treat dental pathologies (Obrez *et al*., 2011; Boushell and Sturdevant, 2012). Tooth morphology assists in developing the aesthetic sense of the dental student and teaching aids, like tooth carving exercises, aim to develop their manual dexterity and psychomotor skills (de Azevedo Rde *et al*., 2015). Currently, no peer-review article documents the profile of the dental anatomists / dentist employed to teach tooth morphology, and the various teaching aids / strategies employed to teach the dental students in the United Kingdom and Ireland. However, a similar document does exist for medical students (Heylings, 2002).

A high response rate was essential for this survey as the number of tooth morphology teaching staff is limited. The individual rate of completion was high (76%) and thus the data collected represents the majority of the dental schools in the United Kingdom and Ireland. Interestingly, our results revealed that the majority of respondents (11/16) have completed a dental degree. Considering the central role of tooth morphology in dental practice, it is revealing of the importance of the discipline in the curriculum of each institution.

PowerPoint™ was the modality of choice and use for lectures with the totality of the respondents. While PowerPoint™ offers many possibilities including the insertion of visual cues and animations that are important for multimedia learning (Moreno and Mayer, 1999; Mayer, 2002a), results from our survey showed that all the institutions surveyed supplemented their PowerPoint presentations with multiple additional

modalities such as models, videos or animations. Visual and blended-learning approaches are considered to be important tools in developing spatial understanding of anatomical structures (Carmichael and Pawlina, 2000). In particular, animations have been shown to effectively stimulate learner interest and thus enhance the learning experience (Clark, 2008). In addition, blended-learning techniques cater to multiple learning styles and have been shown to provide better outcomes than traditional lecture delivery (Pereira *et al*., 2007; Kiviniemi, 2014; McLaughlin *et al*., 2015).

The data indicates that the majority of institutions surveyed offer some form of e-learning. When further queried, the results showed that the definition of e-learning varied massively between respondents. Some considered the availability of lecture notes on the institutional VLE as e-learning while others reported a fully developed package of digital lectures and supporting tools. E-learning offers many advantages to students. The learner has complete control over the learning process (rate and time of delivery for example), thus empowering them towards the achievement of learning objectives (Ruiz *et al*., 2009). The rapidly evolving technology and the development of more complete e-learning packages will allow students to reap the benefits of e-learning, allowing a de-centralization of teaching, leading to a stimulating and satisfying learning experience. However, implementation of a new teaching strategies or changes to the current teaching methods should be considered based on current evidence and best practise keeping the students in mind (Hendricson, 2012; Khatoon *et al*., 2013).

Plastic teeth were used by the majority of the respondents for teaching and examination of tooth morphology. Extracted teeth, tooth atlases, drawing exercises and wax carving further supplement teaching during practicals. While plastic teeth are readily available for teaching they do not offer the variations commonly seen with extracted teeth. On the other hand, restrictions on retention of anatomical material,

infection control and deterioration of material have posed a certain number of hurdles to the use of extracted teeth. Learning anatomical morphology and its variation is important for correct identification of pathologies. The results of the survey show that the majority of the schools in the United Kingdom and Ireland teach both normal and abnormal morphology, including variations and pathologies. While teaching of anomalies may be limited by the availability of extracted teeth, all the institutions surveyed supplement the use of teeth with other material for the purpose of practical teaching and examination.

Conclusion

Tooth morphology requires visualization and understanding of the features of the teeth and their dynamic interactions with each other. It is an important element of the dental curriculum, although students might not realize it at the time and may not recall all the information in their clinical years or career to follow (Obrez *et al*., 2011). A good knowledge of tooth anatomy is vital for all aspects of dental careers including restorative, surgery, prosthodontics and endodontics. Comprehensive knowledge of anatomy assists in the identification of abnormalities and even pathologies. The results to the survey demonstrate that the dental schools in the United Kingdom and Ireland have developed various approaches to teach tooth morphology. The rapid evolution and availability of teaching supplements has allowed the development of programmes from a lecture / extracted teeth-based curriculum to one that caters for multiple learning styles and offers a high degree of flexibility as we are developing more complex programmes.

CHAPTER 6

Development of an Online Tooth Morphology 3D Quiz to Enhance Dental Student Learning

Lone M[1], Vagg T[2], Theocharopoulos A[3], Cryan JF[1], Downer EJ[4], McKenna JP[3] and Toulouse A[1]

[1]Department of Anatomy and Neuroscience, University College Cork, Cork.

[2]Department of Computer Science, University College Cork, Cork.

[3]Cork University Dental School and Hospital, Cork.

[4]School of Medicine, Discipline of Physiology, Trinity College Dublin, Dublin.

Paper published in *INTED2017 Proceedings*.

Abstract

The capacity to recognize the 3-dimensional (3D) features of teeth is an essential skill for the practice of dentistry. At University College Cork (UCC), tooth morphology is taught in the second year of the dentistry programme. Traditional teaching methods include studying with extracted and/or plastic teeth, drawings and wax/chalk carvings, and have been supplemented with 3D computer generated models, all of which allow for the acquisition of the necessary skills and knowledge. The assessment of modules via quizzes (with feedback) promotes active learning, assists in examination preparation and has been shown to motivate students.

The aim of this study was to develop and assess a tooth morphology quiz that incorporates interactive digital 3D models of teeth. Extracted human teeth and high quality plastic teeth were obtained and scanned. Once scanned, all 32 teeth were imported to Blender and applied with a custom material. The 3D quiz environment was created using the Unreal Engine.

The pilot study feedback shows promise for such a 3D quiz in dental education. Solutions to the issues identified in this study have now been implemented in preparation for formal testing with dental students. It is anticipated that the proposed 3D tooth morphology quiz will aid students with acquiring and retaining dental morphology knowledge.

Keywords: Innovation, quiz, 3D technology, tooth morphology.

Introduction

Tooth morphology is the study of the anatomy and structure of the permanent and deciduous teeth (Obrez *et al*., 2011). In Ireland, tooth morphology is usually taught to undergraduate dental students in the second year of their professional degree. Tooth morphology requires visualization and understanding of the various features of the human teeth and their dynamic interactions with each other. Traditional teaching methods vary depending on the institution but may include studying with extracted teeth and/or plastic models, drawing teeth or carving teeth in dental wax or chalk (Bogacki *et al*., 2004; Mitov *et al*., 2010; Obrez *et al*., 2011). In recent years, these have been supplemented with computer-generated 3D models. These allow for the spatial understanding and visualization of the relationship between different structures. Current dental students are being called the Net Generation or digital natives (Maggio *et al*., 2012). E-learning has been introduced in many dental schools that deliver online modules (Mitov *et al*., 2010; Maggio *et al*., 2012). Some studies have shown that the students developed a preference for this type of learning over the conventional lectures (Amer *et al*., 2011). Assessment tools such as quizzes with feedback have been shown to promote active learning and improve learning (Bogacki *et al*., 2004). Assessing students' perception of their learning successfully gauges the programme's achievement (Mitov *et al*., 2010).

A recent survey of British and Irish dental schools revealed that the majority are using blended learning strategies including e-learning approaches (Lone *et al*., in preparation). E-learning offers many advantages, including control over the learning process and individualisation of the learning experience, thus empowering the learner in meeting their curricular objectives (Ruiz *et al*., 2009). Indeed, it has been suggested that

the benefits accomplished from blended learning, e-learning and various new teaching aids an active learning experience, stimulating learners and leading to higher satisfaction rates (Faisal *et al*., 2015). Learning with 3D apps and quizzes has also been shown to cater for differences in learning styles and lead to improved results (Pereira *et al*., 2007). However, implementation of a new teaching method or changes to existing ones should be based on evidence and best practise while keeping the learners in mind (Evans *et al*., 2013).

The aim of this study was to develop and assess a tooth morphology quiz that would incorporate digital 3D models of teeth.

Material and Methods

Scanning the teeth

Extracted human teeth obtained through Cork University Dental School and Hospital and high quality plastic replicas (Adult teeth set, MJ18, Adam Rouilly, Kent, UK) were used. The human teeth were meticulously cleaned. A dental 3D contact surface scanner (DS10, Incise, Renishaw, Gloucestershire, UK) was used to create 3D surface files of the teeth. Each tooth was scanned using a combination of styli (4mm and 1mm ∅) using the scanner software (Incise CAD™ ver. 2.5.0.140, Renishaw, Gloucestershire, UK). In order to scan the teeth, several scans per tooth (2 - 6) were performed from different orientations (e.g. crown, root/s). Care was taken in order for the scans from different surfaces of the same tooth to have sufficient overlap so that they could then be superimposed using appropriate software. The small stylus (1mm ∅) could not scan the intricate fissures and grooves on the occlusal surfaces (Figure 6.2A). Instead, hard impressions (Photo curing resin, Voco, Cuxhaven Germany) of the occlusal surfaces were generated and scanned. All scans were then exported as ".stl" files and sequentially imported in pairs to GOM inspect software (V7.5 SR2, Braunschweig, Germany). All unwanted areas (e.g. undercut areas) were deleted from the scans (Figure 6.1A, B). Each pair (e.g. a crown scan and a root scan) was initially aligned (gross alignment) using the tool "3-point alignment" (Figure 6.1C). The grossly aligned pairs were then accurately aligned using the tool "Local best fit" that utilises the overlapping areas in order to bring the scans to complete alignment (Figure 6.1D). The pairs were then "stitched" into one complete 3D digital model. If more than two scans had been performed on one tooth, the next scan was imported and aligned to the 3D model in a similar fashion. When an occlusal surface had been scanned on the hard resin

impression (Figure 6.2B), the scan was cropped so that only the intricate occlusal characteristics were kept. It was then inverted using the command “Invert selected normals”. The inverted occlusal scan was then aligned to the 3D model of the tooth (Figure 6.2C) using the same process as above. The gross occlusal details from the 3D model were then deleted and replaced by the more accurate occlusal scan of the hard impression. Finally, the occlusal scan was “stitched” to the 3D model (Figure 6.2D). The complete 3D model was then exported as an “.stl” file.

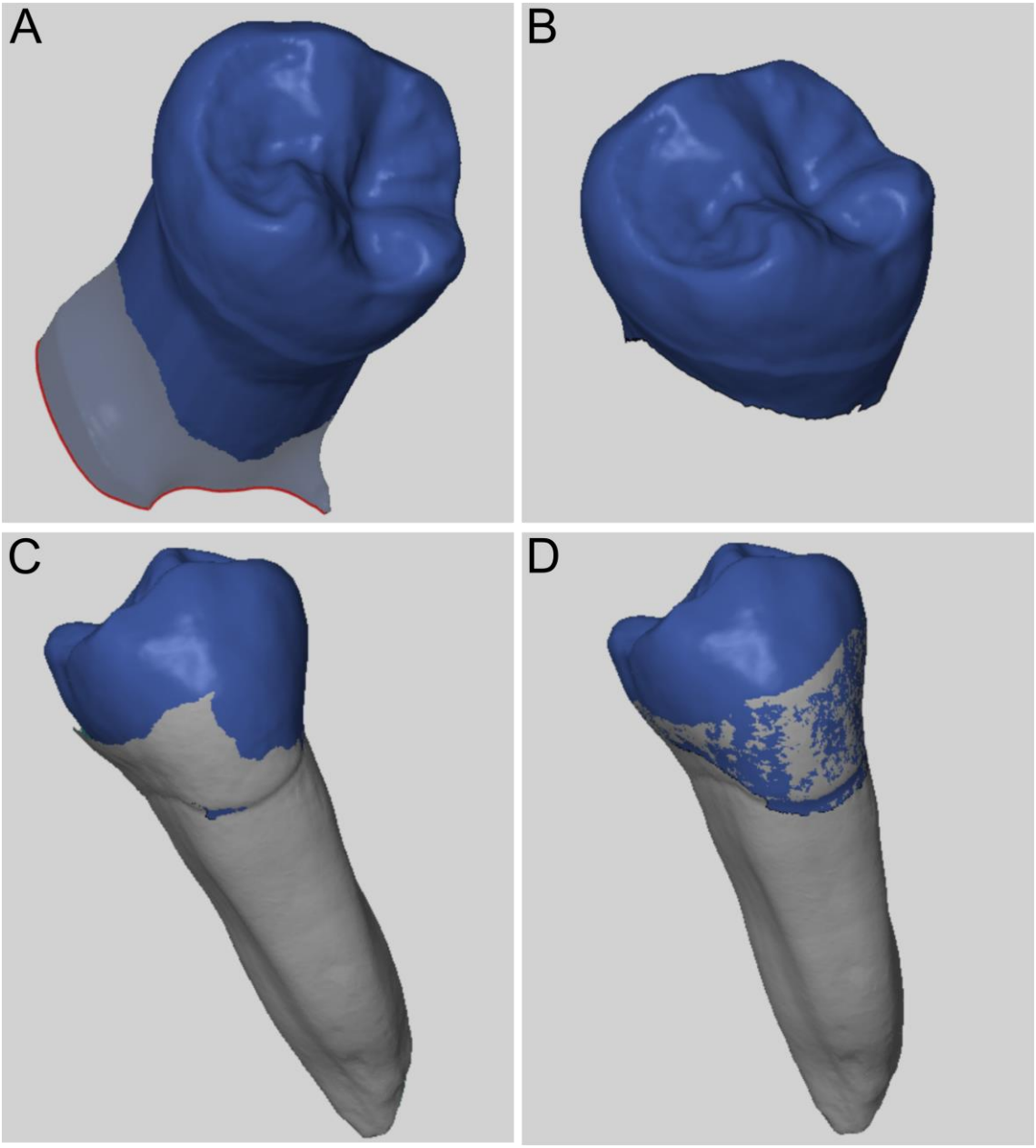

Figure 6.1: Sequential reconstruction of digitalised teeth. (A) Crown scan with some unwanted areas to be deleted. (B) Crown scan cropped. (C) Initial alignment of crown with root. (D) Final alignment with overlapping areas.

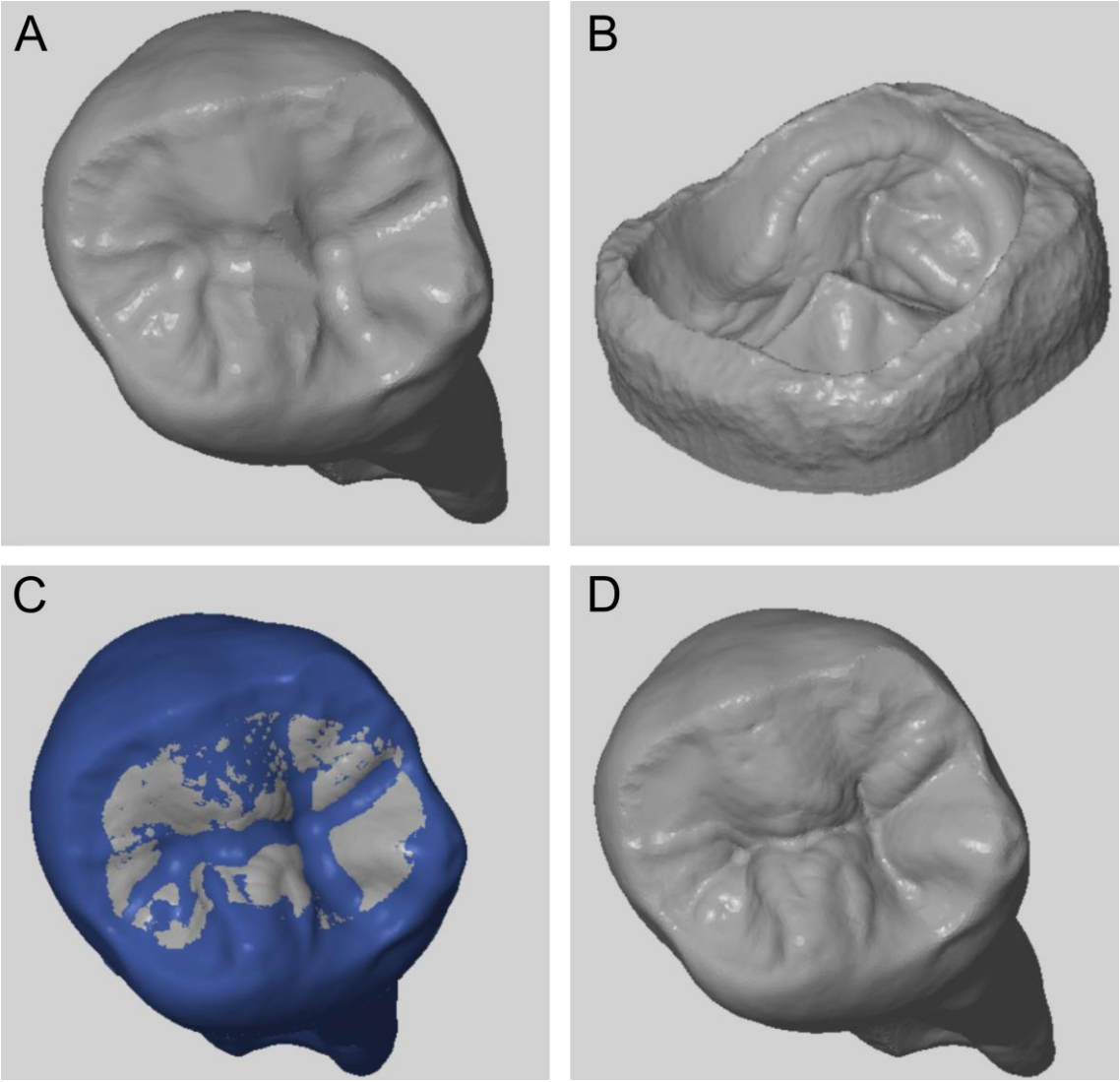

Figure 6.2: Reconstruction of the digitalised occlusal surface. (A) Occlusal view of the initial tooth 3D model scanned with 1mm ∅ stylus showing incomplete fissure structure. (B) Scanned hard impression of the occlusal surface. (C) Alignment of the inverted and cropped occlusal impression with the initial tooth 3D model showing the differences mainly lying at the fissure area. (D) Final 3D model of tooth after cropping the incomplete fissure structure and stitching showing clear occlusal details.

Development of the tooth morphology app

Once all 32 teeth were scanned, the teeth were imported to Blender version 2.7.3 and applied with a custom texture created from images of the scanned teeth (Figure 6.3A). The 3D quiz environment was created using the Unreal Engine 4.9.2. On opening the tool, the users are presented with a menu where they can enter the quiz environment or watch a short animation of the features of the tool. On entering the quiz environment,

the user is prompted to insert a pre-assigned identifier (e.g. student registration number) that will enable the tracking of progress and will also facilitate automated data collection for the next phase of the study. The environment consists of a labelled Fédération Dentaire Internationale (FDI, ISO 3950) dental notation charting system and 10 3D teeth randomly selected from the 32 permanent teeth implemented in the app. The user has the option to “left click” to drag a tooth to a location on the FDI chart, or “right click” to zoom in on a tooth and rotate it in 3D view to study various aspects before submitting to the selected location on the chart. On completing the quiz, the user is presented with a feedback screen, which is overlaid onto the main viewport (Figure 6.3B). This screen shows a small image of the teeth and where they were submitted on the grid. For this view, the coloration of the teeth has been altered to a standard diffuse red or green to denote that the submission is correct or incorrect. To the right of this image the user can select from a list of buttons corresponding to the incorrect entries. After selection, the corresponding tooth will be highlighted in yellow and textual feedback of the main identifying features will be provided. The system's backend then creates a file in the system directory for each new user number. The date, time taken in the 3D quiz environment, score, and list of incorrect teeth are then recorded into this file. If a user returns to the tool this data is then stored in their respective file. This allows for monitoring of scores over time and also repetitions in incorrect answers.

The system was subjected to an informal pilot usability study with six medical students and after amendments pilot feedback was obtained from 22 third year dental students.

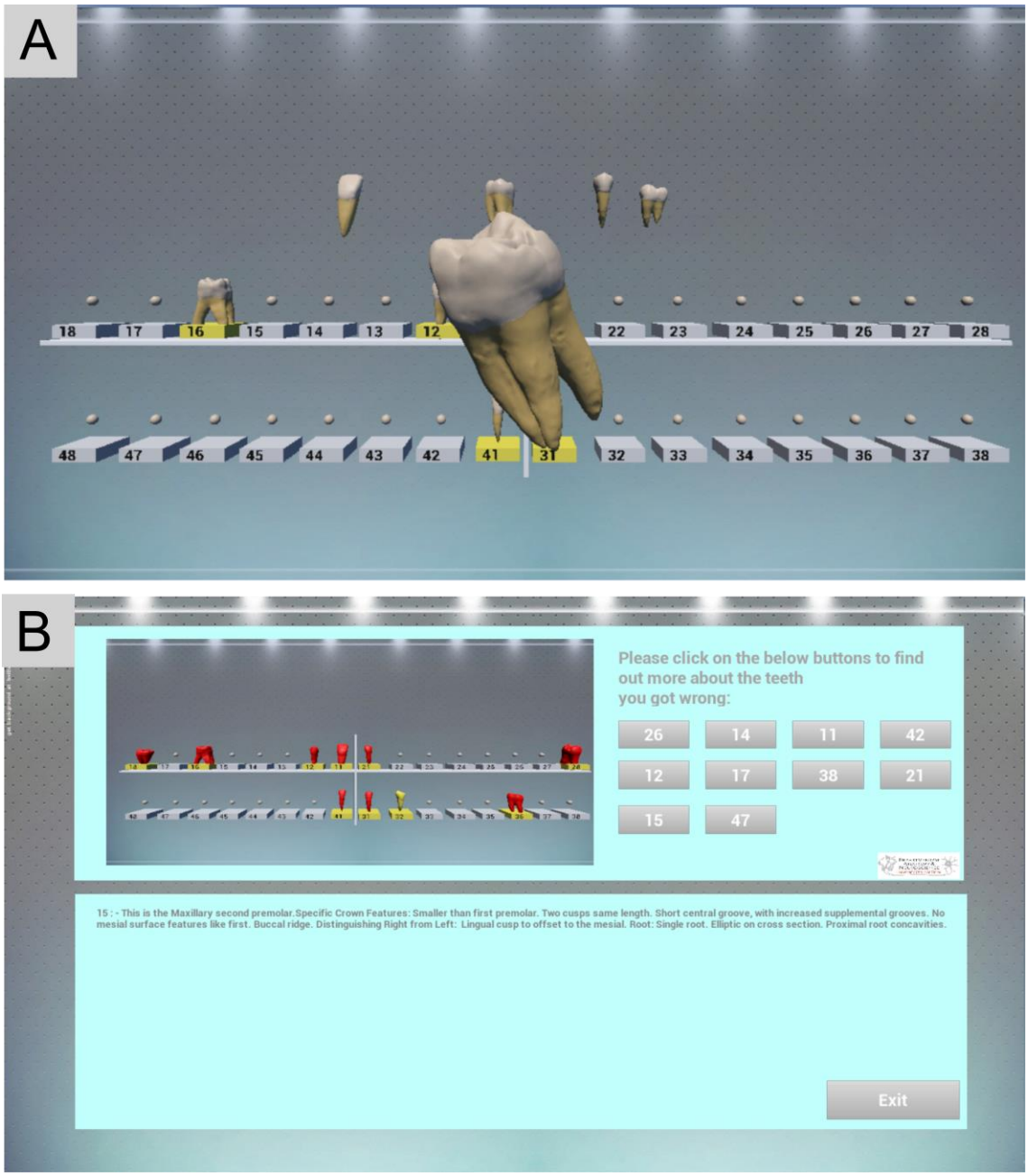

Figure 6.3: Representative images of the quiz environment. (A) Dental annotation screen with dental notation, 3D teeth and tooth currently being studied. (B) Exit screen with correct/incorrect answers and written feedback.

Results

Usability testing

Pilot data was collected from six medical students with no knowledge of tooth morphology. Questions pertained to the general design of the app as well as its appearance and ease of use. Verbal feedback was collected from each of the participants in an open discussion with the first author of this manuscript. The data indicated that the students thought that using the quiz was enjoyable and easy. Importantly, they felt that it displayed the 3-dimensional features of the teeth clearly. However, the participants noted that movement of teeth across the screen was not smooth and even jerky at times. In addition, students indicated that the quantity of textual information on the feedback screen was overwhelming. Students also reported that it was unclear how to submit the selected tooth to the charting grid. Solutions to the issues identified in this study have now been implemented in preparation for formal testing with dental students. It is anticipated that the proposed 3D tooth morphology quiz will aid students in learning dental morphology.

Pilot feedback

A second set of pilot data (Appendix 17) was collected from 22 third year dental students. The participants had completed a tooth morphology course in this institution in the previous semester using extracted teeth and plastic models as teaching aids. Participation was voluntary and informed consent was obtained from the participants. Ethical approval (ref 2016-107A) for the study was obtained from the Social Research Ethics Committee, UCC. Following a demonstration of the features of the app, the students completed the quiz and a short questionnaire collected their opinion about the app. Results show that 9 (40.9%) of the participants had used a tooth morphology app

previously. Sixteen participants (72.7%) rated the app as useful/very useful when compared to apps they had used for other topics.

The clarity of the tooth rendering was rated highly with participants finding the crown (19/22, 86.4%) and the root (16/22, 72.7%) features clear to very clear. 18 (81.8%) participants could recognize the teeth clearly with 21 (95.5%) reporting that the 3D image of the tooth was very realistic, with all 22 (100%) of the participants stating that the app conveyed the 3D features of the tooth clearly. While the app showed the teeth very clearly, the participants felt that it was difficult to rotate and manoeuvre the 3D tooth images and hence a significant proportion of the participants (12, 54.5%) felt that the 3D interface did not allow suitable orientation of the teeth and created difficulty in identifying the teeth. The vast majority of the participants (21, 95.5%) felt that the quadrants in the charting area were clear to see, while more than half (13, 59.1%) felt that it was easy to place the teeth in the quadrants.

When the participants were asked to rate their usability experience with the app and identifying the teeth on a Likert scale (1= easy to 5= difficult), 9 (40.9%) participants reported it difficult to use, 9 (40.9%) reporting it neither difficult nor easy to use and only 4 (18.1%) rating the app as easy to use. Participants were also asked questions pertaining to the feedback given at the end of the quiz. All 22 (100%) participants agreed that the app was a good learning tool with 21 (95.5%) participants agreeing that the colour contrast was appropriate and that they enjoyed using the app. All participants felt that the scoring provided at the end was beneficial and the feedback provided was both appropriate and helpful. Twenty-one (95.5%) participants agreed that they would use an app like this and reported that using the app was a positive experience.

Students' scores were also generated after using the quiz. A total of 22 students participated in the pilot data collection, whose scores ranged from 0-6 with an average score of 3.23.

Discussion

The results demonstrate promise for this application. The majority of users found that the application had sufficient details of the tooth, both crown and root morphology to allow identification of the teeth. While their scores may not reflect this, it is important to note that the participants had received their training in tooth morphology eight months prior to this survey and were not asked to review their material. It is not unusual to see a decline in knowledge between first acquisition of knowledge and routine application in the clinic. In this context, the feedback and data suggest that while the rendering is appropriate for identification, the knowledge of the participants needs to be improved and they may benefit from using this quiz. Indeed, all the participants appreciated the app as a learning tool and positively rated the feedback at the end of the quiz. Ninety-six percent of the participants agreed that they would use this app if available to them and reported that using the app and participating in the pilot study was a positive experience.

The 3D interface, particularly the rotation of the teeth proved to be problematic with the users unable to turn the tooth 360° in all directions and thus stating that it hindered them with identifying the teeth properly, particularly on the root side. While the interface currently allows rotation of the tooth to bring the coronal or root surfaces into view, the users felt that this somewhat limited their capacity to identify some of the distinguishing features, particularly when trying to differentiate between teeth with similar morphology. This difficulty may have influenced the poor outcome on the ease of use of the app with only 18% judging it easy to use. Furthermore, the pilot data was performed on laptop computers using the trackpad, the overall performance of the computer and the familiarity of the users with a trackpad while performing rotation and

moving the teeth may also have influenced the poor usability ratings. Finally, despite improvement between the usability testing and pilot study, issues were identified with the final feedback screen. While all participants reported that the content was appropriate and useful, some raised concerns with the layout of the text, suggesting the use of bullet points. Solutions to these issues are being considered and will be implemented for the testing version.

Conclusion

The present study illustrates a clear strategy for the design and implementation of a computer-aided learning tool for tooth morphology. While 3D applications already exist for the identification of distinguishing features to aid in recognition of teeth, the introduction of the quiz element serves to reinforce the acquisition and retention of knowledge. The proposed application offers a 3D visual support to aid in assimilating the general morphology of the teeth but in addition, the quiz element will ensure engagement with a more dynamic learning process. The feedback provided at the end allows the user to self-correct and keep track of their performance over time. It is anticipated that the application will be tested on a target audience of 2nd year dental students and compared with traditional learning methods. It is hypothesized that an interactive, 3D learning resource that is aligned with the learning principles will have a positive impact on the student learning outcomes when integrated with the current teaching methods for dental students.

Chapter 7

Development and Assessment of an Electronic 3D Tooth Morphology Quiz for Dental Students

Lone M[1], Vagg T[2], Theocharopoulos A[3], McKenna JP[3], Cryan JF[1], Downer EJ[4] and Toulouse A[1]

[1]Department of Anatomy and Neuroscience, University College Cork, Cork.
[2]Department of Computer Science, University College Cork, Cork.
[3]Cork University Dental School and Hospital, University College Cork, Cork.
[4]School of Medicine, Discipline of Physiology, Trinity College Dublin, Dublin.

Paper submitted to *Anatomical Sciences Education.*

Abstract

Tooth morphology has a pivotal role in the dental curriculum and provides the foundation for the clinical years. To supplement tooth morphology teaching, a 3D quiz app 'TMQ' was developed. This 3D resource enables students to study tooth morphology actively by selecting teeth from an interactive quiz, modifying their viewpoint and level of zoom of a particular tooth. Additionally, students are able to rotate each selected tooth to obtain a 3D spatial understanding of the different surfaces of the tooth. A cross-over study was designed to allow comparison of students' comprehension after studying with each teaching modality i.e. extracted teeth or TMQ. Results showed no difference in performance between students using the TMQ or extracted teeth. However, in the early stages of learning tooth morphology, male participants performed better than females, possibly due to a better grasp of 3D complexity as measured by a mental rotation test. In addition, correlations show that student performance is positively correlated throughout the various phases of the assessment. Finally, a comparison of two student cohorts (2016 *vs.* 2017) shows that students have significantly benefited from the implementation of the TMQ, as the overall class assessment was significantly higher for the 2017 group. Furthermore, students found that the 3D application was easy to use, it presented the key features of the teeth clearly and assisted in learning tooth morphology. In conclusion, our results show that the TMQ benefits students in developing their capacity to recognise the individual morphological features of teeth.

Introduction

The study of tooth anatomy and morphology are integral for the foundation of the dental career (Bogacki *et al*., 2004; Kato and Ohno, 2009; Cantín *et al*., 2015; de Azevedo Rde *et al*., 2015). Tooth morphology is the study of the anatomy and morphology of permanent and deciduous teeth (Obrez *et al*., 2011) and is usually taught in initial years of the dental course (Kilistoff *et al*., 2013) enhancing aesthetic development (de Azevedo Rde *et al*., 2015) and psychomotor skill development (Obrez *et al*., 2011). Dental science students, dental technicians and dental nurses study detailed tooth morphology as it aids in recreating lost tooth structure for clinical work and also assists in dental lab work (Abu Eid *et al*., 2013; de Azevedo Rde *et al*., 2015; Bakr *et al*., 2016). Furthermore, knowledge of anatomical features of the teeth also helps in distinction of normal anatomy versus developmental anomalies and pathology (Obrez *et al*., 2011; Bakr *et al*., 2016). Although this module is taught in the first two years of the dental course, its application and use is in the clinical years leading to what some refer to as ‘decontextualized technique learning’ (Bogacki *et al*., 2004; Obrez *et al*., 2011; de Azevedo Rde *et al*., 2015; Magne, 2015).

Traditional methods of teaching tooth morphology include lectures (Bogacki *et al*., 2004) and practical study sessions with extracted (Mitov *et al*., 2010; Cantín *et al*., 2015) and plastic teeth (Obrez *et al*., 2011), carving teeth (Wallen *et al*., 1997; de Azevedo Rde *et al*., 2015) and drawing 2D images of teeth (Abu Eid *et al*., 2013; Magne, 2015). While studying with extracted teeth is preferred (Cantín *et al*., 2015) there are numerous associated considerations including adequate number of teaching teeth without decay or wear, hygiene and ethical concerns (Cantín *et al*., 2015).

Traditional methods of teaching dental anatomy need augmentation with innovative teaching methods in order to maintain students' interest and address different learning styles (Bogacki *et al*., 2004; Cantín *et al*., 2015). Teaching anatomy in 3D allows visualization and spatial understanding of the relationship between different structures (Allen *et al*., 2016). Additionally, assessment modules have also been shown to be a useful tool (Mitov *et al*., 2010). Online tests/quizzes have been shown to motivate students and can be invaluable in preparing them for the examination (Bogacki *et al*., 2004) with students themselves preferring examination related material (Jastrow and Hollinderbaumer, 2004; Jackson *et al*., 2011). Online tests allow students to assess their knowledge and provide immediate feedback which is helpful in long-term retention of knowledge (Wright and Hendricson, 2010; Baker *et al*., 2013).

3D interactive tooth morphology atlas has been shown to interest students and enhance their learning (Mitov *et al*., 2010; Wright and Hendricson, 2010). Previous studies have also reported that students prefer simplicity and quick accessibility of the programs so as not to waste time with technical issues and unnecessary delays (Mitov *et al*., 2010). Furthermore, CAL supports traditional teaching leading to blended learning methods (Nance *et al*., 2009; Maggio *et al*., 2012). Use of CAL provides user flexibility in learning 'at their own pace' and the opportunity to review or repeat the material multiple times while simultaneously reducing faculty's workload (Nance *et al*., 2009).

The aim of the study was to develop and assess a 3D quiz app 'TMQ' used to teach tooth morphology to dental students in UCC. The authors hypothesize that TMQ would assist in student learning of tooth morphology.

Materials and Methods

Extracted human teeth and high quality plastic replica teeth (set of 32 permanent teeth) used for teaching tooth morphology were utilized for the study. The teeth were scanned and stl files for each tooth were imported into Blender version 2.7.3. Unreal Engine 4.9.2 was used to create the 3D quiz environment. Details about the scanning and development of the app have been described in another paper (Lone *et al*., 2017) (Chapter 6).

A pilot study was performed with third year dental students who would have studied tooth morphology the previous year. Following informed consent, students used the TMQ and provided feedback (Appendix 17). Recommendations from the pilot data was subsequently incorporated into the quiz.

Study Design

The study was a randomized controlled trial with 64 second year dental and first year dental hygiene students enrolled in a 12-week module of dental morphology, histology and embryology taught in UCC. The dental anatomy curriculum is taught in the second semester to second year dental students and first year dental hygiene students within the Department of Anatomy and Neuroscience and includes 11 hours of lectures and 17 hours of practical sessions where students have access to study with extracted teeth and plastic teeth. This module is supported by the university's web-based learning '*Blackboard*™' and allows student access to lecture/practical notes, e-learning resources and provides a means of communication between the educator and the students. The students are assessed with an end of the year spot examination with 20 extracted teeth and a written examination consisting of multiple choice questions, short-answer questions and essay questions.

Informed consent was obtained at the start of the study (Appendix 15). Participants were randomly assigned into either the TMQ group or extracted teeth group which accessed the learning modalities in opposite order (Figure. 7.1). Students in group A first accessed TMQ for 3 weeks to study tooth morphology followed by studying with extracted teeth for another 3 weeks. Students in group B initially used extracted teeth to study tooth morphology for 3 weeks followed by access to TMQ for another 3 weeks. The extracted teeth group were provided a set of 32 extracted teeth along with flash cards from Fehrenbach's student workbook of 'Illustrated Dental Embryology, Histology and Anatomy' (Fehrenbach, 2016). TMQ group studied the 3D tooth while using the quiz. The feedback provided at the end of the quiz was identical to the flashcards from Fehrenbach. The duration of each practical session was 30-40 minutes and no electronic equipment was allowed in the practical sessions. Both groups attended the same lectures, had labs together at the same time but in different rooms. Following studying with the first learning modality (3 weeks) a spot examination, Mock examination 1, was conducted with 20 stations where 10 stations had extracted teeth and 10 stations had digital teeth. Students were asked to identify the tooth and a mark was awarded for correct answer. Following exposure to the second teaching modality (another 3 weeks) a Mock examination 2 was conducted with 20 stations (similar to Mock examination 1). Moreover, the students had an end of the year tooth morphology spot examination and the examination scores were used for analysis (Figure 7.1). The total time commitment of participants for the study/practical sessions was approximately 3-4 hours. This study was approved by Social Research Ethics Committee (SREC), UCC.

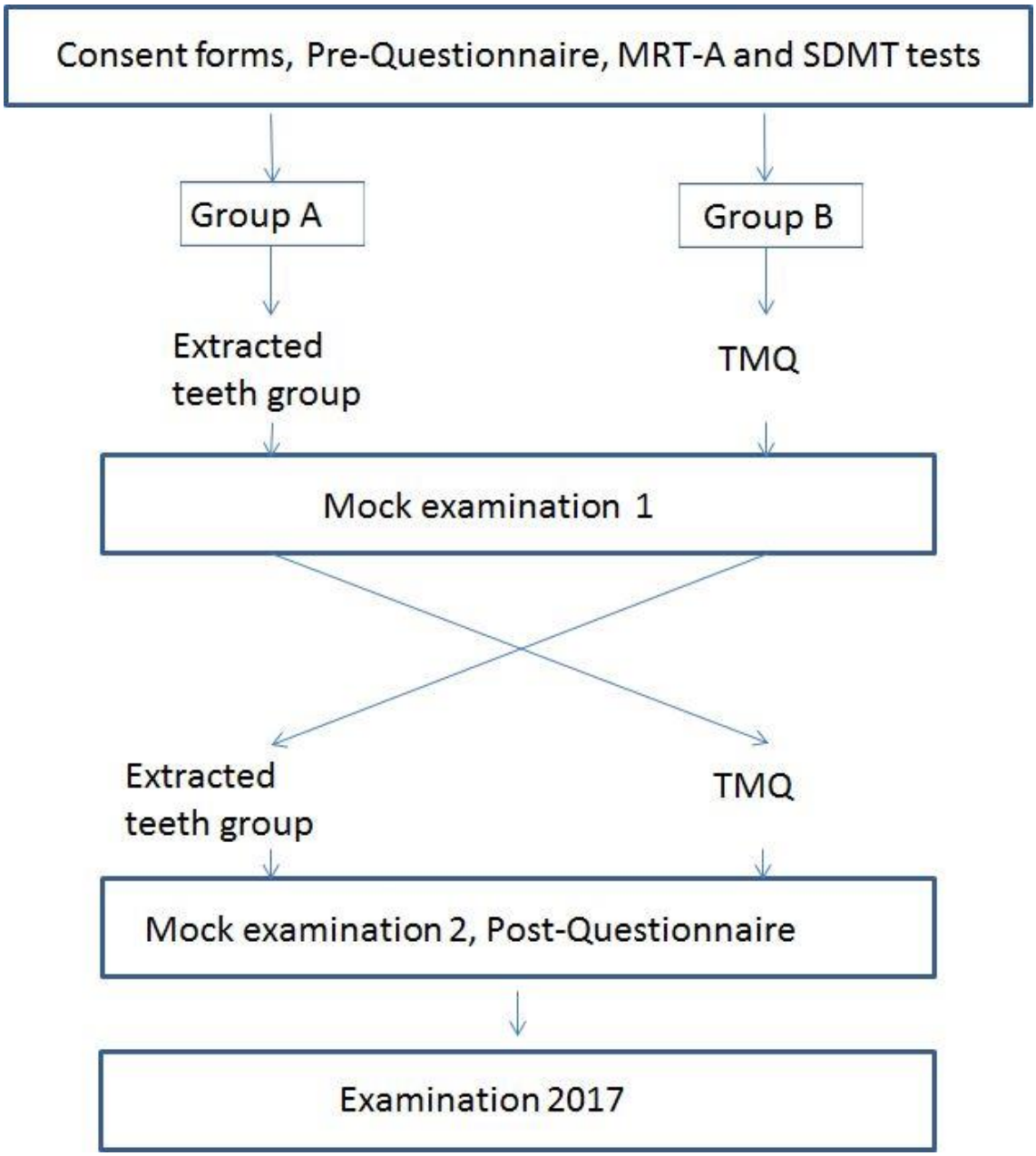

Figure 7.1: Schematic illustration of the tooth morphology cross-over study design. Students were randomly assigned to group A or B. Each group accessed a teaching modality for 3 weeks with a cross over to the other modality for another 3 weeks. Mock examination 1 was conducted before the crossover and Mock examination 2 was conducted at the end of the study. Each mock examination comprised of 10 extracted teeth and 10 digital teeth questions. Examination 2017 was conducted with 20 extracted teeth. MRT-A, Mental Rotation Test-A; SDMT, Symbol Digit Modalities Test; TMQ, Tooth morphology quiz application; Ext teeth, Extracted teeth; Mock examination 1/2, Mock spot examination 1/2; Examination 2017, End of the year examination 2017.

Questionnaire Design

Pre- and post- questionnaires were developed for the study using Survey Monkey (SurveyMonkey, Inc., Palo Alto, CA). The questionnaires were designed by a multidisciplinary team of anatomists and dentists actively involved in teaching anatomy. Likert-style statements, binomial (yes/no) questions, quantitative rating questions or open-ended questions were utilized. All questionnaires were approved by SREC (Appendix 14). The pre-questionnaire comprised of 25 questions and collected data about student demographics, their learning styles, use of internet and online quiz (Appendix 12). The post-questionnaire comprised of 5 questions and collected data about student experience with using the app and studying with extracted teeth (Appendix 13). Senior medical demonstrators in the Department of Anatomy and Neuroscience at UCC were invited to participate in a trial run for validation of the questionnaires. A focus group session was also organized with the medical demonstrators and the questionnaire was then modified based on their feedback.

Mental Rotation Test Version-A (MRT-A)

Visual spatial assessment was performed by using the redrawn Vandenberg and Kuse MRT-A (Vandenberg and Kuse, 1978). This is the most commonly used version of MRT which examines ability of participants to mentally rotate figures around a vertical axis. The test comprised of 24 questions with each question showing a target figure on the left and four figures on the right. Out of four figures only two are rotated versions of the target figure. The test established participants' capacity to mentally rotate the target figures and identify the two correct answers (rotated versions of the target figure). A score of '1' was awarded only if both choices were correct with the maximum score attained being 24. The instructions, procedures and scoring methods were identical to those reported by Peters *et al*., (Peters *et al*., 1995). The MRT-A score

was compared to examination scores to determine a possible correlation between visual-spatial ability and the ability to recognize extracted/digital teeth.

Symbol Digit Modalities Test (SDMT)

The SDMT assesses the cognitive ability of individuals. The test involves participants converting geometric designs into number responses in a time span of 90 seconds. A key is provided with each geometric design corresponding to a specific number. A score of 1 is awarded for each correct response with a maximum attainable score of 110.

Statistical Analysis

Data were coded, anonymized and entered manually into Microsoft Excel spreadsheets. Data was then exported to the Statistical Package for Social Scientists (SPSS), version 22 (IBM Corp., Armonk, NY). Descriptive statistics (frequency and percentages) were used to summarize the data. Paired t-tests was performed to compare the means of the two groups (A and B). Pearson's correlation coefficient was utilized to identify correlation between variables. Answers to open-ended (qualitative) questions were tabulated, and themes were identified. Data are reported as means ± standard deviation (SD). Differences with a p value less than 0.05 were deemed statistically significant.

For ease of understanding and analysis the following terms will be used in results and discussion henceforth: Ext 1/2 (10 extracted teeth spot questions of Mock examination 1/2), 3D 1/2 (10 digital teeth spot questions of Mock examination 1/2), Mock examination 1 (total score of 20 spot questions in Mock examination 1), Mock examination 2 (total score of 20 spot questions in Mock examination 2), Examination

2017 (end of year spot examination for 2017), Examination 2016 (end of year spot examination for 2016).

Results

Demographics

All 64 dental students were included in the study. However, five students were missing at different assessment stages of the study and their data was excluded from final data analysis (n=59). Demographics of the participants are outlined in Table 7.1. The average age of the student was 22.8 ± 0.5 years (range, 18-37 years) and included 15 males and 44 females. The majority of the students were from Europe 29 (45.15%) with students from Canada, Asia and Middle East accounting for the remainder of the student cohort. Forty-eight participants were dental students (34 direct entry and 14 graduate entry dental students) with 11 dental hygiene students. Twenty-four participants (40.68%) had previously completed a third level education degree. Mean SDMT scores of participants was 63.27 (range 46-100) with MRT-A scores being 10.12 (range 0-20).

Table 7.1: Demographics of student cohort of 2017 and 2016.

Characteristics	2017	2016
n	59	64
Sex (F/M)	44/15	45/19
Age (years; mean ± SEM)	22.78 ± 0.48	22.97 ± 0.46
Region of origin		
Europe n (%)	29 (49.15)	44 (68.75)
Canada n (%)	18 (30.51)	16 (25)
Asia n (%)	11 (18.64)	4 (6.25)
Middle East n (%)	1 (1.70)	0 (0)
Direct entry dental students n (%)	34 (57.63)	40 (62.50)
Graduate entry dental student's n (%)	14 (23.73)	10 (15.63)
Dental hygiene student n (%)	11 (18.64)	14 (21.87)
Education level completed		
Secondary n (%)	27 (45.76)	---
Third level n (%)	24 (40.68)	---
Not specified n (%)	8 (13.56)	---
SDMT mean ± SEM (range)	63.27 ± 1.35 (46-100)	---
MRT mean ± SEM (range)	10.12 ± 0.72 (0-20)	---

SDMT, Symbols Digit Modalities Test; MRT-A, Mental Rotation Test-A

Student Preferred Device for Accessing Internet with Location and Device Used for Educational Purposes

Students' daily use of the internet and device preference was inquired. Data shows that student usage of internet on a typical weekday was 1-24 hours (5.78 ± 0.53; mean ± SEM) and on a typical weekend 1-22 hours (6.44 ± 0.52; mean ± SEM). Data gathered from pre-questionnaire shows that smartphones are the preferred device to access the internet (*n*=58, 98.31%) followed by laptops (*n*=51, 86.44%), tablet/ipad (*n*=13, 22.03%) and desktop (*n*=6, 10.17%). However, when inquired about the device

used for educational purposes, laptops are primarily preferred (*n*=52, 88.14%) followed by smartphones (*n*=20, 33.90%) (Fig. 7.2).

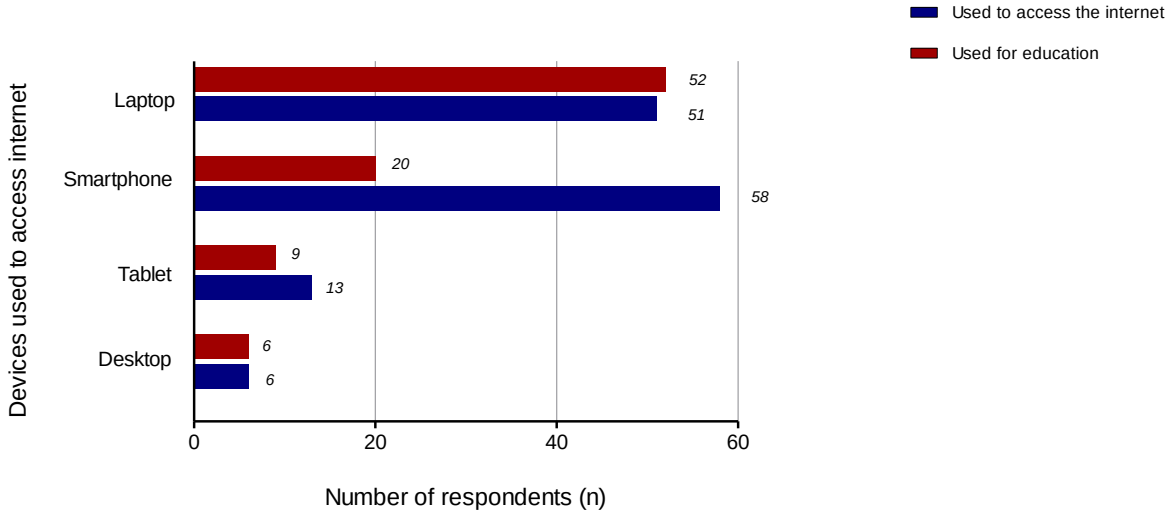

Figure 7.2: Student's preferred use of devices for daily access to the internet and for educational purposes. Red bars show devices used for educational use while blue bars show devices used for daily use. Data is represented as n=number of respondents.

Next students were asked about the location used for accessing the internet for educational purposes. Students' home was the primary location (*n*=54, 91.53%), followed by campus (*n*=42, 71.19 %) and public places including the library (*n*=27, 45.76%).

Participant's Online Activities

Participants were inquired about their online activities and asked to choose from a list of online activities. Participants were encouraged to choose as many activities as applicable. Analysis of data shows that social media was the most popular (*n*=59, 100 %), followed by education (*n*=58, 98.31%), communication via emails (*n*=56, 94.92%) and communication by Whatsapp and viber (*n*=51, 86.44%).

Next participants were asked to rate their three most frequent online activities. For the first preference 22 (37.29%) students chose education, followed by social media (*n*=10, 16.95%) and communications via email (*n*=10, 16.95%). For the second preference 17 (28.81%) students chose communication via email, followed by education (*n*=13, 22.03%) and social media (*n*=8, 13.56%). Third preference included communication (via what's app /viber) chosen by 13 (22.03%) students, social media (20.34%) chosen by 12, followed by 7 (11.86%) students choosing communication (via emails).

Students Learning Style and Confidence with Manoeuvring a 3D Image

Students' preferences of learning styles were also explored. Results show that 23 (38.98%) students prefer learning topics by reading text/notes, 21 students (35.59%) use illustrated texts while animation/videos are preferred by 33 (55.93%) students. Only 4 (6.78%) students prefer to listen to audio recordings. However, despite the majority of students not learning by using audio recordings, they strongly agreed that audio is very important to an educational video (*n*=46, 77.97%). Next students were asked to rate their confidence at manoeuvring a 3D image using a laptop/computer and mobile phone, expressed in a Likert scale where 1=very uncomfortable and 5=very comfortable. The majority of the participants reported confidence (very comfortable/comfortable) in manoeuvring a 3D image using the laptop/computer (*n*=42, 71.19%) and smartphone (*n*=47, 79.67%).

Participants' Use of Educational Apps, Game-based Learning and Online Quizzes

Students were questioned if they had ever downloaded an educational app on their mobile and if they enjoyed learning with games (binary responses, yes/no). The majority of students (*n*=45, 76.27%) had previously downloaded an educational app on their mobiles with more than half of students (*n*=38, 64.4%) reported enjoying learning

with games. Furthermore, students were asked if it was useful to perform an online search for a new/difficult topic and would they routinely perform an online search for a new/difficult topic expressed in a five-point Likert scale (5=all the time and 1=never). Almost all the students agreed that it is useful to perform an online search for a new/difficult topic (*n*=58, 98.31%) (Fig. 7.3A) with 51 students (86.44%) frequently or always performing these searches. 34 (57.6%) students would routinely search for online supplementary teaching aids and quizzes for a topic of interest (Fig. 7.3A).

Subsequent questions inquired about student opinion about benefits of online quizzes for testing themselves and routine use of online quizzes. Online quizzes were deemed useful for learning a topic by 49 (83.05%) students with 42 (71.2%) students using online quizzes to test themselves on a particular topic (Fig. 7.3B).

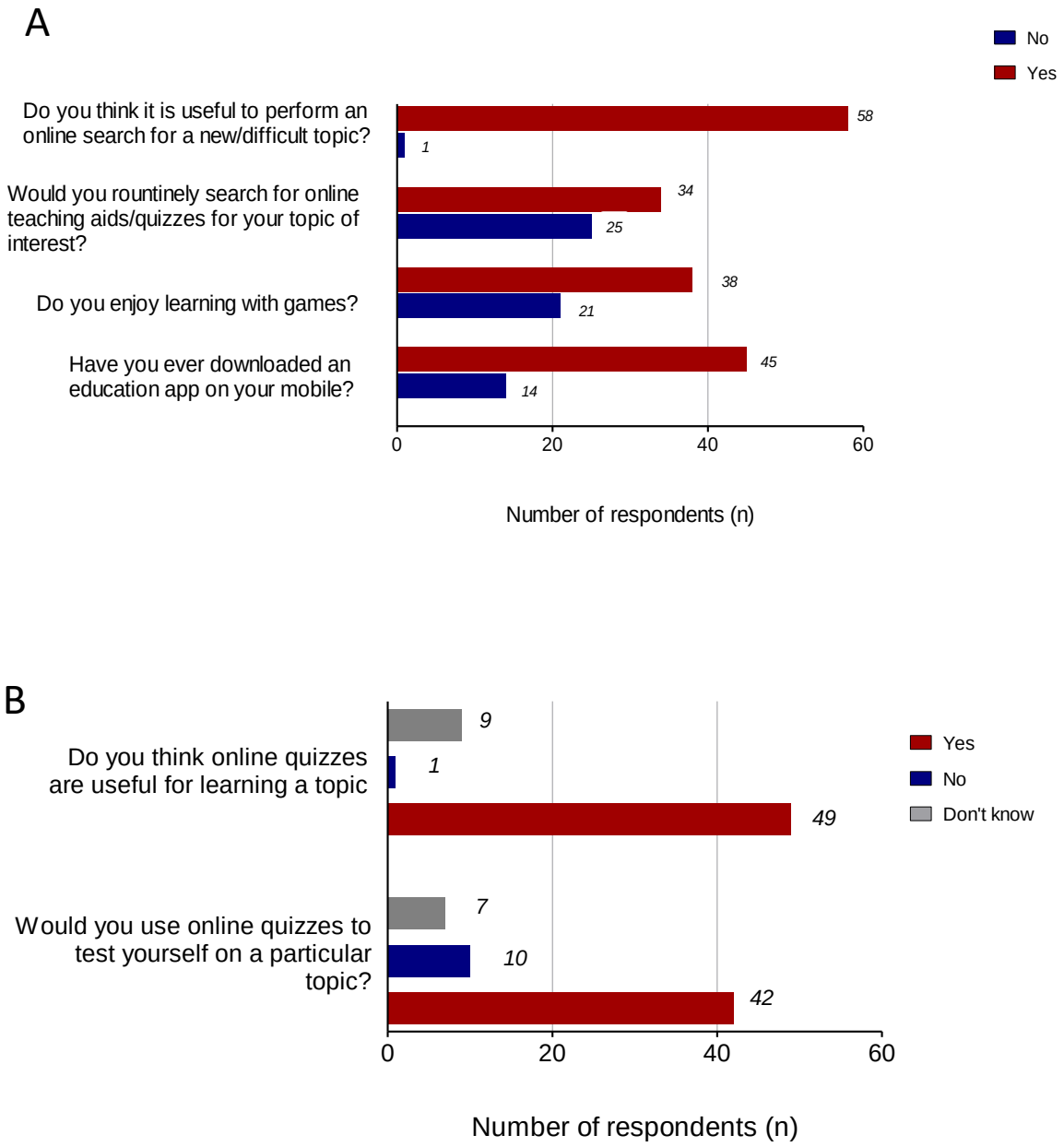

Figure 7.3: Student's' perception on learning. (A) Student's perception about performing online searches, learning with games and downloading apps on their mobiles. Red bars represent positive responses whereas blue bars represent negative responses. (B) Student's perception on using online quizzes for learning topics. Red bars represent positive responses whereas blue bars represent negative responses and grey bars represent don't know. Data is represented as n= number of respondents.

Access to the App

The app was utilized a total of 342 times by 64 students. The average score achieved was 3.152 (Range 0-10). Time spent on the app averaged 1285 sec/21 min (Range 66-2000 sec).

Analysis of the Results

Data was analyzed and found to be normally distributed. T-tests were used to analyse and identify potential intragroup and intergroup differences.

An independent t-test was performed to analyse the different variables between group A and B. There were no significant differences found between group A and B based on age, SDMT and MRT-A scores. Students' score in 3D 1/2, Ext 1/2 and Mock examination 1 and Mock examination 2 along with Examination 2017 were also analysed but yielded no significant differences. Thus, there was no difference ($p>0.05$) between group A and B based on all the different variables.

Paired t-test was conducted to compare the results of Mock examination 1 and Mock examination 2 (questions based on extracted teeth, digital teeth and total scores). Results for the questions based on extracted teeth and 3D teeth show a significant difference between Mock examination 1 and Mock examination 2 ($p<0.005$). A significant difference was also found when the total scores of Mock examination 1 and Mock examination 2 were compared ($p<0.005$). These results show that there was an increase in student scores in all aspects of Mock examination 2 when compared to scores from Mock examination 1 (Fig 7.4A).

The next step involved performing a paired t-test to compare all variables of group A and B based on their scores of Mock examination 1 and Mock examination 2 (extracted teeth score, digital teeth score and total scores). Students in group B had

significantly improved scores in questions on extracted teeth and total scores ($p<0.05$) of Mock 2. Students in group B initially accessed the extracted teeth for study and results show that they performed significantly better on extracted teeth questions and overall scores for Mock examination 2 as compared to Mock examination 1 (Fig 7.4B).

Gender analysis was also performed to compare the differences between males and females. There was no significant difference between the genders based on age, SDMT, 3D 2, Ext 2, Mock examination 2 and Examination 2017. However, there was a significant difference in MRT-A scores of males and females ($p<0.005$). There was also a significant difference in the 3D 1 scores, Ext 1 and Mock examination 1 between males and females ($p<0.005$). These results show that males had higher scores and performed significantly better ($p< 0.005$) than females in MRT-A test and all aspects of Mock examination 1 (3D 1, Ext 1 and total Mock examination 1) (Fig 7.4C).

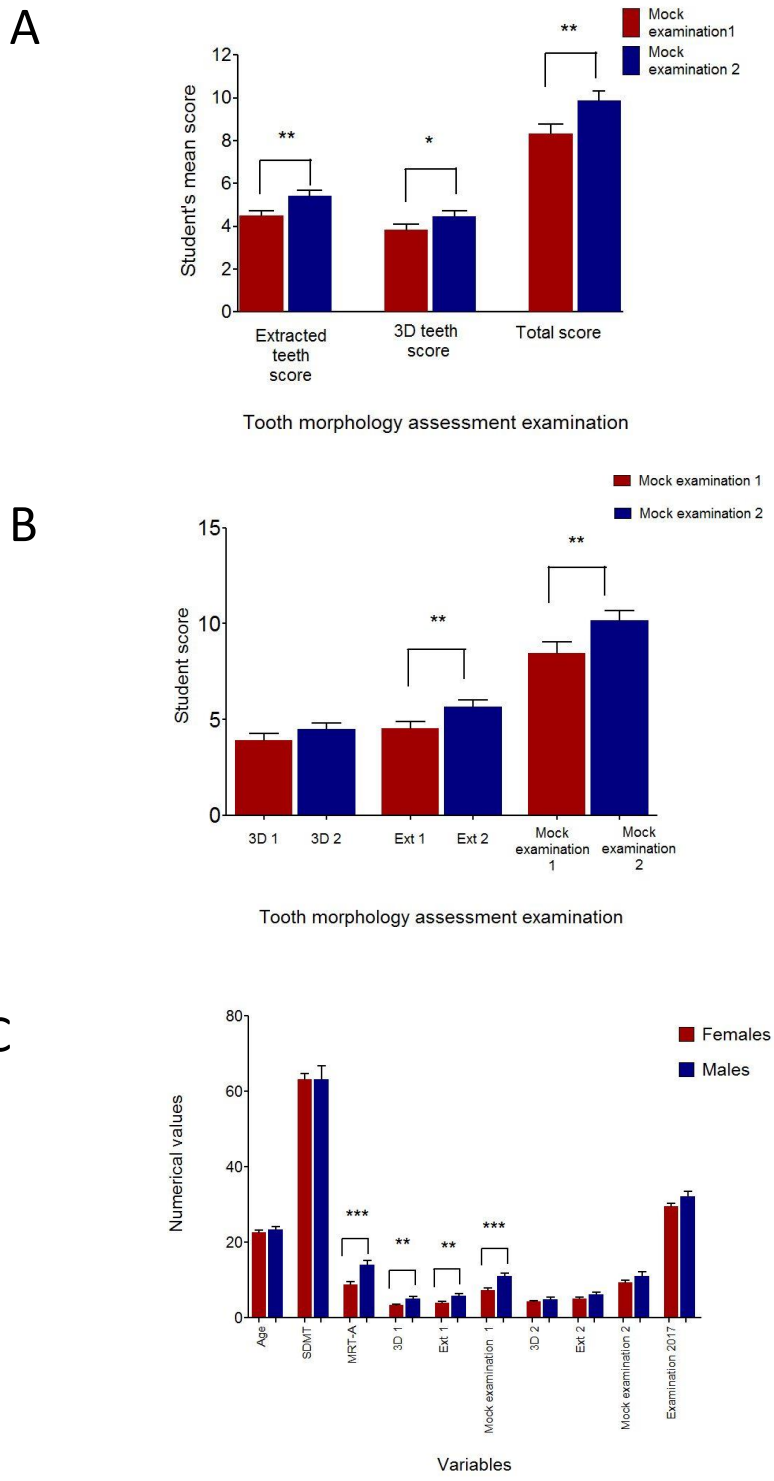

Figure 7.4: Comparison of students score in Mock examinations. (A) Comparison of students' scores of Mock examination 1 (red bars) and Mock examination 2 (blue bars). (B) Performance of group B on 3D1/2, Ext 1/2 and Mock examination 1/2. Red bar shows scores of Mock examination 1 while blue bar represents scores of Mock examination 2. (C) Comparison of gender differences between various variables. Red bars represent females whereas blue bars represent male data. TM assessment spots, Tooth morphology assessment spots; 3D teeth (1/2), digital teeth spot questions of Mock examination 1/2; Extracted teeth scores (1/2), extracted teeth spot question of Mock examination 1/2; total score, total score of Mock examination 1/2; Mock examination 1/2 , Total score of Mock examination 1/2; SDMT, Symbol Digit Modalities Test; MRT-A, Mental Rotation Test-A; Examination 2017, End of year examination 2017; * $p<0.05$, ** $p<0.005$, ***$p<0.0005$.

Pearson correlation coefficient was calculated between different data variables. Age, SDMT and MRT-A scores were correlated against all existing variables. Age was not significantly correlated to any variables. Results show a positive correlation between SDMT scores with Ext 2, r=0.290, p<0.05 and SDMT with Mock examination 2, r=0.308, p<0.05. Furthermore, a positive correlation was found between SDMT and Examination 2017 with r=0.298, p<0.05. These results show that SDMT scores are positively correlated to Ext 2, Mock examination 2 and Examination 2017 scores (Fig. 7.5A). Correlation of MRT-A scores against all the variables did not yield any statistically significant results (p>0.05) (Fig. 7.5B).

Correlation was also assessed between Mock examination 1, Mock examination 2 and Examination 2017. Mock examination 1 had a moderately positive correlation to Mock examination 2, r= 0.405, p<0.001. Moreover, there was a moderately positive correlation between Mock examination 1 with Examination 2017, r= 0.513, p=<0.001 and Mock examination 2 with Examination 2017, r=0.537, p=<0.001(Fig. 7.5C). These correlations show that student performance improved throughout the various phases of the assessment.

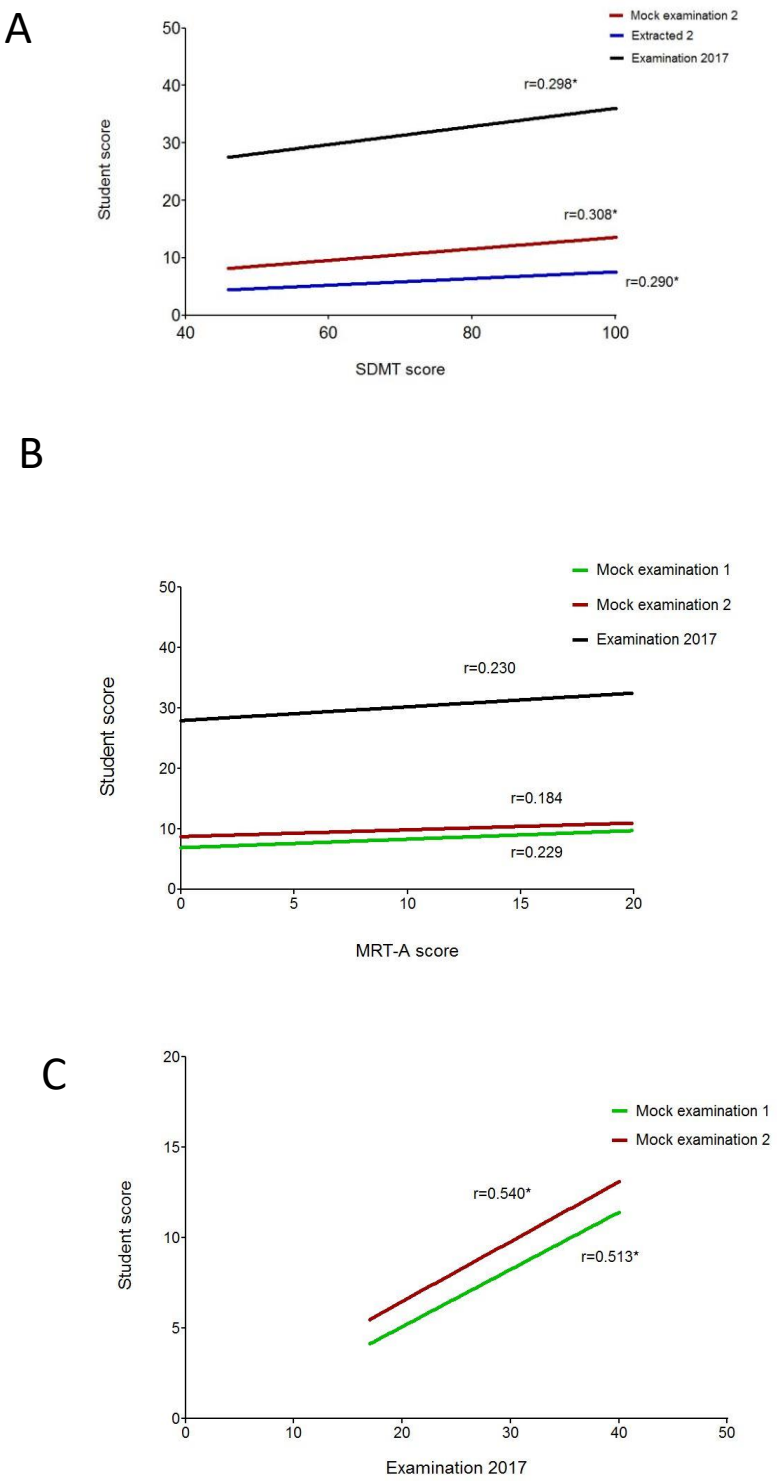

Figure 7.5: Comparison of student examination score with cognitive assessment scores. (A) Comparison of SDMT and student scores of Ext 2 (blue line), Mock examination 2 (red line) and Examination 2017 (black line). (B) Comparison of MRT-A with Mock examination 1 (green line) and Mock examination 2 (red line). And Examination 2017 (black line). (C) Comparison of Examination 2017 with Mock examination 1 (green line) and Mock examination 2 (red line). SDMT, Symbol Digit Modalities Test; MRT-A, Mental Rotation Test; Ext 2, extracted teeth spot questions of mock examination 2; Mock examination 1, total scores of spot questions of mock examination 1; Mock examination 2, total scores of spot questions of mock examination 2; Examination 2017, end of year examination 2017; *r* = correlation coefficient value, * $p<0.05$, ** $p<0.005$.

The results of examination 2017 were compared to the examination scores of student cohort of 2016. Demographics of the student cohort from both years were similar (Table 7.1). Data about the gender and age profiles of student cohort 2016 was available and hence a Pearson's correlation was performed for comparison of available data (gender and age) to the end of year examination result 2016 and yielded no significant results ($p>0.05$).

An independent t-test compared the results of the Examination 2016 and Examination 2017. For this analysis all 64 dental student examination scores from 2017 were compared to the 2016 cohort. The difference in Examination 2016 and Examination 2017 was found to be significant ($p<0.05$). This result provides evidence that student examination performance improved in 2017 as compared to results from 2016 (Fig 7.6).

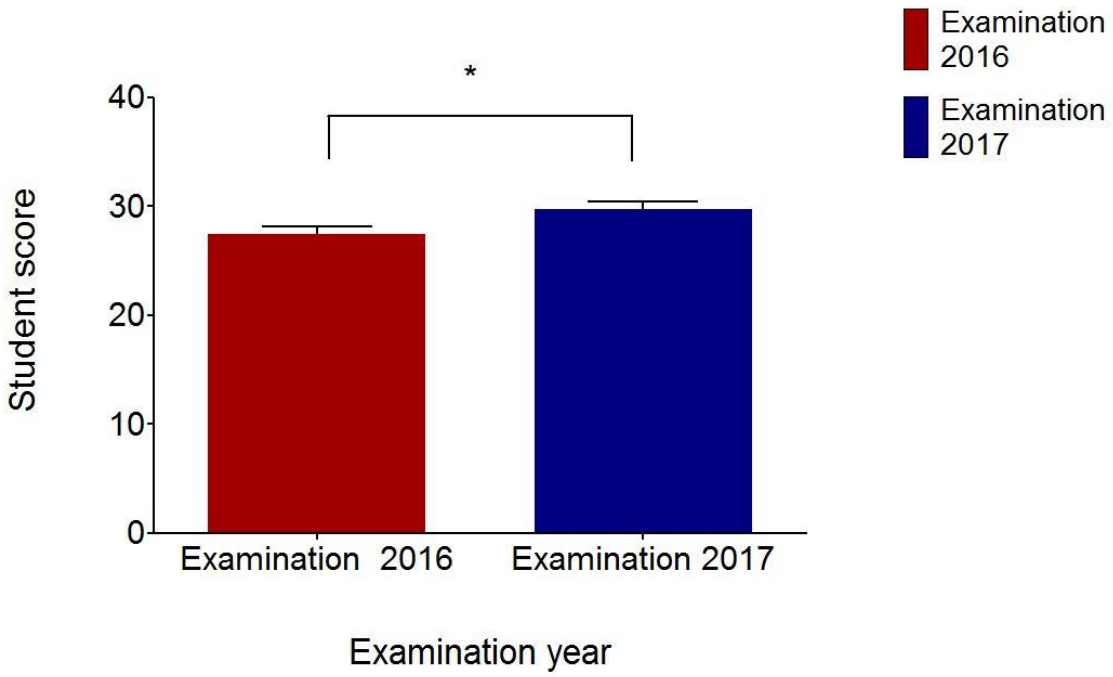

Figure 7.6: Examination results of 2016 and 2017. Comparison of student's results using an independent t-test. The red bar represents examination scores from 2016 while blue bar represents results from 2017. Examination 2016, End of year examination 2016; Examination 2017, End of year examination 2017; * $p<0.05$, ** $p<0.005$, ***$p<0.0005$.

Student's Perception of the Learning Experience Using the TMQ

After the completion of the study, students were asked to fill in the post-questionnaire (Appendix 14) which collected data pertaining to students' opinions about their tooth morphology learning experience. Students were instructed to rank their perception of the learning experience with the TMQ or extracted teeth using a five-point Likert scale (5= strongly agree, 4= agree, 3= neither disagree nor agree, 2= disagree and 1= strongly disagree). Overall the students enjoyed using the app (Mean: 3.21). Students felt the app was easy to use, easy to follow and use, and of good technical quality (Mean: 3.17, 3.75, 3.04 respectively; Table 7.2). Students also reported that the 3D aspect of the tooth was easy to manoeuvre, easy to understand and helped with learning tooth morphology (Mean: 3.33, 3.62 and 3.06 respectively; Table 7.2). Students reported learning more from manipulating extracted teeth and preferred to hold and visualize the extracted teeth (Mean: 4.35 and 4.62 respectively). Students favoured the feedback provided in the app as being helpful (3.71), improved understanding of tooth morphology (3.67) and helped improve the score for the next quiz (3.38). The students were also supportive of quizzes being helpful for self-assessment and understanding of a topic (mean: 4.02). Students would like to use the app again (3.23) and prefer to have it available online and accessible at all times (3.96) (Table 7.2).

Table 7.2: Student's perception on their learning experience.

Question	n	Mean	±SEM
The tooth morphology app was easy to use	53	3.17	0.13
The image quality was poor	53	2.77	0.15
The 3D aspect did not resemble the extracted teeth	53	2.73	0.14
The 3D aspect of the application was easy to understand	53	3.62	0.13
There was distortion in the 3D image	53	2.50	0.13
The 3D tooth was easy to orient (Upper/lower, right/left)	53	2.67	0.15
The app was of good technical quality	53	3.04	0.14
I was able to use the app without assistance	53	4.12	0.14
The app showed the key identifying features of the teeth clearly	53	3.23	0.13
The cusps and grooves on the occlusal surface of the crown were clearly visible	53	2.81	0.15
The roots of the teeth were not clearly visible	53	2.27	0.15
The visible features helped me identify the correct teeth	53	3.33	0.12
It was easy to orientate the tooth	53	2.65	0.15
The app improved my confidence in identifying the teeth	53	2.65	0.13
The 3D aspect of the application helped with learning tooth morphology	53	3.06	0.14
The app is a not a useful learning resource	53	2.75	0.15
The app was easy to understand and follow	53	3.75	0.12
The app provided a better learning experience than extracted tooth	53	1.83	0.11
I learned more from manipulating extracted teeth than from the app	53	4.35	0.14
The feedback at the end was very helpful	53	3.71	0.15
The feedback improved my understanding of the tooth morphology	53	3.67	0.14
The feedback provided at the end helped improve my score for my next quiz	53	3.38	0.13
I prefer to hold/visualize the extracted teeth while learning tooth morphology	53	4.62	0.09
I prefer not to look at 3D images of the teeth	53	3.13	0.16
I found this app very confusing as compared to the extracted teeth	53	2.77	0.15
I enjoyed using this application	53	3.21	0.12
I don't enjoy self-test quizzes	53	2.1	0.11
I would like to use the quiz again	53	3.23	0.12
I like self-assessment and use quizzes to help me study and test myself	53	3.71	0.13
Quizzes are helpful for self-assessment and understanding of the topic	53	4.02	0.10
I would like to have this app on my laptop	53	3.67	0.15
This app should be available online and accessible at all times	53	3.96	0.13

The post-questionnaire also contained an open-ended question to allow students to provide feedback and suggestions. Some of the feedback provided is given below:

- *The app was helpful and easy to use.*
- *The feedback at the end was helpful.*
- *There was no pressure from others to finish using the app so found it helpful to study.*

The following are some of the suggestions and recommendations for improvements:

- *I couldn't rotate the tooth.*
- *I couldn't change the answers.*
- *I would like to have it at home.*
- *I prefer feedback in bullet points.*
- *Feedback-if wrong answer then 3D tooth could be viewed to study.*
- *Instead of 3D quiz, only 3D teeth to study.*
- *Prefer to have quiz of one tooth only and have answer straight after.*
- *The time wasn't sufficient for the practical.*
- *I would have preferred to study with extracted teeth and then study with the app.*

Discussion

This study introduces the development and assessment of a 3D quiz app 'TMQ' for studying tooth morphology. To avoid crossover between the two groups which could be a potential issue, strict attendance was taken in both venues (lab and tutorial room).

The study cohort were second year dental students and first year dental hygiene students and data analysis shows that these students prefer to use smartphone and laptop for accessing the internet whereas desktop is least preferred. These findings are in line with a recent study by Khatoon *et al*., (Khatoon *et al*., 2014). Although smartphones were primarily used for accessing the internet (98.31%), laptops are still preferred for educational purposes (88.14%). This indicates that while the students might predominantly use smartphones to access the internet possibly because of the size and ease of access, laptops are still the preferred study device used to access and study educational material probably due to ease of typing notes, larger screen for reading and available printing options (Khatoon *et al*., 2014).

Responses from the pre-questionnaire show that the majority of students were confident manoeuvring 3D images on laptops and smartphones. Usage of the app, app scores and scores generated from digital spot questions for mock examination also demonstrate that students found 3D tooth easy to manoeuvre, study and recognize. Furthermore, students also reported that the tooth morphology app was easy to use and 3D features of crown and root could be easily viewed and studied.

In this study design, the module allowed participants to take a more active role in their learning. Both practical sessions (extracted teeth and TMQ) were self-directed with a lecturer available to answer queries. The TMQ allowed students to adjust the viewing of digital tooth, including the ability to zoom, rotate the tooth around a vertical

and horizontal axis. Previous studies have also reported that active learning promotes better retention of knowledge (Allen *et al*., 2015).

TMQ was developed as a self-directed teaching tool to teach tooth morphology. Feedback obtained shows that majority of the students described the app as simple and easy to use and did not require help while using the app. At the start of the app a short animation provided demonstrates the features of the tool. The app was developed as a standalone application which does not require any plugins and is very easy to install in a computer. The app was installed in the computers and laptops in the lab and students reported no technical difficulties while using the app. The data suggests that the TMQ developed was easy to use and could be easily provided to the students for personal use on laptops.

Results of the paired t-test show a significant improvement in student scores from Mock examination 1, Mock examination 2 and Examination 2017. This demonstrates that student scores improved with each consecutive examination. Furthermore, student scores improved regardless of the teaching modalities accessed first, proving that the students who studied with TMQ first performed just as well as the students in the extracted teeth group. These results substantiate the effectiveness of TMQ in learning tooth morphology and also reiterates that e-learning or CAL should supplement the teaching of tooth morphology (Bogacki *et al*., 2004).

There is strong evidence linking MRT-A scores to improved anatomy learning (Guillot *et al*., 2007; Hoyek *et al*., 2009). Our cohort of male dental students' had higher MRT-A scores than females, similar to other studies (Nazareth *et al*., 2013) and also performed better in Mock examination 1 (both 3D teeth and extracted teeth scores). We can conclude that although our study cohort had fewer males as compared to females,

because group A studied tooth morphology initially with TMQ without access to extracted teeth, they had to use more visuospatial awareness (MRT-A scores) and understanding for tooth morphology. However once this group was exposed to the extracted teeth (crossover) the effect was diluted and MRT-A was not significant when compared to students' scores of Mock examination 2 and Examination 2017.

The SDMT scores measure the cognition ability of individuals. Students in group B studied with extracted teeth initially and thus they were able to understand tooth morphology by kinaesthetic learning. Once these students accessed the TMQ their understanding was further improved and hence they had statistically significant scores in Ext 2 and Mock examination 2. Furthermore, SDMT scores were also positively correlated to end of year 2017 results.

The study proves that innovative technologies can present teaching material in a novel and efficient manner and supplement traditional teaching. These methods are student friendly and lead to a better learning experience and enhanced teaching outcomes. These strategies are as effective as traditional teaching methods while allowing the students to study at their own pace and with or without repetition. It also reduces workload on the faculty while providing them with opportunity for increased interaction with the students. These outcomes are in line with similar studies (Rosenberg *et al*., 2003; Bogacki *et al*., 2004; Nance *et al*., 2009; de Azevedo Rde *et al*., 2015). Furthermore, blended teaching approaches should be utilized and innovative teaching methods should supplement, not replace, the traditional teaching lectures and face to face teaching (El Tantawi *et al*., 2013).

Comparing results of both groups, it was found that group B performed better in extracted teeth questions for Mock examination 2 and overall Mock examination 2. We

can thus speculate that their study design led to enhanced learning. Students should be provided access to extracted teeth first before exposing them to TMQ. This will reinforce their learning and lead to better understanding. Students themselves reported preference for studying with the extracted teeth first and then using the app. Students also reported in favour of using quizzes for self-examination and find them helpful (Jackson *et al*., 2011). Moreover, combining play and learning for the millennium generation leads to better student satisfaction (El Tantawi *et al*., 2013).

Future directions include testing of the interactive quiz with a larger cohort of dental students. Additionally, this study can be expanded to include scanning of pathological tooth anomalies including developmental anomalies. We also propose that the quiz should be provided to students in their clinical years to introduce vertical integration of tooth morphology in the dental curriculum (Jackson *et al*., 2011; de Azevedo Rde *et al*., 2015).

Conclusion

The aim of the study was to develop a tooth morphology quiz app ‘TMQ’ to demonstrate the 3D structure of individual teeth to assist in student learning. Furthermore, game-based learning is introduced in the form of a quiz. Data herein also indicates that TMQ was statistically equivalent to extracted teeth in teaching tooth morphology and can be used as a supplemental tool to teach tooth morphology in the absence of extracted teeth. The app offers unlimited practise time for students, reduced student/ facilitator interaction for teaching and offers student learning in both basic and clinical years.

CHAPTER 8

General Discussion

8.1 Overview

Anatomy education is undergoing significant transformations and there is a need to assess and improve anatomy teaching strategies to take advantage of modern technological advancements. This is vital to ensure that the current generation of students are taught to the highest standards and are better equipped to deal with contemporary challenges. An exhaustive review of the literature had identified gaps in teaching methods (Table 1.2), which led to the development of the work presented in this thesis. The research projects introduced in this thesis bridge the limitations in current research (Table 8.1).

The second chapter describes the development and assessment of an animation based on an overview of the cranial nerves. Cranial nerves are a very important topic for dental students, but their anatomical route and functions are difficult to remember. The animation was developed as a teaching tool to enhance learning, particularly as a self-directed aid for visualization of difficult concepts. Results showed an improvement in the students' knowledge of cranial nerves. Qualitative feedback obtained indicates that the animation was easy to understand, facilitated learning and was a useful tool in understanding cranial nerves.

The third chapter introduces the use of a soft-preserved cadaver to teach anatomy of the oral cavity to dental students. Students compared and rated the aesthetic and haptic properties of various features of the oral cavity. Students reported that most of the anatomical features of the oral cavity were easy to locate on their partners and TEC, with features on TEC considered visually realistic. Another element of this research project was the assessment of TEC to teach local anaesthetic techniques. Visual inspection of the tissues at the end of the study revealed that the majority of

needle marks had reduced in size suggesting that the gingival tissue had preserved some elasticity after fixation.

The fourth chapter surveyed the staff currently engaged in teaching tooth morphology in dental schools of UK and Ireland. A list of educators was compiled by accessing the schools' website or by personal correspondence. A total of 17/18 institutions responded to the survey. Results from the survey show that the majority of staff involved in teaching tooth morphology are dentists with master's and Ph.D. degrees. Tooth morphology is taught and examined using extracted and plastic teeth, CAL and online tooth atlases. Traditional teaching methods are being supplemented with innovative tools to achieve optimal results.

The fifth chapter involved the development and assessment of a tooth morphology quiz app for dental students. Extracted teeth routinely used to teach tooth morphology were scanned, stitched and incorporated into a 3D quiz. Randomized crossover study design was selected with students accessing extracted teeth and a Tooth Morphology Quiz (TMQ) app to study tooth anatomy. Mock examinations were performed before the cross-over and at the end of the study to gather data regarding student knowledge. Results show that there was no difference in student performance based on the teaching modality accessed. However, students who first used extracted teeth to study had improved performance in the latter examinations providing evidence that their study design was better. Students themselves preferred 'to study with extracted teeth first and then use the app'.

Table 8.1: Current projects bridging the research gaps.

Research area	What has been done	What is required	What the research achieved in this thesis	Future recommendations
Anatomy animations for dental students.	Animations of the TMJ and dental mandibular nerve block were developed (Guttmann, 2000).	Animations are required to aid the visualization of difficult anatomical concepts.	-A cranial nerve animation was created and assessed for improvements in student knowledge. -Qualitative feedback obtained about students' perception on use of the animation.	-More research is required to assess the educational effectiveness of animations using a control group of students. - Long-term retention of knowledge should also be assessed.
Use of soft-preserved cadavers in teaching pre-clinical dental skills.	Tooth extraction was taught to dental students (Hansen *et al*., 2016).	Recommended model is required for teaching local anaesthesia and other clinical skills.	-First year dental students performed oral cavity examination in TEC/partners. -TEC assessed for teaching local anaesthesia.	-Research is needed to ascertain the use of soft preserved cadavers for teaching various clinical procedures.
Staff involved in teaching dental students.	Survey on staff teaching oral histology and embryology in North American dental schools (Burk *et al*., 2013).	Assess staff teaching tooth morphology to dental students.	-Survey assessed the staff involved in teaching tooth morphology in UK and Ireland. -The teaching aids employed for tooth morphology teaching were also analysed.	-Survey to assess tooth morphology teaching in dental schools in Europe and the US. -Use of extracted teeth for teaching tooth morphology and its preference by educators and students should be further explored.
Apps for tooth morphology teaching.	'Tooth morphology'- computer assisted learning programme (Bogacki *et al*., 2004). '3D Interactive Tooth Altas' Version 4.0 (Wright *et al*., 2009). 'MorphoDent'- Web-based learning programme in dental morphology (Mitov., 2010).	An interactive 3D app with quiz and feedback to aid in studying tooth morphology.	-Extracted teeth used for teaching were scanned for TMQ. -TMQ was developed and assessed.	-Further improvement in the TMQ is required. -TMQ use and efficacy can be assessed after providing it to the students on their personal laptops.

Apps, Applications; TEC, Thiel embalmed cadaver; TMJ, Temporormandibular joint; TMQ, Tooth morphology quiz; UK, United Kingdom; US, United States; 3D, Three dimensional.

8.2 Traditional Teaching Versus Innovative Teaching Methods

A review of the literature shows that innovative pedagogies are increasingly being employed to teach dental students. These technologies are primarily supplementing the traditional teaching methods (Bogacki *et al*., 2004; Maggio *et al*., 2012). Our results affirm existing literature that use of innovative teaching tools leads to improved student results when compared to traditional teaching methods (Bogacki *et al*., 2004).

Traditional methods employed to teach cranial nerves in practical sessions involve using prosections, models and CAL. A review of the available tools currently employed to teach cranial nerves showed no suitable teaching aids to provide a quick overview of the cranial nerves. Furthermore, the available teaching aids list the cranial nerves in their numerical order, which promotes learning in rote. While this may be pertinent to some learning styles, other learners may prefer to learn with a more applicable setting such as a simple, everyday scenario. The cranial nerve animation developed as part of this research will help students use the scenario to study the cranial nerves, apply it in their everyday life and remember the functions of cranial nerves in the long-term.

Anatomy needs to be taught with its associated clinical significance. Improved student learning and performance is reported when anatomy and clinical examination are taught concurrently (Rafai *et al*., 2016). Traditional methods used to teach the oral cavity features in practical sessions include the use of images, prosections and CAL. Formalin embalmed cadavers are hard-fixed and have reduced mobility at the temporomandibular joint which restricts access to the oral cavity. Furthermore, the features of the oral cavity that are visible are not very realistic. TEC were used to

introduce first-year dental students to oral cavity examination. Dental students examined the oral cavity for the first time as part of their anatomy practical session.

Tooth morphology is usually taught in the second-year of the dental curriculum. Extracted teeth are the preferred teaching tool (Cantín *et al*., 2015) but the acquisition of unworn, non-carious human teeth, which show sufficient morphological features of the teeth, is difficult. Due to aforementioned problems there is a lack of a sufficient number of extracted teeth for teaching tooth anatomy. While high quality plastic teeth are readily available and provide an alternative method for teaching students, they do not show any variations in morphology or size and hence are not a realistic alternative. Moreover, students often complain of not having enough time for learning tooth morphology during practical sessions, using extracted and plastic teeth. Keeping these factors in mind, a set of 32 permanent teeth were scanned and imported in a 3D quiz app (TMQ). The quiz allowed students to study the 3D projected image of the teeth and identify the anatomical features particular to each tooth. The quiz also required students to drag and place the teeth in the proper location on a grid of the oral cavity based on the FDI notation system. Hence the teaching was two-fold with students learning to identify the teeth and also use the notation system. Additionally, feedback was provided at the end of the quiz for student learning.

8.3 Student Engagement

The current cohorts of students are referred to as the ‘Net generation’ (Sandars and Morrison, 2007) and have easy access to the internet and the latest gadgets (Khatoon *et al*., 2014). There is a requirement to teach students in innovative ways. To facilitate this, we aimed to enhance the dental students learning experience in UCC by introducing and assessing an animation based on the overview of the cranial nerves and

a 3D interactive tooth morphology quiz. We also introduced oral cavity examination by utilizing soft-preserved cadavers, while also assessing its application for teaching local anaesthesia to dental students.

Most of the current teaching methods show the cranial nerves in numerical order and introduce students to learning in rote format (Rowland and Joy, 2015). Our animation was unique in that it introduced a short animation consisting of an overview of cranial nerves with a scenario based on a simple, everyday task of eating an apple. The cranial nerves in our animation were not in their numerical order, but rather their order was dictated by the scenario. It is anticipated that students will use this simple scenario to learn the topic of cranial nerves, apply it to their everyday life and remember the anatomic topic easily. Data was collected for two cohorts of dental students. One cohort had access to the animation for two weeks whereas the other cohort had a single viewing of the animation only. Results show that student knowledge improved in most questions. Students' feedback obtained at the end of the study shows that animation improved the conceptual understanding of the cranial nerves. Students described and said that 'animations stimulate their visual learning centres and provide helpful material to visualize, understand and appreciate different topics'. Students also described 'how animations help in acquiring a 3D understanding and are easier to learn than from a book or lecture slide while also consolidating the topic'. Open-ended feedback was collected regarding the students' opinion on how to improve the cranial nerve animation. Students reported that the speed of the animation was too fast to follow and would benefit from slowing with more audio description. Students also expressed interest in watching more animations on anatomical topics.

Oral cavity examination and local anaesthesia application are both basic skills introduced in the clinical years of the dental curriculum. Students usually perform these

clinical activities for the first time on either a student/partner's oral cavity or on their 'first patient'. TEC was used to teach oral cavity examination to the dental students. To the best of our knowledge this was the first time TEC or soft-preserved cadavers were used to teach anatomy in UCC or even Ireland. Students rated the aesthetic and haptic properties of the anatomical features and results show that the students' perceive TEC as closely resembling living anatomy. Furthermore, student's appreciated the link between theoretical knowledge of anatomy and its practical application. The dental tissue was also assessed for repeated local anaesthesia injection and their teaching capacity. Based on the results we can speculate that soft-preserved cadavers offer a realistic model for teaching anatomy to dental students.

Dental students need to learn tooth anatomy and morphology in great detail so they can correctly identify the tooth and also restore them. Traditional methods of teaching tooth morphology in practical sessions include studying extracted teeth, plastic teeth, drawing teeth and carving teeth. The educational benefits of each of these methods are widely recognized (Bogacki *et al*., 2004; Mitov *et al*., 2010; Obrez *et al*., 2011). Moreover, introducing quizzes has been linked to enhanced student learning (Lee *et al*., 2012). In the current study an innovative 3D TMQ app was developed. Students were provided access to the app in practical session as a self-directed teaching tool to learn tooth morphology and found the app easy to use, helpful and aided in learning tooth morphology. Students also reported that TMQ showed the morphological features of the crown and root clearly while feedback at the end of the quiz was beneficial. Furthermore, innovative aids provide students with an opportunity to conduct self-directed learning at their own pace and in their own time (MacPherson and Brueckner, 2003; Bogacki *et al*., 2004). TMQ was an innovative teaching tool that introduced a learning element in the form of a quiz and additionally feedback was also provided at

the end. Both, introduction of quiz and feedback in CAL are highly valued by dental students (MacPherson and Brueckner, 2003).

8.4 Educator Perspective

An integrated dental curriculum has been proposed as best practice for teaching dental students (Field and Jeffcoat, 1995). An integrated curriculum will ensure vertical and horizontal integration of anatomy into the dental curriculum (Plasschaert *et al*., 2006; Manogue *et al*., 2011).

The results from an online survey assessing tooth morphology teaching in the UK and Ireland show that the majority of educators employ the use of PowerPoint™ during lectures, while blended-learning approaches are applied in practical sessions by using extracted teeth, plastic teeth, wax carving and drawing teeth. Different e-learning elements are offered in the majority of the institutions and while its applications vary they include placing content on online learning platforms (*Blackboard™ / Moodle™)*, CAL or recommending websites to students. Respondents also reported that tooth morphology needs to be taught in conjunction with its clinical application.

The results of TMQ, when compared to traditional teaching methods, show that it is equally effective as a teaching tool. This does not imply that innovative teaching aids can replace academics. It rather suggests that when these innovative aids are employed for teaching students, it allows the faculty an opportunity to spend more time interacting with the students, answer queries and help them understand the clinical relevance of the anatomy (Rosenberg *et al*., 2003; Bogacki *et al*., 2004). It will also provide an opportunity to obtain invaluable feedback from the students. Lecture and practical sessions can become more interactive with staff dedicating more time to support and help students who are challenged by specific topics.

8.5 Benefits of Innovative Teaching

Innovative teaching aids developed as part of this research project show an increase in students' knowledge (quantitative results) and provided a stimulating learning (qualitative feedback) experience for the students. These are novel teaching pedagogies, in line with modern technological advancements. The use of innovative teaching aids along with traditional teaching methods will ensure that teaching is applicable to all different learning styles within the student cohort. As mentioned earlier, the use of innovative teaching aids can be tailored to provide self-directed learning and hence provide the staff with an opportunity to interact and engage with students.

Quantitative results from the animation study demonstrate an increase in knowledge of the cranial nerves following access to a cranial nerve animation. An example of a statistically significant question was the question pertaining to nerves supplying the muscles of the eye. Data collected before showing the animation revealed that there were no correct answers. However, when the same question was asked after viewing the animation the number of correct responses was ten. It is important to note that three nerves supply the muscles of the eye and scripts with all three answers were only awarded a correct answer. This question yielded a statistically significant result. Qualitative student feedback shows that animations facilitate understanding and learning and help visualize difficult concepts. Students indicated that they would prefer more animation in topics of anatomy. Both results favour the use of animation for teaching difficult concepts.

The Thiel study introduced first-year dental students to their first oral cavity examination on a TEC. Results from the study show that the students were very

enthusiastic during the practical and reported that most features of the oral cavity of TEC were quite realistic. TEC were also assessed for teaching local anaesthesia. We conclude that TEC provides a useful tool for teaching anatomy to dental students.

Tooth morphology teaching for dental students was supplemented with the use of TMQ. The results of students' performance on mock examinations during and after the crossover study design were collected. Additionally, the end of year examination results were compared to the mock examinations and also to the previous year's examination results. Statistical analysis shows that the innovative teaching tool was effective in teaching tooth morphology with no difference in students score, regardless of the teaching modality accessed. Furthermore, end of year examination yielded a better score than the previous year's result. These results prove that the innovative teaching tool not only supplement traditional teaching methods but is also equally effective. Students found TMQ effective and useful for learning tooth morphology. However, our dental student cohort indicated a preference to study initially with extracted teeth, with subsequent self-testing using TMQ or TMQ as a supplemental teaching tool at home. The purpose of the TMQ study was to assess the effectiveness of the app for teaching tooth morphology as a self-directed teaching aid. The study was conducted in the anatomy laboratory, UCC. The app was easy to install, required no plugins and students did not report encountering any technical issues. Thus, data suggests that the app can be provided to students on their personal laptops as a self-directed study aid.

8.6 Future of Technology Enhanced Learning

Innovative teaching tools are constantly being developed. However, each new teaching aid should be assessed carefully before implementation. Two very important

factors to consider would be the student or user's and educator or facilitator's opinions. Innovative tools need to be developed keeping the user in mind and should be user friendly, easy to access and not require plug-ins. Educators should be provided with training workshops to introduce them to the innovative tools (McAndrew and Johnston, 2012).

With an exponential increase in the scientific knowledge in a wide range of disciplines, there has been a concomitant increase in the need to link these disciplinary fields in order to devise innovative teaching tools to effectively address critical limitations in current teaching designs and facilitate student learning. Hence, there has been a steadily increasing trend within the scientific community; educators, instructional designers and developers to work collaboratively with each other and combine their multi-disciplinary skills and perspectives to develop new and innovative teaching methods for the millennial generation. Such an approach offers a more holistic perspective to the teaching pedagogy and allows the tool to address the limitations from a multi-dimensional angle.

8.7 Challenges to Overcome

A recent study by Arnett *et al.*, (2013) presented evidence that most educators do not use social media-assisted teaching. Some of the reasons stated were mainly related to time, privacy concerns, lack of expertise in implementation of using social media for teaching and uncertainty about the usefulness of social media for teaching (Arnett *et al*., 2013). Similarly, another study reported insufficient resources, lack of faculty and training time as some of the issues creating barriers for integrated dental curriculum (Elangovan *et al*., 2016). Information sessions should be organized to introduce faculty to social media and innovative tools currently available, with the

practical applications and academic uses emphasised. Faculty should be encouraged to participate in such sessions (Rowland and Joy, 2015). Furthermore, as mentioned earlier, innovative pedagogies should be assessed before implementation. A pilot study should gather data about effectiveness of the teaching tool and once recommended for implementation, staff should endeavour to use it.

One of the challenges encountered as part of this project was performing research in innovative, technology-based teaching areas without formal knowledge about software programming and developing applications. Detailed knowledge of anatomy and tooth morphology were the domains of the primary author. Limited knowledge of computer science and programming created the basis for collaborative work with the members of the computer science department in UCC (creating the cranial nerve animation as mentioned in chapter 2 and 3 and also development of the tooth morphology application as stated in chapters 6 and 7) and also staff of the restorative department, Cork University Dental School and Hospital CUDSH (where digital scanning the teeth was performed as stated in chapters 6 and 7). This collaboration was vital and productive for the research and reiterates that anatomist should participate in collaborative multidisciplinary research. This will enhance and enrich the teaching within an institution while also encouraging interaction and collaboration between departments for future research avenues.

8.8 Conclusion and Future Recommendations for Dental Curriculum

Traditional methods of teaching anatomy to dental students should be supplemented with innovative teaching tools. Using innovative teaching methods have demonstrated an increase in student satisfaction and interest in the taught course (Mitov *et al*., 2010; Vuchkova *et al*., 2012), improved confidence for clinical sessions (Hanson

et al., 2016) and improved examination scores (Obrez *et al*., 2011). Moreover, the current cohort of students are called the 'Net generation' (Sandars and Morrison, 2007) with the majority of students using smartphones and laptops for educational purposes (Khatoon *et al*., 2014). Hence, the faculty needs to introduce innovative educational tools to supplement the traditional teaching methods.

There is a need for vertical and horizontal integration of anatomy into the dental curriculum. PBL, skill based learning and radiology should all be introduced concurrently while teaching anatomy to allow students to obtain a better and more comprehensive understanding. This will ensure an integrated dental curriculum (Rowland and Joy, 2015; Elangovan *et al*., 2016).

There is no single best method to teach anatomy. A blended learning model where traditional teaching methods are augmented with several innovative teaching modalities including CAL, PBL, case-based learning and inquiry-based learning is considered appropriate. Additionally, blended learning model ensures application to all the different learning styles.

The different chapters of this research were designed to develop and assess innovative aids for teaching anatomy and tooth morphology to dental students. The assessment of the teaching strategies shows an increase in knowledge for the students while also providing them with an innovative and better learning experience.

APPENDICES

Appendix 1

Storyboard for the cranial nerve animation

Time	Focus	Text	Illustration	Snapshot
0-49 sec	General	Hi Everyone. My name is Jimmy. Today I will be talking to you about the 12 pairs of cranial nerves in the head and neck region of the human body. These nerves are part of the peripheral nervous system and all nerves originate from the brain and exit by passing through foraminae and fissures in the cranial cavity.We use these nerves subconsciously in nearly every action or movement that we do. Some nerves have senosry function such as the olfactory, the optic and the vestibulocochlear nerves. Some nerves have motor functions such as the occulomotor, the trochlear,the abducent,the accessory and the hypoglossal nerves and some nerves are in fact mixed that is have both sensory and motor innervation like the trigeminal, the facial, the glossopharyngeal and the vagus nerve. ' While these nerves have several actions, in the following animation we will focus only on the function of the nerves related to this scenario'.	Diagram of the brain showing the nerves firing. All the sensory nerves will fire first (red).The word SENSORY will appear on the screen. Next the motor nerves will fire (blue colour) and the word MOTOR will appear.	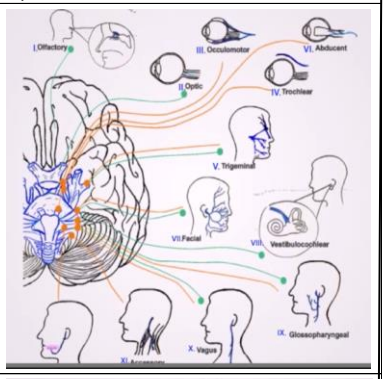
50-59 sec	2 nerve	*Stomach growling(sound bite for this)! I'm hungry!Hmm apple* . The second cranial nerve (optic) carries the sense of vision from retina to the brain.	The optic nerve fires from retina to the brain	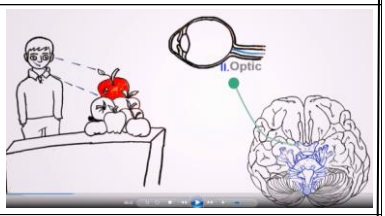
1-1.16sec	3,4,6 nerve	*Hmmm, Now which apple should I have* . My various eye movements are a combination of these nerves working together. These nerves run from the brainstem to the muscles of the eye. The occulomotor,trochlear and abducent nerves are responsible for the movement of the eye.	The 3 nerves fire from eye to the brain	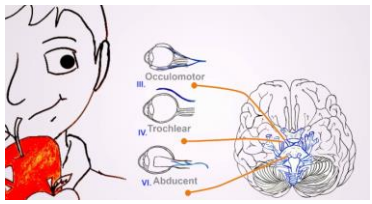
1.17-1.27 sec	7 nerve	*Ah the perfect red apple.* The seventh cranial nerve (facial) arises in the brainstem and innervates the muscles of facial expression.	The nerve fires from the brain to face and in opposite direction.	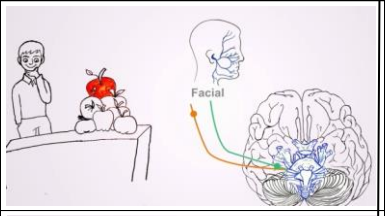
1.28-1.40 sec	8 nerve	*Now to reach for the apple* ..The eighth cranial nerve (vestibulocochlear) carries sensation of hearing and balance from the inner ear to the brainstem (music playing)	Nerve fires from the ear to the brain.	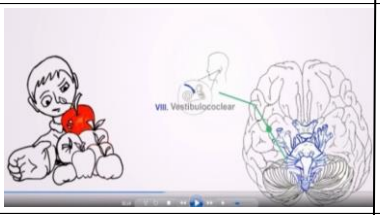
1.41-1.50 sec	1 nerve	The first cranial nerve (olfactory) carries the sensation of smell from the nose to Central nervous system (CNS).	Nerve fires from the nasal mucosa to the brain.	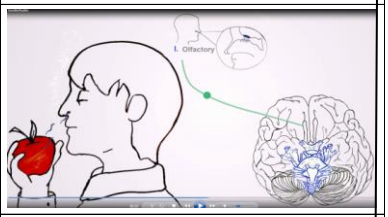
1.51-2.05 sec	5,7,9, 12 nerves	Oral cavity innervation and actions like chewing and mastication involve the primary nerves which are trigeminal,facial,glossopharyngeal and hypoglossal nerves. However these nerves do not function on their own but work with each other just like a team.	Group of nerves mentioned that are responsible for mastication.	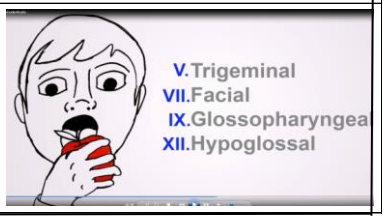

2.06-2.20 sec	5,7 nerves	Opening the mouth to take a bite and then closing it.This is carried out by the facial and the trigeminal nerve working together. These nerves supply the muscles of facial expression and the muscles of mastication and help with this co-ordinated movement.	Triogeminal and facial nerves fire in both directions as mixed nerves.	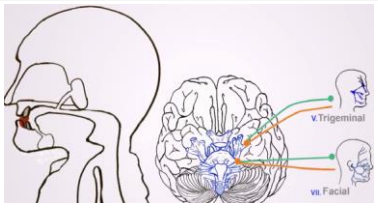
2.21-2.30 sec	7,9 nerve	As soon as the food enters the mouth, taste sensation is carried by both facial nerve (anterior 2/3 of tongue) and glossopharyngeal (posterior 1/3 of tongue) nerve. Sound bite yum yum.	Facial and glossopharngeal fie in both directions as both mixed nerves.	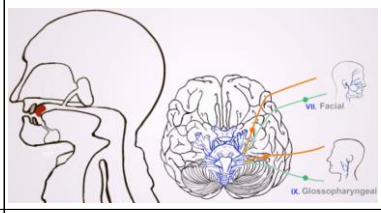
2.31-2.38 sec	7,9 nerve	The glossopharyngeal and facial nerves are also responsible for the flow of saliva from the parotid, submandibular and sublingual glands.	Facial and glossopharngeal fie in both directions as both mixed nerves.	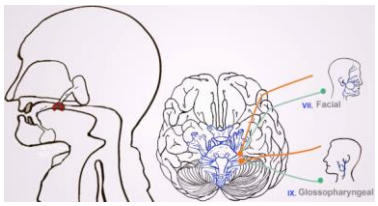
2.39-2.56 sec	5,7 nerves	Sound bite for loud chewing. The trigeminal nerve arises from the pons and innervates the muscles of mastication to helps in chewing the food. It also carries sensory innervation from the face and oral cavity. While chewing is primarily the role of the muscles of mastication, some accessory muscles like buccinator (supplied by facial nerve) helps keep the food in the mouth and in between the teeth.	Trigeminal nerve fires from the muscles to brain and in opposite direction for sensory.	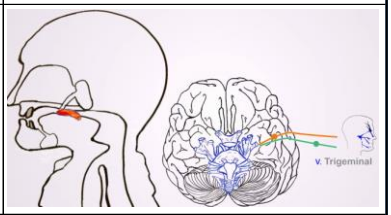
2.57-3.02 sec	12 nerve	The twelfth cranial nerve the hypoglossal nerve arises from the brainstem and supplies the muscles of the tongue.	Hypoglossal nerve fires from tongue to the brain.	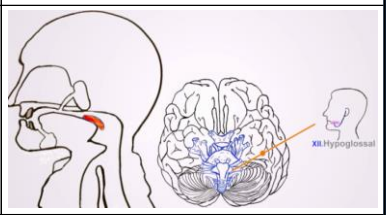
3.03-3.11 sec	9,10 nerves	Swallowing is carried out by the pharynx and oesophagus which are innervated by the lossophayngeal and vagus nerves.	Glossopharyngeal and vagus nerves fire in both directions and both mixed nerves,	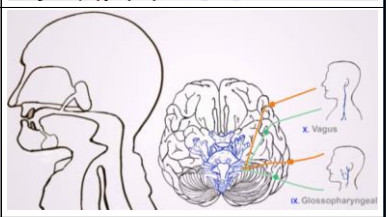
3.12-3.23 sec	11 nerve	Alright bye for now. Oops before I forget, the eleventh cranial nerve arises from the brainstem and supplies the sternocleidomastoid and trapezius muscles.	Accessory nerve fires from the trapezius and sternocleidomastoid to the brain,	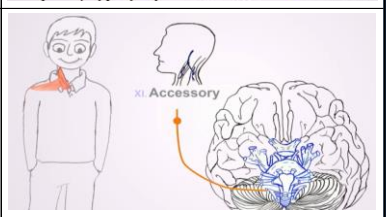
3.24-3.58 sec	All 12 cranial nerves	To sum things up, the 12 cranial nerves are really important in our daily life. They don't work independently, but rather work in conjunction with each other to bring about the various actions, as seen in this animation. These nerves work as a group to bring about coordinated actions and movements like a symphony of sound and music. I hope you've enjoyed our journey through the cranial nerves. See you next time.	Diagram of the brain showing the nerves firing. All the sensory nerves will fire first (red). The word SENSORY will fade in and out on the right of the screen. Next the motor nerves will fire (blue colour) and the work MOTOR will fade in and out.	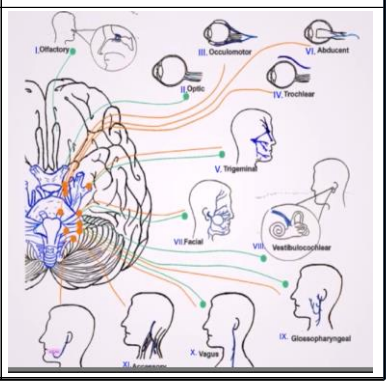

Appendix 2

Pre-animation questionnaire

(SurveyMonkey)

ASSESSMENT OF CRANIAL NERVE KNOWLEDGE

PERSONAL INFORMATION

1. Please state your student number.

2. Please state your gender.

- ○ Male
- ○ Female

3. Please state your age.

4. Please state your country of origin.

5. Education: What is the highest degree or level of school you have completed? Please tick any box which applies.

- ☐ Secondary level qualification [e.g. leaving certificate, A-Levels, baccalaureat]
- ☐ 1 or more years of third level education, no degree
- ☐ Bachelor's degree
- ☐ Master's degree
- ☐ Professional degree
- ☐ Doctorates [e.g. PhD, D.Phil]

Other (please specify)

6. If you have already completed a university degree [e.g. BA Arts, MSc Biology etc.], please state subject.

7. I am studying dentistry via the following route

- ○ Undergraduate entry curriculum
- ○ Graduate entry curriculum
- ○ Diploma in dental hygiene

CRANIAL NERVE INFORMATION

1

8. Have you heard of the cranial nerves previously?

- Yes
- No
- Don't know

9. If Yes, how many pairs of cranial nerves are there?

10. Which nerve(s) carries the sense of vision?

- Abducent nerve
- Accessory nerve
- Facial nerve
- Glossopharyngeal nerve
- Hypoglossal nerve
- Occulomotor nerve
- Olfactory nerve
- Optic nerve
- Trigeminal nerve
- Trochlear nerve
- Vagus nerve
- Vestibulocochlear nerve
- Don't know

11. Which nerve(s) supplies the muscles of mastication?

- Abducent nerve
- Accessory nerve
- Facial nerve
- Glossopharyngeal nerve
- Hypoglossal nerve
- Occulomotor nerve
- Olfactory nerve
- Optic nerve
- Trigeminal nerve
- Trochlear nerve
- Vagus nerve
- Vestibulocochlear nerve
- Don't know

12. Which nerve(s) carries the sensation of smell?

- Abducent nerve
- Accessory nerve
- Facial nerve
- Glossopharyngeal nerve
- Hypoglossal nerve
- Occulomotor nerve
- Olfactory nerve
- Optic nerve
- Trigeminal nerve
- Trochlear nerve
- Vagus nerve
- Vestibulocochlear nerve
- Don't know

13. Which nerve(s) supplies the muscles of the eye?

- Abducent nerve
- Accessory nerve
- Facial nerve
- Glossopharyngeal nerve
- Hypoglossal nerve
- Occulomotor nerve
- Olfactory nerve
- Optic nerve
- Trigeminal nerve
- Trochlear nerve
- Vagus nerve
- Vestibulocochlear nerve
- Don't know

14. Which nerve(s) supplies the sensory innervation to the face?

- Abducent nerve
- Accessory nerve
- Facial nerve
- Glossopharyngeal nerve
- Hypoglossal nerve
- Occulomotor nerve
- Olfactory nerve
- Optic nerve
- Trigeminal nerve
- Trochlear nerve
- Vagus nerve
- Vestibulocochlear nerve
- Don't know

15. Which nerve(s) supplies the muscles of facial expression?

- Abducent nerve
- Accessory nerve
- Facial nerve
- Glossopharyngeal nerve
- Hypoglossal nerve
- Occulomotor nerve
- Olfactory nerve
- Optic nerve
- Trigeminal nerve
- Trochlear nerve
- Vagus nerve
- Vestibulocochlear nerve
- Don't know

16. Which nerve(s) carries the taste sensation?

- Abducent nerve
- Accessory nerve
- Facial nerve
- Glossopharyngeal nerve
- Hypoglossal nerve
- Occulomotor nerve
- Olfactory nerve
- Optic nerve
- Trigeminal nerve
- Trochlear nerve
- Vagus nerve
- Vestibulocochlear nerve
- Don't know

17. Which nerve(s) supplies the muscles of the tongue?

- Abducent nerve
- Accessory nerve
- Facial nerve
- Glossopharyngeal nerve
- Hypoglossal nerve
- Occulomotor nerve
- Olfactory nerve
- Optic nerve
- Trigeminal nerve
- Trochlear nerve
- Vagus nerve
- Vestibulocochlear nerve
- Don't know

18. Which nerve(s) provides the sense of hearing?

- Abducent nerve
- Accessory nerve
- Facial nerve
- Glossopharyngeal nerve
- Hypoglossal nerve
- Occulomotor nerve
- Olfactory nerve
- Optic nerve
- Trigeminal nerve
- Trochlear nerve
- Vagus nerve
- Vestibulocochlear nerve
- Don't know

19. Which nerve(s) supplies the muscles of the neck?

- Abducent nerve
- Accessory nerve
- Facial nerve
- Glossopharyngeal nerve
- Hypoglossal nerve
- Occulomotor nerve
- Olfactory nerve
- Optic nerve
- Trigeminal nerve
- Trochlear nerve
- Vagus nerve
- Vestibulocochlear nerve
- Don't know

20. Which nerve(s) supplies the muscles of the soft palate?

- Abducent nerve
- Accessory nerve
- Facial nerve
- Glossopharyngeal nerve
- Hypoglossal nerve
- Occulomotor nerve
- Olfactory nerve
- Optic nerve
- Trigeminal nerve
- Trochlear nerve
- Vagus nerve
- Vestibulocochlear nerve
- Don't know

21. How many major branches does the trigeminal nerve have?

7

22. Which nerve(s) supplies the muscles of the pharynx?

- Abducent nerve
- Accessory nerve
- Facial nerve
- Glossopharyngeal nerve
- Hypoglossal nerve
- Occulomotor nerve
- Olfactory nerve
- Optic nerve
- Trigeminal nerve
- Trochlear nerve
- Vagus nerve
- Vestibulocochlear nerve
- Don't know

23. Which nerve(s) provides the sense of balance?

- Abducent nerve
- Accessory nerve
- Facial nerve
- Glossopharyngeal nerve
- Hypoglossal nerve
- Occulomotor nerve
- Olfactory nerve
- Optic nerve
- Trigeminal nerve
- Trochlear nerve
- Vagus nerve
- Vestibulocochlear nerve
- Don't know

24. Which nerve(s) supplies the salivary glands?

- Abducent nerve
- Accessory nerve
- Facial nerve
- Glossopharyngeal nerve
- Hypoglossal nerve
- Occulomotor nerve
- Olfactory nerve
- Optic nerve
- Trigeminal nerve
- Trochlear nerve
- Vagus nerve
- Vestibulocochlear nerve
- Don't know

25. Which of the following are part of the brainstem?

- Cerebellum
- Cerebrum
- Medulla
- Midbrain
- Pons
- Spinal cord
- Don't know

26. How would you rank the following education methods in teaching, with 1= least important and 10= most important.

	1	2	3	4	5	6	7	8	9	10
Lectures	○	○	○	○	○	○	○	○	○	○
Books	○	○	○	○	○	○	○	○	○	○
Computer-assisted learning	○	○	○	○	○	○	○	○	○	○
In class drawings	○	○	○	○	○	○	○	○	○	○
Practicals	○	○	○	○	○	○	○	○	○	○
Tutorials	○	○	○	○	○	○	○	○	○	○
Self-directed learning	○	○	○	○	○	○	○	○	○	○
Case-based problem solving	○	○	○	○	○	○	○	○	○	○
Powerpoint	○	○	○	○	○	○	○	○	○	○
Animation	○	○	○	○	○	○	○	○	○	○

27. How would you rate your knowledge of the cranial nerves?

- ○ Excellent
- ○ Good
- ○ Average
- ○ Poor
- ○ No knowledge

28. I am interested in the role of cranial nerves in dentistry.

- ○ Strongly agree
- ○ Agree
- ○ Neither agree nor disagree
- ○ Disagree
- ○ Strongly disagree

29. The use of animation facilitates learning of dental anatomy?

- ○ Strongly agree
- ○ Agree
- ○ Neither agree nor disagree
- ○ Disagree
- ○ Strongly disagree

ASSESSMENT OF CRANIAL NERVE KNOWLEDGE

CRANIAL NERVE INFORMATION

30. Please rate the following where SA- Strongly agree, A- Agree, N- Neither agree nor disagree, D- Disagree, SD-Strongly disagree.

	SA	A	N	D	SD
I use animations to assist in my study	○	○	○	○	○
I think animations are helpful in understanding difficult topics	○	○	○	○	○
I think animations should be used in lectures	○	○	○	○	○
I think animations should be made for difficult topics	○	○	○	○	○

Appendix 3

Post-animation questionnaire –Two week access to the animation

(SurveyMonkey)

Post assessment of cranial nerves

1. Please state your student number.

2. Did you watch the animation?

- Yes
- No

3. When did you watch the animation?

- Morning
- Afternoon
- Evening
- At night
- Not applicable
- Other (please specify)

4. How many times did you watch the entire animation?

5. How many times did you watch clips from the animation?

6. If you watched clips from the animation, which clips did you watch repeatedly?

7. Where did you watch the animation?

- Campus
- Home
- While commuting
- Other (please specify)

1

8. Did you watch the animation

- Alone
- With classmates/study group

9. Which device(s) did you use to watch the animation?

- Computer
- Laptop
- Mobile phone
- Tablet/Ipad
- Other (please specify)

10. When did you watch the animation?

- Before studying
- While studying
- After studying the cranial neves
- Not applicable

11. Do you think the animation was useful in understanding the cranial nerves?

- Yes
- No

12. Do you think it would be helpful to use the animations during the lectures?

- Yes
- No

13. Would you like to see more animations on similar topics of anatomy?

- Yes
- No

14. Do you have any suggestions for improvement.

15. Please rate the following where SA- Strongly agree, A- Agree, N- Neither agree nor disagree, D- Disagree, SD-Strongly disagree.

2

	SA	A	N	D	SD
I enjoyed watching the animation	○	○	○	○	○
Cranial nerves are a difficult topic to visualize	○	○	○	○	○
The names of the cranial nerves are easy to remember	○	○	○	○	○
The course of the cranial nerve is difficult to visualize	○	○	○	○	○
The functions of the cranial nerves are difficult to understand	○	○	○	○	○
Cranial nerves are an easy topic to memorize	○	○	○	○	○
The animation helped me study for the cranial nerves	○	○	○	○	○
The animation improved my understanding of the cranial nerves	○	○	○	○	○
The animation was useful in understanding the cranial nerves	○	○	○	○	○
The animation helped me with the conceptual understanding of the cranial nerves	○	○	○	○	○
The animation helped me with the conceptual understanding of the functions/origins of the cranial nerves	○	○	○	○	○
The animation explained the concept clearly	○	○	○	○	○
The animation presented the anatomy very clearly	○	○	○	○	○
The animation presented the functions very clearly	○	○	○	○	○
The animation is not a useful learning resource	○	○	○	○	○
The animation was of good technical quality	○	○	○	○	○

3

	SA	A	N	SD	D
The animation was easy to understand	○	○	○	○	○
The pace of the animation was too fast to follow	○	○	○	○	○
The duration of the animation was satisfactory	○	○	○	○	○
It will be helpful to use the animations during the lectures	○	○	○	○	○
I would you like to see more animations on similar topics of anatomy	○	○	○	○	○
I think animations should be used in lectures	○	○	○	○	○
I think animations should be made for difficult topics	○	○	○	○	○

16. Do you think that animations are a useful teaching tool? Please explain.

17. Did you encounter any technical difficulties while watching the animation?

- ○ Yes
- ○ No

18. I am interested in the role of cranial nerves in dentistry.

- ○ Strongly agree
- ○ Agree
- ○ Neither agree nor disagree
- ○ Disagree
- ○ Strongly disagree

4

19. How would you rate your knowledge of the cranial nerves?

- Excellent
- Good
- Average
- Poor
- No knowledge

20. The use of animation facilitates learning of dental anatomy.

- Strongly agree
- Agree
- Neither agree nor disagree
- Disagree
- Strongly disagree

21. How would you rank the following education methods in teaching, with 1= least important and 10= most important.

	1	2	3	4	5	6	7	8	9	10
Lectures										
Books										
Computer-assisted learning										
In class drawings										
Practicals										
Tutorials										
Self-directed learning										
Case-based problem solving										
Powerpoint										
Animation										

22. How many pairs of cranial nerves are there?

5

23. Which nerve(s) carries the sense of vision?

- Abducent nerve
- Accessory nerve
- Facial nerve
- Glossopharyngeal nerve
- Hypoglossal nerve
- Occulomotor nerve
- Olfactory nerve
- Optic nerve
- Trigeminal nerve
- Trochlear nerve
- Vagus nerve
- Vestibulocochlear nerve
- Don't know

24. Which nerve(s) supplies the muscles of mastication?

- Abducent nerve
- Accessory nerve
- Facial nerve
- Glossopharyngeal nerve
- Hypoglossal nerve
- Occulomotor nerve
- Olfactory nerve
- Optic nerve
- Trigeminal nerve
- Trochlear nerve
- Vagus nerve
- Vestibulocochlear nerve
- Don't know

25. Which nerve(s) carries the sensation of smell?

- Abducent nerve
- Accessory nerve
- Facial nerve
- Glossopharyngeal nerve
- Hypoglossal nerve
- Occulomotor nerve
- Olfactory nerve
- Optic nerve
- Trigeminal nerve
- Trochlear nerve
- Vagus nerve
- Vestibulocochlear nerve
- Don't know

26. Which nerve(s) supplies the muscles of the eye?

- Abducent nerve
- Accessory nerve
- Facial nerve
- Glossopharyngeal nerve
- Hypoglossal nerve
- Occulomotor nerve
- Olfactory nerve
- Optic nerve
- Trigeminal nerve
- Trochlear nerve
- Vagus nerve
- Vestibulocochlear nerve
- Don't know

27. Which nerve(s) supplies the sensory innervation to the face?

- Abducent nerve
- Accessory nerve
- Facial nerve
- Glossopharyngeal nerve
- Hypoglossal nerve
- Occulomotor nerve
- Olfactory nerve
- Optic nerve
- Trigeminal nerve
- Trochlear nerve
- Vagus nerve
- Vestibulocochlear nerve
- Don't know

28. Which nerve(s) supplies the muscles of facial expression?

- Abducent nerve
- Accessory nerve
- Facial nerve
- Glossopharyngeal nerve
- Hypoglossal nerve
- Occulomotor nerve
- Olfactory nerve
- Optic nerve
- Trigeminal nerve
- Trochlear nerve
- Vagus nerve
- Vestibulocochlear nerve
- Don't know

29. Which nerve(s) carries the taste sensation?

- Abducent nerve
- Accessory nerve
- Facial nerve
- Glossopharyngeal nerve
- Hypoglossal nerve
- Occulomotor nerve
- Olfactory nerve
- Optic nerve
- Trigeminal nerve
- Trochlear nerve
- Vagus nerve
- Vestibulocochlear nerve
- Don't know

30. Which nerve(s) supplies the muscles of the tongue?

- Abducent nerve
- Accessory nerve
- Facial nerve
- Glossopharyngeal nerve
- Hypoglossal nerve
- Occulomotor nerve
- Olfactory nerve
- Optic nerve
- Trigeminal nerve
- Trochlear nerve
- Vagus nerve
- Vestibulocochlear nerve
- Don't know

31. Which nerve(s) provides the sense of hearing?

- Abducent nerve
- Accessory nerve
- Facial nerve
- Glossopharyngeal nerve
- Hypoglossal nerve
- Occulomotor nerve
- Olfactory nerve
- Optic nerve
- Trigeminal nerve
- Trochlear nerve
- Vagus nerve
- Vestibulocochlear nerve
- Don't know

32. Which nerve(s) supplies the muscles of the neck?

- Abducent nerve
- Accessory nerve
- Facial nerve
- Glossopharyngeal nerve
- Hypoglossal nerve
- Occulomotor nerve
- Olfactory nerve
- Optic nerve
- Trigeminal nerve
- Trochlear nerve
- Vagus nerve
- Vestibulocochlear nerve
- Don't know

10

33. Which nerve(s) supplies the muscles of the soft palate?

- Abducent nerve
- Accessory nerve
- Facial nerve
- Glossopharyngeal nerve
- Hypoglossal nerve
- Occulomotor nerve
- Olfactory nerve
- Optic nerve
- Trigeminal nerve
- Trochlear nerve
- Vagus nerve
- Vestibulocochlear nerve
- Don't know

34. Which nerve(s) supplies the salivary glands?

- Abducent nerve
- Accessory nerve
- Facial nerve
- Glossopharyngeal nerve
- Hypoglossal nerve
- Occulomotor nerve
- Olfactory nerve
- Optic nerve
- Trigeminal nerve
- Trochlear nerve
- Vagus nerve
- Vestibulocochlear nerve
- Don't know

35. Which nerve(s) supplies the muscles of the pharynx?

- Abducent nerve
- Accessory nerve
- Facial nerve
- Glossopharyngeal nerve
- Hypoglossal nerve
- Occulomotor nerve
- Olfactory nerve
- Optic nerve
- Trigeminal nerve
- Trochlear nerve
- Vagus nerve
- Vestibulocochlear nerve
- Don't know

36. Which nerve(s) provides the sense of balance?

- Abducent nerve
- Accessory nerve
- Facial nerve
- Glossopharyngeal nerve
- Hypoglossal nerve
- Occulomotor nerve
- Olfactory nerve
- Optic nerve
- Trigeminal nerve
- Trochlear nerve
- Vagus nerve
- Vestibulocochlear nerve
- Don't know

37. How many branches are there of the trigeminal nerve?

12

38. Which of the following are part of the brainstem?

- Cerebellum
- Cerebrum
- Medulla
- Midbrain
- Pons
- Spinal cord
- Don't know

13

Appendix 4

Post-animation questionnaire – Single viewing of the animation

(SurveyMonkey)

Post-Questionnaire 1

1. Please write your student number.

2. Do you think the animation was useful in understanding the cranial nerves?

- Yes
- No

3. Do you think it would be helpful to use the animations during lectures?

- Yes
- No

4. Would you like to see more animations on similar topics of anatomy?

- Yes
- No

5. Please rate the following where SA- Strongly agree, A- Agree, N- Neither agree nor disagree, D- Disagree, SD- Strongly disagree

	SD	D	N	A	SA
I enjoyed watching the animation					
Cranial nerves are a difficult topic to visualize					
The names of the cranial nerves are easy to remember					
The course of the cranial nerves is difficult to visualize					
The functions of the cranial nerves are difficult to understand					
Cranial nerves are an easy topic to memorize					

1

	SD	D	N	A	SA
The animation improved my understanding of the cranial nerves	○	○	○	○	○
The animation was useful in understanding the cranial nerves	○	○	○	○	○
The animation helped me with the conceptual understanding of the cranial nerves	○	○	○	○	○
The animation helped me with the conceptual understanding of the functions/origins of the cranial nerves	○	○	○	○	○
The animation explained the concept clearly	○	○	○	○	○
The animation presented the anatomy very clearly	○	○	○	○	○
The animation presented the functions very clearly	○	○	○	○	○
The animation is not a useful learning resource	○	○	○	○	○
The animation was of good technical quality	○	○	○	○	○
The animation was easy to understand	○	○	○	○	○
The pace of the animation was too fast to follow	○	○	○	○	○
The duration of the animation was satisfactory	○	○	○	○	○
It will be helpful to use the animations during the lectures	○	○	○	○	○
I would like to see more animations on similar topics of anatomy	○	○	○	○	○
I think animations should be used in lectures	○	○	○	○	○
I think animations should be made for difficult topics	○	○	○	○	○

2

6. Did the animation interest/encourage you to study the cranial nerves?

- ◯ Yes
- ◯ No
- ◯ Don't know

7. I am interested in the role of cranial nerves in dentistry.

- ◯ Strongly agree
- ◯ Agree
- ◯ Neither agree nor disagree
- ◯ Disagree
- ◯ Strongly disagree

8. How would you rate your knowledge of the cranial nerves?

- ◯ Excellent
- ◯ Good
- ◯ Average
- ◯ Poor
- ◯ No knowledge

9. The use of animation facilitates learning of dental anatomy?

- ◯ Strongly agree
- ◯ Agree
- ◯ Neither agree nor disagree
- ◯ Disagree
- ◯ Strongly disagree

10. How would you rank the following education methods in teaching,with 1= most important, and 10= least important.

	1	2	3	4	5	6	7	8	9	10
Lectures	○	○	○	○	○	○	○	○	○	○
Books	○	○	○	○	○	○	○	○	○	○
Computer-assisted learning	○	○	○	○	○	○	○	○	○	○
In class drawings	○	○	○	○	○	○	○	○	○	○
Practicals	○	○	○	○	○	○	○	○	○	○
Tutorials	○	○	○	○	○	○	○	○	○	○
Self-directed learning	○	○	○	○	○	○	○	○	○	○
Case-based problem solving	○	○	○	○	○	○	○	○	○	○
Powerpoint	○	○	○	○	○	○	○	○	○	○
Animation	○	○	○	○	○	○	○	○	○	○

4

Post-Questionnaire 1

Cranial nerve knowledge

11. How many pairs of cranial nerves are there?

12. Which nerve(s) carries the sense of vision? (Please select all that apply.)

- ◯ Abducent nerve
- ◯ Accessory nerve
- ◯ Facial nerve
- ◯ Glossopharyngeal nerve
- ◯ Hypoglossal nerve
- ◯ Occulomotor nerve
- ◯ Olfactory nerve
- ◯ Optic nerve
- ◯ Trigeminal nerve
- ◯ Trochlear nerve
- ◯ Vagus nerve
- ◯ Vestibulocochlear nerve
- ◯ Don't know

5

13. Which nerve(s) supplies the muscles of mastication? (Please select all that apply.)

- ◯ Abducent nerve
- ◯ Accessory nerve
- ◯ Facial nerve
- ◯ Glossopharyngeal nerve
- ◯ Hypoglossal nerve
- ◯ Occulomotor nerve
- ◯ Olfactory nerve
- ◯ Optic nerve
- ◯ Trigeminal nerve
- ◯ Trochlear nerve
- ◯ Vagus nerve
- ◯ Vestibulocochlear nerve
- ◯ Don't know

14. Which nerve(s) carries the sensation of smell? (Please select all that apply.)

- ◯ Abducent nerve
- ◯ Accessory nerve
- ◯ Facial nerve
- ◯ Glossopharyngeal nerve
- ◯ Hypoglossal nerve
- ◯ Occulomotor nerve
- ◯ Olfactory nerve
- ◯ Optic nerve
- ◯ Trigeminal nerve
- ◯ Trochlear nerve
- ◯ Vagus nerve
- ◯ Vestibulocochlear nerve
- ◯ Don't know

15. Which nerve(s) supplies the muscles of the eye? (Please select all that apply.)

- ◯ Abducent nerve
- ◯ Accessory nerve
- ◯ Facial nerve
- ◯ Glossopharyngeal nerve
- ◯ Hypoglossal nerve
- ◯ Occulomotor nerve
- ◯ Olfactory nerve
- ◯ Optic nerve
- ◯ Trigeminal nerve
- ◯ Trochlear nerve
- ◯ Vagus nerve
- ◯ Vestibulocochlear nerve
- ◯ Don't know

16. Which nerve(s) supplies the sensory innervation to the face? (Please select all that apply.)

- ◯ Abducent nerve
- ◯ Accessory nerve
- ◯ Facial nerve
- ◯ Glossopharyngeal nerve
- ◯ Hypoglossal nerve
- ◯ Occulomotor nerve
- ◯ Olfactory nerve
- ◯ Optic nerve
- ◯ Trigeminal nerve
- ◯ Trochlear nerve
- ◯ Vagus nerve
- ◯ Vestibulocochlear nerve
- ◯ Don't know

17. Which nerve(s) supplies the muscles of facial expression? (Please select all that apply.)

- ◯ Abducent nerve
- ◯ Accessory nerve
- ◯ Facial nerve
- ◯ Glossopharyngeal nerve
- ◯ Hypoglossal nerve
- ◯ Occulomotor nerve
- ◯ Olfactory nerve
- ◯ Optic nerve
- ◯ Trigeminal nerve
- ◯ Trochlear nerve
- ◯ Vagus nerve
- ◯ Vestibulocochlear nerve
- ◯ Don't know

18. Which nerve(s) carries the taste sensation? (Please select all that apply.)

- ◯ Abducent nerve
- ◯ Accessory nerve
- ◯ Facial nerve
- ◯ Glossopharyngeal nerve
- ◯ Hypoglossal nerve
- ◯ Occulomotor nerve
- ◯ Olfactory nerve
- ◯ Optic nerve
- ◯ Trigeminal nerve
- ◯ Trochlear nerve
- ◯ Vagus nerve
- ◯ Vestibulocochlear nerve
- ◯ Don't know

19. Which nerve(s) supplies the muscles of the tongue? (Please select all that apply.)

- ◯ Abducent nerve
- ◯ Accessory nerve
- ◯ Facial nerve
- ◯ Glossopharyngeal nerve
- ◯ Hypoglossal nerve
- ◯ Occulomotor nerve
- ◯ Olfactory nerve
- ◯ Optic nerve
- ◯ Trigeminal nerve
- ◯ Trochlear nerve
- ◯ Vagus nerve
- ◯ Vestibulocochlear nerve
- ◯ Don't know

20. Which nerve(s) provides the sense of hearing? (Please select all that apply.)

- ◯ Abducent nerve
- ◯ Accessory nerve
- ◯ Facial nerve
- ◯ Glossopharyngeal nerve
- ◯ Hypoglossal nerve
- ◯ Occulomotor nerve
- ◯ Olfactory nerve
- ◯ Optic nerve
- ◯ Trigeminal nerve
- ◯ Trochlear nerve
- ◯ Vagus nerve
- ◯ Vestibulocochlear nerve
- ◯ Don't know

21. Which nerve(s) supplies the muscles of the neck? (Please select all that apply.)

- ◯ Abducent nerve
- ◯ Accessory nerve
- ◯ Facial nerve
- ◯ Glossopharyngeal nerve
- ◯ Hypoglossal nerve
- ◯ Occulomotor nerve
- ◯ Olfactory nerve
- ◯ Optic nerve
- ◯ Trigeminal nerve
- ◯ Trochlear nerve
- ◯ Vagus nerve
- ◯ Vestibulocochlear nerve
- ◯ Don't know

22. Which nerve(s) supplies the muscles of the soft palate? (Please select all that apply.)

- ◯ Abducent nerve
- ◯ Accessory nerve
- ◯ Facial nerve
- ◯ Glossopharyngeal nerve
- ◯ Hypoglossal nerve
- ◯ Occulomotor nerve
- ◯ Olfactory nerve
- ◯ Optic nerve
- ◯ Trigeminal nerve
- ◯ Trochlear nerve
- ◯ Vagus nerve
- ◯ Vestibulocochlear nerve
- ◯ Don't know

10

23. Which nerve(s) supplies the salivary glands? (Please select all that apply.)

- ◯ Abducent nerve
- ◯ Accessory nerve
- ◯ Facial nerve
- ◯ Glossopharyngeal nerve
- ◯ Hypoglossal nerve
- ◯ Occulomotor nerve
- ◯ Olfactory nerve
- ◯ Optic nerve
- ◯ Trigeminal nerve
- ◯ Trochlear nerve
- ◯ Vagus nerve
- ◯ Vestibulocochlear nerve
- ◯ Don't know

24. Which nerve(s) supplies the muscles of the pharynx? (Please select all that apply.)

- ◯ Abducent nerve
- ◯ Accessory nerve
- ◯ Facial nerve
- ◯ Glossopharyngeal nerve
- ◯ Hypoglossal nerve
- ◯ Occulomotor nerve
- ◯ Olfactory nerve
- ◯ Optic nerve
- ◯ Trigeminal nerve
- ◯ Trochlear nerve
- ◯ Vagus nerve
- ◯ Vestibulocochlear nerve
- ◯ Don't know

25. Which nerve(s) provides the sense of balance? (Please select all that apply.)

- ◯ Abducent nerve
- ◯ Accessory nerve
- ◯ Facial nerve
- ◯ Glossopharyngeal nerve
- ◯ Hypoglossal nerve
- ◯ Occulomotor nerve
- ◯ Olfactory nerve
- ◯ Optic nerve
- ◯ Trigeminal nerve
- ◯ Trochlear nerve
- ◯ Vagus nerve
- ◯ Vestibulocochlear nerve
- ◯ Don't know

26. How many branches are there of the trigeminal nerve?

[ ]

27. Which of the following are part of the brainstem?

- ◯ Cerebellum
- ◯ Cerebrum
- ◯ Medulla
- ◯ Midbrain
- ◯ Pons
- ◯ Spinal cord
- ◯ Don't know

12

Appendix 5

Ethical approval form for cranial nerve animation- SREC, UCC

UCC Social Research Ethics Committee (SREC)

ETHICS APPROVAL FORM

Name of applicant	Dr. André Toulouse Date	06 June 2015
Contact Details	Phone: (021) 4205477 Email	a.toulouse@ucc.ie
Department/Unit	Department of Anatomy and Neuroscience	
Title of project	Evaluation of the impact of the use of an animated video clip for the study of the cranial nerves.	

		YES	NO
1	Do you consider that this project has significant ethical implications?		x
2	Will you describe the main research procedures to participants in advance, so that they are informed about what to expect?	x	
3	Will participation be voluntary?	x	
4	Will you obtain informed consent in writing from participants?	x	
5	Will you tell participants that they may withdraw from the research at any time and for any reason, and (where relevant) omit questionnaire items to which they do not wish to respond?	x	
6	Will data be treated with full confidentiality / anonymity (as appropriate)?	x	
7	If results are published, will anonymity be maintained and participants not identified?	x	
8	Will you debrief participants at the end of their participation (i.e. give them a brief explanation of the study)?	x	
9	Will your project involve deliberately misleading participants in any way?		x
10	Will your participants include schoolchildren (under 18 years of age)?		x
11	Will your participants include people with learning or communication difficulties?		x
12	Will your participants include patients?		x
13	Will your participants include people in custody?		x
14	Will your participants include people engaged in illegal activities (e.g. drug taking; illegal Internet behaviour)?		x
15	Is there a realistic risk of participants experiencing either physical or psychological distress?		x
16	If yes to 15, has a proposed procedure, including the name of a contact person, been given? (see no 23)		

DESCRIPTION OF THE PROJECT

17. Aims of the project:
This project aims to assess the impact of a purpose-designed animated video clip for the study of the anatomy and function of the cranial nerves in the context of dentistry and dental hygiene. Neuroanatomy has been identified as an area of particular difficulty by first year dental students and dental hygiene students, at University College Cork. We have designed a short animation aimed at supplementing the traditional lectures with the overall goal of providing students with an additional learning tool. This project will be divided in two phases. In the first phase, to be conducted in autumn 2015, the usefulness of the video clip as a learning tool will be assessed outside of the class context. In the second phase, in autumn 2016, the effectiveness of the video clip as a supplemental learning tool in the context of the neuroanatomy lectures will be assessed.

18. Brief description and justification of methods and measures to be used (attach copy of questionnaire / interview protocol / discussion guide / etc.)

This study is aimed for first year dental students and first year dental hygiene students. The study consists of two phases. Phase 1 will be conducted in autumn 2015 and will evaluate the usefulness of the video clip as a learning tool assessed outside of the class context. After providing information about the study and obtaining consent, the participants will be requested to fill a pre-assessment questionnaire (Questionnaire 1 – attached) about their knowledge of the anatomy of the cranial nerves. The participants will then be shown an animation detailing the names, roles and anatomy of the cranial nerves in a context related to dentistry. The design of the animated clip was based on Mayer's theory of multimedia learning. After watching the animation the participants will be requested to fill in a post assessment questionnaire to help us evaluate their understanding and knowledge of the cranial nerves. This second questionnaire will also collect student feedback on the animation (Questionnaire 2 – attached).

Phase 2 will be conducted in autumn 2016. Recruited participant will be first year dental students and first year dental hygienists, a similar cohort to Phase 1. In this phase the effectiveness of the video clip as a supplemental learning tool in the context of the neuroanatomy lectures will be assessed. After providing information about the study and obtaining consent, the participants will be requested to fill a pre-assessment questionnaire (Questionnaire 1 – attached) about their knowledge of the anatomy of the cranial nerves. The participants will then attend lectures and dissection room tutorials on neuroanatomy as part of their first year anatomy module. The students will then be randomly divided into two groups. One group will be shown the animation whereas the other group will not see the animation. At this stage both groups will be requested to fill in a post assessment questionnaire (Questionnaire 2 – attached) to help us evaluate their understanding and knowledge of the cranial nerves. The questionnaires are the same as those used in phase 1 and will also collect student feedback on the usefulness of the tool.

Once all the data has been collected it will be analysed and validated using Kendall's tau test. Detailed statistical analysis will be done and pictorial representation of the results will be generated using Prism.

19. Participants: recruitment methods, number, age, gender, exclusion/inclusion criteria

Participants will be recruited from the first year dental students and first year dental hygienists cohort (2015-2016). Following an initial information session we expect to recruit approximately 50 to 55 participants reflecting the race, age and gender balance of each of the student cohorts. Detailed information about the study will be provided. Participation is voluntary and informed consent will be obtained from the participants. Participants can withdraw at any time following a written demand to Dr. André Toulouse and all data pertaining to their participation will be destroyed.

20. Concise statement of ethical issues raised by the project and how you intend to deal with them

We expect that there will be no ethical issues with this project. The forms will be partly anonymised, only student numbers will be collected for assessment of performance before and after presentation of the animation and will be stored securely. The data will be entered on a computer secured by a password protected login in a limited access room. Complete anonymity will be ensured throughout for publications. Participation and performance during the study will not have impact on the student assessment.

21. Arrangements for informing participants about the nature of the study (cf. Question 3)

An information session will be arranged with the students. Written information regarding the study will be provided to the participants as part of the consent form. Any questions/queries will be addressed verbally, if they arise.

22. How you will obtain Informed Consent - cf. Question 4 (attach relevant form[s])

Informed consent form (attached) will be obtained before the start of the study. Participants will be given an informed consent form to read and sign. A copy of the form will be given to the students for their own records. The consent form will be submitted with this application. Participants can withdraw at any time following a written demand to Dr. André Toulouse and all data pertaining to their participation will be destroyed.

23. Outline of debriefing process (cf. Question 8). If you answered YES to Question 15, give details here. State what you will advise participants to do if they should experience problems (e.g. who to contact for help).

After the completion of the study the participants would be given information about the relevance of the study, the introduction of the teaching pedagogy and its relevance. We don't envision any problem or discomfort arising among the participants after watching this video. However, any questions/queries can be addressed to the following email address: M.Lone@ucc.ie

24. Estimated start date and duration of project.

September 2015 to August 2017.

Signed _____A. Toulouse_____ Date _____March 2015_____
Applicant

Notes

1. Please submit this form and any attachments to Dr. S. Hammond, Chair, SREC, c/o Miriam Collins, Office of the Vice President for Research and Innovation, Block E, 4th Floor, Food Science Building, University College Cork, College Road, Cork. Please also forward an electronic copy to srec@ucc.ie

2. Research proposals can receive only provisional approval from SREC in the absence of approval from any agency where you intend to recruit participants. If you have already secured the relevant consent, please enclose a copy with this form.

3. SREC is not primarily concerned with methodological issues but may comment on such issues in so far as they have ethical implications.

This form is adapted from pp. 13-14 of Guidelines for Minimum Standards of Ethical Approval in Psychological Research (British Psychological Society, July, 2004)

Last update: 2011-07-19

Appendix 6

Student consent form for the cranial nerve animation

Department of Anatomy and Neuroscience, UCC

Project information for research participants

Evaluation of the impact of the use of an animated video clip for the study of the cranial nerves.

Investigators: Dr. André Toulouse, Dr. Eric Downer, Dr. Joe McKenna, Prof. John Cryan, Dr. Mutahira Lone.

Study Location: Department of Anatomy and Neuroscience, University College Cork, Cork, Ireland.

Purpose of the Study: This study aims to assess the validity and usefulness of an animated video clip for teaching neuroanatomy, at University College Cork (UCC).

What will the study involve? The study will involve answering 2 questionnaires and watching an animation. There are 30 questions in the first questionnaire which takes approximately 10 – 15 minutes to complete. You will be requested to fill it in the lecture room and return it to us. At a later stage you will be asked to watch an animation which is 4 minutes long. After watching the animation you will be asked to fill another questionnaire with 38 questions and should take approximately 20 minutes to complete.

Why have you been asked to take part? You have been asked to participate because the overall aim of our research project is to introduce innovative teaching pedagogies in anatomy for first year dental students and first year dental hygienists at UCC. Your participation allows us to gauge the development of a new animated study tool and assess its usefulness for future incorporation in class material.

Do you have to take part? Your participation is entirely voluntary and we greatly value your input. Whether you participate or not, will not influence your grades or performance evaluations. To indicate that you are willing to participate, you are asked to sign the attached consent form.

The questionnaires used during the study will be partly anonymised, only student numbers will be collected for statistical analysis of group performance before and after presentation of the animation. All data will be stored securely and retained up to seven years after the completion of the study at which time it will be destroyed.

The overall analysis of the results will be presented in Dr Lone's PhD thesis and may also be published in a research journal. While student numbers will be used for initial data analysis, they will not be used past that stage and anonymity will be ensured in publications.

Any questions or queries will be addressed by contacting the investigators. Participants can withdraw within 4 weeks of the start of the study, following a written demand to Dr.

André Toulouse (a.toulouse@ucc.ie) and all data pertaining to their participation will be destroyed.

If you need any further information, you can contact the researcher, Dr. Mutahira Lone (m.lone@ucc.ie).

This study has been reviewed and approved by the Social Research Ethics Committee at University College Cork.
.
If you need any further information, you can contact me: [Dr. Mutahira Lone, m.lone@ucc.ie].

If you agree to take part in the study, please sign the consent form overleaf.

We would like to sincerely than you for your participation in this study.

Consent Form

Evaluation of the impact of the use of an animated video clip for the study of the cranial nerves.

I……agree to participate in this research study.

The purpose and nature of the study has been explained to me in writing.

I am participating voluntarily.

I give permission for my data to be used for further analysis and research

I understand that my participation will not affect in anyway my grades/examination performance.

I understand that anonymity will be ensured throughout the research process.

Signed……. Date…….

RS Ver 6 2/11/07

Appendix 7

Student questionnaire - Thiel study

Assessment of Thiel-embalmed cadavers as a teaching tool

The objective of this questionnaire is to assess the use of Thiel-embalmed human cadaveric material as a teaching aid in oral cavity examination. Thiel embalming is a process used to preserve the flexibility and life-like nature of cadaveric material.
Participation in this survey is highly appreciated since it will aid in improving dental teaching. Your participation in this questionnaire is voluntary and will not affect your grade.

While locating the following structures on your partner, please rate how easy they are to identify

1= very difficult, 2= difficult, 3= neither difficult nor easy, 4= easy, 5 = very easy.

Repeat the same procedure on one of the Thiel embalmed specimen and also compare them to your experience with your partner for texture and appearance

1=very unrealistic, 2=unrealistic, 3= neither unrealistic nor realistic, 4=realistic and 5=life like

	Your partner	**Thiel-embalmed specimen**		
	Ease of location	*Ease of location*	*Feel*	*Look*
Lips				
Labial frenulum				
Buccal frenulum				
Labial mucosa				
Buccal mucosa				
Free gingiva				
Attached gingiva				
Hard palate				
Soft palate				
Uvula				
Pterygomandibular raphe				
Tongue (anterior and posterior part)				
Lingual frenulum				

Sub-lingual fold				

3- Please use the space below to provide any extra visual observation/feedback.

Please write your student number:

_____

Thank you for your feedback!

Appendix 8.

Ethical approval form for Thiel study- SREC, UCC

ETHICS APPROVAL FORM

Social Research Ethics Committee (SREC)

University College Cork, Ireland
Coláiste na hOllscoile Corcaigh

Introduction

UCC academic staff and postgraduate research students who are seeking ethical approval should use this approval form. Ethical review by SREC is strongly recommended where the methodology is not clinical or therapeutic in nature and proposes to involve:

- direct interaction with human participants for the purpose of data collection using research methods such as questionnaires, interviews, observations, focus groups etc
- indirect observation with human participant for example using observation, web surveys etc
- access to, or utilisation of, data concerning identifiable individuals.

Application Checklist

This checklist includes all of the items that are required for an application to be deemed complete. In the event that any of these are not present, the application will be returned to the applicant without having been sent to review. Please ensure that your application includes all of these prior to submission. Thank you.

Completed Application Checklist	☐
Completed Ethical Approval Self-Evaluation	☐
Completed Description of Project	☐
Information Sheet(s)	☐
Consent Sheet(s)	☐
Psychometric Instruments / Interview / Focus Group Schedules	☐
I have consulted the UCC *Code of Research Conduct* and believe my proposal is in line with its requirements	☐
If you are under academic supervision, your supervisor has approved the wording of and co-signed this application prior to submission	☐

Please note that you must confirm you have taken account of the University's Code of Research Conduct in order for your application to be considered by SREC

(http://www.ucc.ie/en/media/research/researchatucc/documents/CodeofGoodConductinResearch_000.pdf)

APPLICANT DETAILS

Name of applicant(s)	Dr Mutahira Lone	**Date**	03.10.16
Department/School/Unit, & Supervisor's Name	Department of Anatomy and Neuroscience, Dr. André Toulouse	**Phone**	0214205477
Correspondence Address	Dr André Toulouse, Department of Anatomy and Neuroscience, Western Gateway Building.	**Email**	a.toulouse@ucc.ie
Title of Project	Assessment of Thiel-embalmed cadavers as a teaching tool for oral anatomy and local anesthesia.		

ETHICAL APPROVAL SELF-EVALUATION

		YES	NO
1	Do you consider that this project has significant ethical implications?		X
2	Will you describe the main research procedures to participants in advance, so that they are informed about what to expect?	X	
3	Will participation be voluntary?	X	
4	Will you obtain informed consent in writing from participants?	X	
5	Will you tell participants that they may withdraw from the research at any time and for any reason, and (where relevant) omit questionnaire items to which they do not wish to respond?	X	
6	Will data be treated with full confidentiality / anonymity (as appropriate)?	X	
7	Will data be securely held for a minimum period of seven years after the completion of a research project, in line with the University's Code of Research Conduct?	X	
8	If results are published, will anonymity be maintained and participants not identified?	X	
9	Will you debrief participants at the end of their participation (i.e. give them a brief explanation of the study)?	X	
10	Will your project involve deliberately misleading participants in any way?		X
11	Will your participants include children (under 18 years of age)?		X
12	Will your participants include people with learning or communication difficulties?		X
13	Will your participants include patients?		X
14	Will your participants include people in custody?		X

15	Will your participants include people engaged in illegal activities (e.g. drug taking; illegal Internet behaviour)?		X
16	Is there a realistic risk of participants experiencing either physical or psychological distress?		X
17	If yes to 16, has a proposed procedure, including the name of a contact person, been given? (see no 25)		X
18	If yes to 11, is your research informed by the UCC Child Protection Policy? http://www.ucc.ie/en/ocla/policy/		X

DESCRIPTION OF THE PROJECT

19. Aims of the project (briefly)

This study aims to assess the Thiel-embalmed cadavers as a teaching tool for oral anatomy and local anesthesia.

20. Brief description and justification of methods and measures to be used (attach research questions / copy of questionnaire / interview protocol / discussion guide / etc.)

This study is aimed for the first year dental students and first year hygienists. Once the information about the study has been provided and consent obtained, the participants will be requested to examine and rate the oral cavity features in their class partners and then the Thiel embalmed cadaver (list of oral features provided in the questionnaire). The participants will also be asked to rate the texture and appearance of the oral cavity features seen in the Thiel cadavers (likert scale).

21. Participants: recruitment methods, number, age, gender, exclusion/inclusion criteria, detail permissions

Participants will be recruited from the first year dental students and first year dental hygienists. There will be approximately 50 to 60 students. There will be no recruitment bias based on gender, race or age. Information about the study will be provided. Participation is voluntary and informed consent will be obtained from the participants.

22. Concise statement of ethical issues raised by the project and how you intend to deal with them

We hope there will be no ethical issues with this project. The forms will be anonymous and will be stored securely. The data will be entered on a computer secured by a password protected login in a limited access room. Complete anonymity will be ensured throughout data analysis and for publications.

23. Arrangements for informing participants about the nature of the study (cf. Question 3)

Written information regarding the study will be provided to the participants as part of the consent form. Any questions/queries will be addressed verbally, if they arise.

24. How you will obtain Informed Consent - cf. Question 4 (attach relevant form[s])

Informed consent form will be obtained before the start of the study. Participants will be given an informed consent form to read and sign. A copy of the form will be given to the students for their own records. The consent form will be submitted with this application.

25. Outline of debriefing process (cf. Question 9). If you answered YES to Question 16, give details here. State what you will advise participants to do if they should experience problems (e.g. who to contact for help).
After the completion of the study the participants would be given information about the relevance of the study, the introduction of the teaching pedagogy and its relevance. We don't envision any problem or discomfort arising among the participants after watching this video. However, any questions/queries can be addressed to the following email address: m.lone@ucc.ie

26. Estimated start date and duration of project

October 2016 to October 2017.

Signed _____M.Lone_____ Date _____06.10.16____
Applicant

Signed _____A.Toulouse_____ Date ___06.10.16_____
Research Supervisor/Principal Investigator (if applicable)

Notes

1. Please submit this form and any attachments to srec@ucc.ie (including **a scanned signed copy**).
No hard copies are required.

2. Research proposals can receive only provisional approval from SREC in the absence of approval from any agency where you intend to recruit participants. If you have already secured the relevant consent, please enclose a copy with this form.

3. SREC is not primarily concerned with methodological issues but may comment on such issues in so far as they have ethical implications.

This form is adapted from pp. 13-14 of Guidelines for Minimum Standards of Ethical Approval in Psychological Research (British Psychological Society, July, 2004)

Last update: September 2015

Appendix 9

Student consent form for the Thiel study

Department of Anatomy and Neuroscience, UCC

Project information for research participants

Assessment of Thiel-embalmed cadaver as a teaching tool for oral anatomy and local anesthesia.

Investigators: Dr. André Toulouse, Dr. Eric Downer, Dr. Joe McKenna, Prof. John Cryan, Dr. Mutahira Lone.

Study Location: Department of Anatomy and Neuroscience, University College Cork, Cork, Ireland.

Purpose of the Study: This study aims to assess the Thiel-embalmed cadaver as a teaching tool for oral anatomy and local anesthesia for teaching dental students, at University College Cork (UCC).

What will the study involve? The study will involve performing an examination of the oral cavity of their partner and Thiel-embalmed cadavers and rating the oral cavity features. A questionnaire will be provided with a list of features that need to be examined and rated by the students.

Why have you been asked to take part? You have been asked to participate because the overall aim of our research project is to introduce innovative teaching pedagogies in anatomy for first year dental students and first year dental hygienists at UCC. Your participation allows us to gauge and assess the Thiel-embalmed cadaver as a teaching tool.

Do you have to take part? Your participation is entirely voluntary and we greatly value your input. Whether you participate or not, will not influence your grades or performance evaluations. To indicate that you are willing to participate, you are asked to sign the attached consent form.

The questionnaires used during the study will be partly anonymised, only student numbers will be collected for statistical analysis of group performance before and after presentation of the animation. All data will be stored securely and retained up to seven years after the completion of the study at which time it will be destroyed.

The overall analysis of the results will be presented in Dr Lone's PhD thesis and may also be published in a research journal. While student numbers will be used for initial data analysis, they will not be used past that stage and anonymity will be ensured in publications.

Any questions or queries will be addressed by contacting the investigators. Participants can withdraw within 4 weeks of the start of the study, following a written demand to Dr. André Toulouse (a.toulouse@ucc.ie) and all data pertaining to their participation will be

destroyed.

If you need any further information, you can contact the researcher, Dr. Mutahira Lone (m.lone@ucc.ie).

This study has been reviewed and approved by the Social Research Ethics Committee at University College Cork.

If you need any further information, you can contact me: [Dr. Mutahira Lone, m.lone@ucc.ie].

If you agree to take part in the study, please sign the consent form overleaf.

We would like to sincerely than you for your participation in this study.

Consent Form

Assessment of Thiel-embalmed cadaver as a teaching tool for oral anatomy and local anethesia.

I……agree to participate in this research study.

The purpose and nature of the study has been explained to me in writing.

I am participating voluntarily.

I give permission for my data to be used for further analysis and research

I understand that my participation will not affect in anyway my grades/examination performance.

I understand that anonymity will be ensured throughout the research process.

Signed……. Date…….

RS Ver 6 2/11/07

Appendix 10

Online questionnaire for tooth morphology teaching survey

(LimeSurvey)

Tooth morphology survey questionnaire

This short online questionnaire aims to gather information about various educational pedagogies employed in teaching tooth morphology to dental students.

This questionnaire should not take any longer than 10-15 minutes of your time. Your participation in this survey is voluntary. We will ask you for your name and the name of your institution but this data will not, under any circumstances, be used for assessment purposes and the confidentiality of your responses will be protected at all times.

Any data that will be published will be done so in summary of statistical aggregates, again protecting the confidentiality of our respondents.

This survey has been reviewed and approved by the Social Research Ethics Committee (SREC), University College Cork.

If you agree to participate in the study please proceed to the next page.

There are 22 questions in this survey

Background

[] What is your name? *

Please write your answer here:

[] What is the name of the institution that you work for? *

Please choose **all** that apply:

- ☐Barts and The London School of Medicine and Dentistry
- ☐Cardiff University, School of Dentistry
- ☐King's College London, Dental Institute
- ☐Newcastle University, School of Dental Sciences
- ☐Peninsula Medical and Dental School
- ☐Queen's University Belfast, School of Medicine, Dentistry and Biomedical Sciences
- ☐Trinity College Dublin, School of Dental Science
- ☐University of Aberdeen, School of Medicine and Dentistry
- ☐University of Birmingham, School of Dentistry
- ☐University of Bristol, School of Oral and Dental Sciences
- ☐University of Central Lancashire, College of Clinical and Biomedical Sciences
- ☐University of Dundee, School of Dentistry

- ☐University of Glasgow, Dental School
- ☐University of Leeds, School of Dentistry
- ☐University of Liverpool, School of Dentistry
- ☐University of Manchester, School of Dentistry
- ☐University of Sheffield, The School of Clinical Dentistry

[] What is your current position?Please choose **only one** of the following:

- ○Leading role (Head, Chair, Professor and Director)
- ○Senior teaching position (Senior lecturer, Associate Professor, Senior teaching fellow)
- ○Teaching position (Assistant Professor, Lecturer, teaching fellow and demonstrator)
- ○Others

Make a comment on your choice here:

[] What qualifications do you hold? *

Please choose **only one** of the following:

- ○PhD
- ○Masters
- ○Dental degree
- ○Dental degree and Masters
- ○Dental degree and PhD
- ○Dental degree, Masters and PhD
- ○Others

Make a comment on your choice here:

[] Do you teach full-time or part-time? *

Please choose **only one** of the following:

○Full-time

○Part-time

[] Which group of students do you teach?

Please choose **all** that apply:

☐Dental students

☐Dental nursing students

☐Dental hygiene students

☐Dental technicians

☐Graduate entry dental students

☐Others

Tooth morphology teaching

[] Are you teaching tooth morphology to *

Please choose **only one** of the following:

○Undergraduate students

○Postgraduate students

○Both

[] What type of teaching sessions do you deliver? *

Please choose **only one** of the following:

○Lectures

○Lab practicals

○Lectures and practicals

○Tutorials

○Others

Make a comment on your choice here:

[] How many hours do you lectures (per year)?

Only answer this question if the following conditions are met:
Answer was 'Lectures' *or* 'Lectures and practicals' at question '8 [Q8]' (What type of teaching sessions do you deliver?)

Please choose **only one** of the following:

○0-10

○11-20

○21-30

○31-40

○41-50

○Over 50

[] How many hours do you lecture on Tooth morphology (per year)? *

Please choose **only one** of thefollowing:

○0-10

○11-20

21-30

○31-40

○41-50

○Over 50

Make a comment on your choice here:

[] How many hours are assigned for practicals (per year)?

Please choose **only one** of the following:

○0-10

○11-20

○21-30

○31-40

○41-50

○Over 50

[] How many hours are assigned for tooth morphology practicals (per year)? *

Please choose **only one** of the following:

○0-10

○11-20

○21-30

○31-40

○41-50

○Over 50

Make a comment on your choice here:

[] If you lecture, do you use any of the following in your lectures?

Comment only when you choose an answer.

Please choose all that apply and provide a comment:

☐Videos

☐Powerpoint

☐Animations

☐Models

☐Others

[] Do you offer e-learning?Please choose **only one** of the following:

○Yes ○No

Make a comment on your choice here:

[] If yes, please explain the e-learning options you/your department provide?

Please write your answer here:

[] Do you place lecture notes/supplementary notes online for students?

Please choose **only one** of the following:

○Yes/No

[] Which teaching aids do you use for the tooth morphology practicals?

Comment only when you choose an answer.

Please choose all that apply and provide a comment:

☐Extracted human teeth

☐Plastic teeth

☐Tooth atlas/Computer Assisted Learning (CAL)

☐Wax carving on teeth

☐Tooth drawings exercises

Other:

[] Do you teach *

Please choose **only one** of the following:

○Normal tooth morphology only

○Variations and anomalies of tooth development

○Both

Make a comment on your choice here:

[] For examination and assessment of tooth morphology which of the following do you use:

Comment only when you choose an answer.

Please choose all that apply and provide a comment:

☐Extracted human teeth

☐Plastic teeth

☐Images

☐Online tooth atlas/computer images

☐Others

[] In my experience, it is important for students to learn the 3D aspects of tooth morphology.

Please choose **only one** of the following:

○Strongly agree

○Agree

○Neither agree nor disagree

○Disagree

○Strongly disagree

Make a comment on your choice here:

[] In my experience, tooth morphology is a difficult topic for students.

Please choose **only one** of the following:

○Yes

○No

Make a comment on your choice here:

[] Please use the comment box below to provide feedback (if any). Please write your answer here:

Submit your survey.
Thank you for completing this survey.

Appendix 11

Ethical approval form for tooth morphology teaching survey- SREC, UCC

UCC Social Research Ethics Committee (SREC)

ETHICS APPROVAL FORM

Name of applicant	Dr. André Toulouse 07 October 2015 Date
Contact Details	Phone: (021) 4205477 a.toulouse@ucc.ie Email
Department/Unit	Department of Anatomy and Neuroscience
Title of project	A Survey of the Pedagogies used in Teaching Tooth Morphology in UK and Ireland

		YES	NO
1	Do you consider that this project has significant ethical implications?		x
2	Will you describe the main research procedures to participants in advance, so that they are informed about what to expect?	x	
3	Will participation be voluntary?	x	
4	Will you obtain informed consent in writing from participants?	x	
5		x	
6	Will data be treated with full confidentiality / anonymity (as appropriate)?	x	
7	If results are published, will anonymity be maintained and participants not identified?	x	
8	Will you debrief participants at the end of their participation (i.e. give them a brief explanation of the study)?	x	
9	Will your project involve deliberately misleading participants in any way?		x
10	Will your participants include schoolchildren (under 18 years of age)?		x
11	Will your participants include people with learning or communication difficulties?		x
12	Will your participants include patients?		x
13	Will your participants include people in custody?		x
14	Will your participants include people engaged in illegal activities (e.g. drug taking; illegal Internet behaviour)?		x
15	Is there a realistic risk of participants experiencing either physical or psychological distress?		x
16	If yes to 15, has a proposed procedure, including the name of a contact person, been given? (see no 23)		

DESCRIPTION OF THE PROJECT

17. Aims of the project:
This project aims to assess the various educational pedagogies employed in teaching tooth morphology to the dental students including dental hygiene and dental technicians in various colleges in UK and Ireland. We have designed a short online questionnaire aimed at gathering information from the academic staff involved in teaching this subject with the overall goal of providing students with an additional and innovative learning tool.

18. Brief description and justification of methods and measures to be used (attach copy of questionnaire / interview protocol / discussion guide / etc.)

This study is aimed for the academic staff involved in teaching tooth morphology to the dental students in dental schools in UK and Ireland. The second year dental students and first year dental hygiene students study tooth morphology and the anatomy of each individual tooth. This questionnaire aims to collect data on how tooth morphology is taught to the dental students in UK and Ireland. It will also explore the background and teaching commitments of the academic staff and the use of the different teaching pedagogies utilized to teach tooth morphology.

An online questionnaire was designed to collect data about tooth morphology teaching in Republic of Ireland and the United Kingdom. LimeSurvey was used to design the questionnaire. The questionnaire started with an introduction, followed by questions that were divided into 2 sections.

The introductory page provided a brief description of the questionnaire along with the aim and the benefits of taking part in this study. The questionnaire is made up of 22 questions. The first section has 6 questions and mainly includes questions about the participants' general background and participants teaching experiences. The second section addressed 16 questions about the participants' teaching commitments and teaching modalities used and their opinions on different anatomy pedagogical theories. For the purpose of validating the questionnaire, invitations will be sent to the senior medical demonstrators in the anatomy and neuroscience department in UCC to participate in a trial run. The medical demonstrators will take part in a focus group session to discuss their feedback on the questionnaire.

A list of academic staff teaching tooth morphology in universities located in the Republic of Ireland and the United Kingdom was created by searching through departmental websites and by personal communication.

Emails will be used to send invitation to participants. The invitation emails will include a short description of the research being conducted and a link to the online questionnaire. Invitations will be sent to academic staff within dental schools in the Republic of Ireland and the United Kingdom (Northern Ireland, Wales, Scotland and England). Data will be analysed using Limesurvey statistical package and SPSS statistical package version 22. Detailed statistical analysis will be done and pictorial representation of the results will be generated using Prism.

19. Participants: recruitment methods, number, age, gender, exclusion/inclusion criteria

Participants will be recruited from an academic staff list compiled by accessing the departmental websites and personal communication. Detailed information about the study will be provided. Participation is voluntary and consent will be obtained from the participants. Participants can withdraw at any time following a written demand to Dr. André Toulouse and all data pertaining to their participation will be destroyed.

20. Concise statement of ethical issues raised by the project and how you intend to deal with them

We expect that there will be no ethical issues with this project. The forms will collect information about the participants' names and the colleges they work in. However, this information will be used for communication purpose only and once the data has been collected it will be completely anonymous. The data will be stored securely. It will be entered on a computer secured by a password protected login in a limited access room. Complete anonymity will be ensured throughout for publications.

21. Arrangements for informing participants about the nature of the study (cf. Question 3)

Invitation emails sent to the participants will provide details of the study. Any questions/queries will be addressed by emails, if they arise.

22. How you will obtain Informed Consent - cf. Question 4 (attach relevant form[s])

Informed consent form will be obtained before the start of the study. Participants will be informed that filling the online form indicates their consent for participating in the study. Participants can withdraw within 4 weeks of the start of the study, following a written demand to Dr. André Toulouse and all data pertaining to their participation will be destroyed.

23. Outline of debriefing process (cf. Question 8). If you answered YES to Question 15, give details here. State what you will advise participants to do if they should experience problems (e.g. who to contact for help).

After the completion of the study the participants would be given information about the relevance of the data obtained and its implications to develop a teaching tool. We don't envision any problem or discomfort arising among the participants after filling this questionnaire. However, any questions/queries can be addressed to the following email address: m.lone@ucc.ie.

24. Estimated start date and duration of project.

November 2015 to August 2017.

Signed _____A.Toulouse_____ Date 07.10.15_____

Applicant

Appendix 12

Pre-study questionnaire for tooth morphology quiz app

Pre-assessment questionnaire (tooth morphology)

Personal Information

1. Please write your student number?

2. What is your gender?

- ◯ Female
- ◯ Male

3. Please state your age.

4. Please state your country of origin.

5. What is the highest level of school you have completed or the highest degree you have received?

- ◯ Secondary level qualification or equivalent (e.g., Leaving certificate, A-levels, baccalaureat)
- ◯ Some college but no degree
- ◯ Bachelor degree
- ◯ Graduate degree (Professional)
- ◯ Doctorate (e.g. PhD, D.Phil)
- ◯ Other (please specify)

6. State the subject of the highest degree completed.

1

7. I am studying dentistry via the following route

- ◯ Direct entry dental curriculum
- ◯ Graduate entry dental curriculum
- ◯ Dental hygiene curriculum

8. In a typical weekday, how many hours per day do you access the internet?

9. In a typical weekend, how many hours per day do you access the internet?

10. Please choose all the following that you would use to access the internet?

- ◯ Desktop
- ◯ Laptop
- ◯ Smartphone
- ◯ Tablet/Ipad

11. Please choose as many as applicable. I use the internet for the following activities

- ◯ Education
- ◯ Social media
- ◯ Communication (emails)
- ◯ Communication (What's app/ Viber)
- ◯ Watch TV/movies
- ◯ Online shopping
- ◯ Gaming
- ◯ Instant messaging
- ◯ Information retrieval
- ◯ Other (please specify)

2

12. Do you use the internet mainly for (please rank 3 in the order of frequency used)

- [ ] Education
- [ ] Social media
- [ ] Communication (emails)
- [ ] Communication (What's app/ Viber)
- [ ] Watch TV/movies
- [ ] Online shopping
- [ ] Gaming
- [ ] Instant messaging
- [ ] Information retrieval

Other (please specify)

13. If you use internet for education purpose, would you use:

- ( ) Desktop
- ( ) Laptop
- ( ) Smartphone
- ( ) Tablet/Ipad
- ( ) Not applicable
- ( ) Other (please specify)

14. If you use internet for education purpose, would you use it:

- ( ) At home
- ( ) Friend's house
- ( ) On Campus
- ( ) While commuting
- ( ) Internet cafe
- ( ) Public places (library etc)
- ( ) Other (please specify)

3

15. Would you perform an online search for a new/difficult term/topic?

- ◯ Never
- ◯ Rarely
- ◯ Sometimes
- ◯ Frequently
- ◯ All the time

16. Do you think it is useful to perform an online search for a new/difficult topic?

- ◯ Yes
- ◯ No
- ◯ Don't know

17. While learning a topic, do you prefer:

- ◯ To read text/notes
- ◯ Use an illustrated text
- ◯ Listen to an audio recording
- ◯ Watch a video/animation

18. In your opinion, is audio important to an educational video?

- ◯ Strongly disagree
- ◯ Disagree
- ◯ Niether disagree nor disagree
- ◯ Agree
- ◯ Strongly Agree

19. How confident are you maneuvering / rotating through a 3D image using a laptop / computer?

- ◯ Very uncomfortable
- ◯ Uncomforatble
- ◯ Neither comfortable nor uncomfortable
- ◯ Comfortable
- ◯ Very comfotable
- ◯ Not applicable

4

20. How confident are you maneuvering / rotating through a 3D image using a smartphone?

- ◯ Very uncomfortable
- ◯ Uncomforatble
- ◯ Neither comfortable nor uncomfortable
- ◯ Comfortable
- ◯ Very comfotable
- ◯ Not applicable

21. Have you ever downloaded an educational app on your mobile?

- ◯ No
- ◯ Yes

22. Do you enjoy learning with games?

- ◯ No
- ◯ Yes

23. Would you use online quizzes to test yourself on a particular topic?

- ◯ No
- ◯ Yes
- ◯ Don't know

24. Do you think online quizzes are useful for learning a topic?

- ◯ Yes
- ◯ No
- ◯ Don't know

25. Would you routinely search for online supplementary teaching aids and quizzes available for your topic of interest/ learning.

- ◯ No
- ◯ Yes

5

Appendix 13

Post-study questionnaire for tooth morphology quiz app

Post tooth morphology questionnaire

1. Please write your student number.

2. Please rate the following statements on the scale provided.

	Strongly disagree	Disagree	Neither disagree nor agree	Agree	Strongly agree
The tooth morphology app was easy to use					
The image quality was poor					
3D tooth did not resemble the extracted teeth					
The 3D aspect of the application was easy to understand					
There was distortion in the 3D images					
3D tooth was easy to orient (upper/lower, right/left)					
The app was of good technical quality					
I was able to use the app without assistance					

3. Please rate the following statements on the scale provided.

	Strongly disagree	Disagree	Neither disagree nor agree	Agree	Strongly agree
The app showed the key identifying features of the teeth clearly					
The cusps and grooves on the occlusal surface of the crown were clearly visible					

1

	Strongly disagree	Disagree	Neither disagree nor agree	Agree	Strongly agree
The roots of the teeth were not clearly visible	○	○	○	○	○
The visible features helped me identify the correct teeth	○	○	○	○	○
It was easy to orientate the tooth	○	○	○	○	○
The app improved my confidence in identifying the teeth	○	○	○	○	○
The 3D aspect of the application helped with learning tooth morphology	○	○	○	○	○
The app is a not a useful learning resource	○	○	○	○	○
The app was easy to understand and follow	○	○	○	○	○
The app provided a better learning experience than extracted tooth	○	○	○	○	○
I learned more from manipulating extracted teeth than from the app	○	○	○	○	○
The feedback at the end was very helpful	○	○	○	○	○
The feedback improved my understanding of the tooth morphology	○	○	○	○	○
The feedback provided at the end helped improve my score for my next quiz	○	○	○	○	○
I prefer to hold/visualize the extracted teeth while learning tooth morphology	○	○	○	○	○
I prefer not to look at 3D images of the teeth	○	○	○	○	○
I found this app very confusing as compared to the extracted teeth	○	○	○	○	○

2

4. Please rate the following statements on the scale provided.

	Strongly disagree	Disagree	Neither disagree nor agree	Agree	Strongly agree
I enjoyed using this application	○	○	○	○	○
I don't enjoy self-test quizzes	○	○	○	○	○
I would like to use the quiz again	○	○	○	○	○
I like self-assessment and use quizzes to help me study and test myself	○	○	○	○	○
Quizzes are helpful for self-assessment and understanding of the topic	○	○	○	○	○
I would like to have this app on my laptop	○	○	○	○	○
This app should be available online and accessible at all times	○	○	○	○	○
Did you encounter any technical difficulties while using the application?	○	○	○	○	○

If you encountered technical difficulty please specify.

5. We would value feedback about the app.

3

Appendix 14

Ethical approval form for tooth morphology quiz app- SREC, UCC

ETHICS APPROVAL FORM

Social Research Ethics Committee (SREC)

UCC
University College Cork, Ireland
Coláiste na hOllscoile Corcaigh

Introduction

UCC academic staff and postgraduate research students who are seeking ethical approval should use this approval form. Ethical review by SREC is strongly recommended where the methodology is not clinical or therapeutic in nature and proposes to involve:

- direct interaction with human participants for the purpose of data collection using research methods such as questionnaires, interviews, observations, focus groups etc
- indirect observation with human participant for example using observation, web surveys etc
- access to, or utilisation of, data concerning identifiable individuals.

Application Checklist

This checklist includes all of the items that are required for an application to be deemed complete. In the event that any of these are not present, the application will be returned to the applicant without having been sent to review. Please ensure that your application includes all of these prior to submission. Thank you.

Completed Application Checklist	☐
Completed Ethical Approval Self-Evaluation	☐
Completed Description of Project	☐
Information Sheet(s)	☐
Consent Sheet(s)	☐
Psychometric Instruments / Interview / Focus Group Schedules	☐
I have consulted the UCC *Code of Research Conduct* and believe my proposal is in line with its requirements	☐
If you are under academic supervision, your supervisor has approved the wording of and co-signed this application prior to submission	☐

Please note that you must confirm you have taken account of the University's Code of Research Conduct in order for your application to be considered by SREC

(http://www.ucc.ie/en/media/research/researchatucc/documents/CodeofGoodConductinResearch_000.pdf)

APPLICANT DETAILS

Name of applicant(s)	Dr Mutahira Lone	**Date**	03.10.16
Department/School/Unit, & Supervisor's Name	Department of Anatomy and Neuroscience, Dr. André Toulouse	**Phone**	0214205477
Correspondence Address	Dr André Toulouse, Department of Anatomy and Neuroscience, Western Gateway Building.	**Email**	a.toulouse@ucc.ie
Title of Project	Development and assessment of a tooth morphology application for dental students.		

ETHICAL APPROVAL SELF-EVALUATION

		YES	NO
1	Do you consider that this project has significant ethical implications?		X
2	Will you describe the main research procedures to participants in advance, so that they are informed about what to expect?	X	
3	Will participation be voluntary?	X	
4	Will you obtain informed consent in writing from participants?	X	
5	Will you tell participants that they may withdraw from the research at any time and for any reason, and (where relevant) omit questionnaire items to which they do not wish to respond?	X	
6	Will data be treated with full confidentiality / anonymity (as appropriate)?	X	
7	Will data be securely held for a minimum period of seven years after the completion of a research project, in line with the University's Code of Research Conduct?	X	
8	If results are published, will anonymity be maintained and participants not identified?	X	
9	Will you debrief participants at the end of their participation (i.e. give them a brief explanation of the study)?	X	
10	Will your project involve deliberately misleading participants in any way?		X
11	Will your participants include children (under 18 years of age)?		X
12	Will your participants include people with learning or communication difficulties?		X
13	Will your participants include patients?		X
14	Will your participants include people in custody?		X
15	Will your participants include people engaged in illegal activities (e.g. drug taking; illegal Internet behaviour)?		X

16	Is there a realistic risk of participants experiencing either physical or psychological distress?		X
17	If yes to 16, has a proposed procedure, including the name of a contact person, been given? (see no 25)		X
18	If yes to 11, is your research informed by the UCC Child Protection Policy? http://www.ucc.ie/en/ocla/policy/		X

DESCRIPTION OF THE PROJECT

19. Aims of the project (briefly)

Evaluation of a tooth morphology application for studying tooth morphology by dental students and hygienists.

20. Brief description and justification of methods and measures to be used (attach research questions / copy of questionnaire / interview protocol / discussion guide / etc.)

This study is aimed for the second year dental students and second year hygienists. Once the information about the study has been provided and consent obtained, the participants will be requested to fill a pre-assessment questionnaire about their use of internet and technology. The participants will then access the tooth morphology application during their tooth morphology practicals. The results of these sessions will be evaluated to see the progress of the students. After the practical the paticipants will then complete a post-questionnaire aimed at obtaining information about the quality of the application and educational benefits obtained by the students.

21. Participants: recruitment methods, number, age, gender, exclusion/inclusion criteria, detail permissions

Participants will be recruited from the second year dental students and second year dental hygienists. There will be approximately 60 to 70 students. There will be no recruitment bias based on gender, race or age. Information about the study will be provided. Participation is voluntary and informed consent will be obtained from the participants.

22. Concise statement of ethical issues raised by the project and how you intend to deal with them

We hope there will be no ethical issues with this project. The forms will be anonymous and will be stored securely. The data will be entered on a computer secured by a password protected login in a limited access room. Complete anonymity will be ensured throughout data analysis and for publications.

23. Arrangements for informing participants about the nature of the study (cf. Question 3)

Written information regarding the study will be provided to the participants as part of the consent form. Any questions/queries will be addressed verbally, if they arise.

24. How you will obtain Informed Consent - cf. Question 4 (attach relevant form[s])

Informed consent form will be obtained before the start of the study. Participants will be given an informed consent form to read and sign. A copy of the form will be given to the students for their own records. The consent form will be submitted with this application.

25. Outline of debriefing process (cf. Question 9). If you answered YES to Question 16, give details here. State what you will advise participants to do if they should experience problems (e.g. who to contact for help).
After the completion of the study the participants would be given information about the relevance of the study, the introduction of the teaching pedagogy and its relevance. We don't envision any problem or discomfort arising among the participants after watching this video. However, any questions/queries can be addressed to the following email address: m.lone@ucc.ie

26. Estimated start date and duration of project

October 2016 to October 2019.

Signed _____M.Lone_____ Date ___06.10.16_____
Applicant

Signed _____A.Toulouse_____ Date _____06.10.16_____
Research Supervisor/Principal Investigator (if applicable)

Notes

1. Please submit this form and any attachments to srec@ucc.ie (including **a scanned signed copy**).
No hard copies are required.

2. Research proposals can receive only provisional approval from SREC in the absence of approval from any agency where you intend to recruit participants. If you have already secured the relevant consent, please enclose a copy with this form.

3. SREC is not primarily concerned with methodological issues but may comment on such issues in so far as they have ethical implications.

This form is adapted from pp. 13-14 of Guidelines for Minimum Standards of Ethical Approval in Psychological Research (British Psychological Society, July, 2004)

Last update: September 2015

Appendix 15

Student consent form for the tooth morphology quiz app

Department of Anatomy and Neurosicence, UCC

Project information for research participants

Evaluation of a tooth morphology application for teaching tooth morphology to the dental student.

Investigators: Dr. André Toulouse, Dr. Eric Downer, Tamara Vagg, Dr. Antonios Theocharopoulos, Dr. Joe McKenna, Prof. John Cryan, Dr. Mutahira Lone.

Study Location: Department of Anatomy and Neuroscience, University College Cork, Cork, Ireland.

Purpose of the Study: This study aims to assess the validity and usefulness of a tooth morphology application for teaching tooth morphology, at University College Cork (UCC).

What will the study involve? The study will involve answering 2 questionnaires and working on an application. There are 25 questions in the first questionnaire which takes approximately 10 – 15 minutes to complete. You will be requested to fill it in the lecture room and return it to us. At a later stage you will be using a tooth morphology app designed for this project. At the end of the project you will be asked to fill another questionnaire with 5 questions and should take approximately 15-20 minutes to complete.

Why have you been asked to take part? You have been asked to participate because the overall aim of our research project is to introduce innovative teaching pedagogies in anatomy for dental students and dental hygienists at UCC. Your participation allows us to gauge the development of a new study tool and assess its usefulness for future incorporation in class material.

Do you have to take part? Your participation is entirely voluntary and we greatly value your input. Whether you participate or not, will not influence your grades or performance evaluations. To indicate that you are willing to participate, you are asked to sign the attached consent form.

The questionnaires used during the study will be partly anonymised, only student numbers will be collected for statistical analysis of group performance. All data will be stored securely and retained up to seven years after the completion of the study at which time it will be destroyed.

The overall analysis of the results will be presented in Dr Lone's PhD thesis and may also be published in a research journal. While student numbers will be used for initial data analysis, they will not be used past that stage and anonymity will be ensured in publications.

Any questions or queries will be addressed by contacting the investigators. Participants can withdraw within 2 weeks from the start of the study, following a written demand to Dr. André Toulouse (a.toulouse@ucc.ie) and all data pertaining to their participation will be destroyed.

If you need any further information, you can contact the researcher, Dr. Mutahira Lone (m.lone@ucc.ie).

This study has been reviewed and approved by the Social Research Ethics Committee at University College Cork.

If you agree to take part in the study, please sign the consent form overleaf.

We would like to sincerely thank you for your participation in this study.

DEPARTMENT OF ANATOMY & NEUROSCIENCE
UNIVERSITY COLLEGE CORK

Consent Form

Evaluation of a tooth morphology application for teaching tooth morphology to the dental student.

1. I…… (BLOCK PRINT) agree to participate in this research study.

2. The purpose and nature of the study has been explained to me in writing.

3. I am participating voluntarily.

4. I give permission for my data to be used for further analysis and research

5. I understand that my participation will not affect in anyway my grades/examination performance.

6. I understand that anonymity will be ensured in the research process.

Signed……. Date…….

RS Ver 6 2/11/07

Appendix 16

Pilot feedback form for cranial nerve animation

Feedback form for cranial nerve animation

	Strongly disagree	Disagree	Neither agree nor disagree	Agree	Strongly agree
Cranial nerves are a difficult topic to visualize and remember.					
This exercise helped improve your knowledge/understanding of the cranial nerve.					
This animation improved your understanding of the functions of the cranial nerves.					
This animation improved your knowledge about the pathway of the cranial nerves.					
The animation was easy to understand.					
The pace of the animation was easy to follow.					
This animation motivates you to learn more about the cranial nerves.					
Animation can aid the teaching of dental anatomy.					
This animation should be placed on blackboard as a supplemental aid.					
This animation would offer a better 3D understanding of the cranial nerves compared to other neuroanatomy resources.					
I feel that my dental anatomy knowledge will benefit from integration of the animation.					

Please use the space below to provide any feedback regarding the animation.

Thank you for your feedback

Appendix 17

Pilot feedback form for tooth morphology quiz application

USING THE APP					
Have you used any other apps like this?	Y	N			
How does this app compare to the other apps? 1-5 where 1=less useful, 5= very useful	1	2	3	4	5
Rate the crown features (distinguishing features)? 1-5 where 1=less useful, 5= very useful	1	2	3	4	5
Were the root features clear to see? 1-5 where 1=less useful, 5= very useful	1	2	3	4	5
Can you recognize the teeth clearly?	Y	N			
Is the 3D image of the tooth realistic?	Y	N			
Does the app convey 3D feature of the tooth clearly?	Y	N			
Did the 3D interface allow suitable orientation of the 3D image?	Y	N			
Were the teeth difficult to identify in the app?	Y	N			
Were the quadrants clear to see?	Y	N			
Was it easy to place the teeth in the quadrants?	Y	N			
On a scale of 1-5 please rate your usability experience? 1=easy to 5=difficult	1	2	3	4	5
FEEDBACK					
Do you think the app would be a good learning tool	Y	N			
If no, please explain your answer.					
Was the colour contrast appropriate?	Y	N			
Did you enjoy using the app?	Y	N			
Is scoring at the end of benefit?	Y	N			
Is the feedback appropriate?	Y	N			
Is the feedback helpful?	Y	N			
QUALITATIVE QUESTIONS					
Would you use an app like this?	Y	N			
Was this a positive or a negative experience?	Positive	Negative			
Is there any change that you would recommend or any feedback that you have:					

REFERENCES

Abu Eid, R., Ewan, K., Foley, J., Oweis, Y. and Jayasinghe, J. (2013) 'Self-directed study and carving tooth models for learning tooth morphology: perceptions of students at the University of Aberdeen, Scotland', *Journal of dental education,* 77(9), pp. 1147-1153.

ADEE (2016) *SIGT-02: 'Biomedical Sciences in Dentistry: Developing a Contemporary Core Curriculum'*, Association for Dental Education in Europe (Outcome of ADEE SIG's 2013-2016) (Accessed: 01.06.17).

Ainsworth, S. and Vanlabeke, N. (2004) 'Multiple forms of dynamic representation. ', *Learn Instruct* 14, pp. 241-255.

Allen, L. K., Bhattacharyya, S. and Wilson, T. D. (2015) 'Development of an interactive anatomical three-dimensional eye model', *Anatomical sciences education,* 8(3), pp. 275-282.

Allen, L. K., Eagleson, R. and de Ribaupierre, S. (2016) 'Evaluation of an online three-dimensional interactive resource for undergraduate neuroanatomy education', *Anatomical sciences education,* 9(5), pp. 431-439.

Amer, R. S., Denehy, G. E., Cobb, D. S., Dawson, D. V., Cunningham-Ford, M. A. and Bergeron, C. (2011) 'Development and evaluation of an interactive dental video game to teach dentin bonding', *Journal of dental education,* 75(6), pp. 823-831.

Amin, M., Zulla, R., Gaudet-Amigo, G., Patterson, S., Murphy, N. and Ross, S. (2017) 'Dental Students' Perceptions of Learning Value in PBL Groups with Medical and Dental Students Together versus Dental Students Alone', *Journal of dental education,* 81(1), pp. 65-74.

Anderhuber, F. (1996) 'The concept of anatomy--classical topographic anatomy', *Surgical and radiologic anatomy : SRA,* 18(4), pp. 253-256.

Arnett, M. R., Loewen, J. M. and Romito, L. M. (2013) 'Use of social media by dental educators', *Journal of dental education,* 77(11), pp. 1402-1412.

Azer, S. A. (2012) 'Can "YouTube" help students in learning surface anatomy?', *Surgical and radiologic anatomy : SRA,* 34(5), pp. 465-468.

Aziz, M. A., McKenzie, J. C., Wilson, J. S., Cowie, R. J., Ayeni, S. A. and Dunn, B. K. (2002) 'The human cadaver in the age of biomedical informatics', *The Anatomical record,* 269(1), pp. 20-32.

Bacro, T. R., Gebregziabher, M. and Ariail, J. (2013) 'Lecture recording system in anatomy: possible benefit to auditory learners', *Anatomical sciences education,* 6(6), pp. 376-384.

Baghdady, M. T., Carnahan, H., Lam, E. W. and Woods, N. N. (2014) 'Dental and dental hygiene students' diagnostic accuracy in oral radiology: effect of diagnostic strategy and instructional method', *Journal of dental education,* 78(9), pp. 1279-1285.

Baker, E. W., Slott, P. A., Terracio, L. and Cunningham, E. P. (2013) 'An innovative method for teaching anatomy in the predoctoral dental curriculum', *Journal of dental education,* 77(11), pp. 1498-1507.

Bakr, M. M., Thompson, C. M. and Massadiq, M. (2016) 'Anatomical sciences: A foundation for a solid learning experience in dental technology and dental prosthetics', *Anatomical sciences education,* Advance online publication doi:10.1002/ase.1650.

Balta, J. Y., Cronin, M., Cryan, J. F. and O'Mahony, S. M. (2015) 'Human preservation techniques in anatomy: A 21st century medical education perspective', *Clinical anatomy (New York, N.Y.),* 28(6), pp. 725-734.

Bassir, S. H., Sadr-Eshkevari, P., Amirikhorheh, S. and Karimbux, N. Y. (2014) 'Problem-based learning in dental education: a systematic review of the literature', *Journal of dental education,* 78(1), pp. 98-109.

Bell, M. D. (2006) 'The UK Human Tissue Act and consent: surrendering a fundamental principle to transplantation needs?', *Journal of medical ethics,* 32(5), pp. 283-286.

Bernabe, E. and Sheiham, A. (2014) 'Tooth loss in the United Kingdom--trends in social inequalities: an age-period-and-cohort analysis', *PloS one,* 9(8), pp. e104808.

Bernardini, J. and Davis, D. J. (2014) 'Evaluation of a computer-guided curriculum using animation, visual images, and voice cues to train patients for peritoneal dialysis', *Peritoneal dialysis international : journal of the International Society for Peritoneal Dialysis,* 34(1), pp. 79-84.

Best, L., Walton, J. N., Walker, J. and von Bergmann, H. (2016) 'Reaching Consensus on Essential Biomedical Science Learning Objectives in a Dental Curriculum', *Journal of dental education,* 80(4), pp. 422-429.

Bodemer, D., Ploetzner, R., Feuerlein, I. and Spada, H. (2004) 'The active integration of information during learning with dynamic and interactive visualisations', *Learning and Instruction,* 14(3), pp. 325-341.

Bogacki, R. E., Best, A. and Abbey, L. M. (2004) 'Equivalence study of a dental anatomy computer-assisted learning program', *Journal of dental education,* 68(8), pp. 867-871.

Bohl, M., Bosch, P. and Hildebrandt, S. (2011) 'Medical students' perceptions of the body donor as a "first patient" or "teacher": a pilot study', *Anatomical sciences education,* 4(4), pp. 208-213.

Bolek, B. (2006) 'Facing cranial nerve assessment', *Am Nurse Today,* 1, pp. 21-22.

Bosslet, G. T. (2011) 'Commentary: the good, the bad, and the ugly of social media', *Academic emergency medicine : official journal of the Society for Academic Emergency Medicine,* 18(11), pp. 1221-1222.

Boushell, L. W. and Sturdevant, J. R. (2012) *Clinical significance of dental anatomy, histology, physiology, and occlusion. Sturdevant's Art and Science of Operative Dentistry* 6th edn. Missouri: Elsevier.

Brennan, D. S. and Spencer, A. J. (2005) 'The role of dentist, practice and patient factors in the provision of dental services', *Community dentistry and oral epidemiology,* 33(3), pp. 181-195.

Brenner, E. (2014) 'Human body preservation - old and new techniques', *Journal of anatomy,* 224(3), pp. 316-344.

Brisbourne, M. A., Chin, S. S., Melnyk, E. and Begg, D. A. (2002) 'Using web-based animations to teach histology', *The Anatomical record,* 269(1), pp. 11-19.

Bryner, B. S., Saddawi-Konefka, D. and Gest, T. R. (2008) 'The impact of interactive, computerized educational modules on preclinical medical education', *Anatomical sciences education,* 1(6), pp. 247-251.

Burk, D. T., Lee, L. M. and Lambert, H. W. (2013) 'Embryology and histology education in North American dental schools: the Basic Science Survey Series', *Journal of dental education,* 77(6), pp. 744-756.

Cantín, M., Muñoz, M. and Olate, S. (2015) 'Generation of 3D tooth models based on three-dimensional scanning to study the morphology of permanent teeth', *International Journal of Morphology,* 33(2), pp. 782-787.

Carmichael, S. W. and Pawlina, W. (2000) 'Animated PowerPoint as a tool to teach anatomy', *The Anatomical record,* 261(2), pp. 83-88.

Clark, J. (2008) 'PowerPoint and pedagogy: Maintaining student interest in university lectures', *College Teaching,* 56(1), pp. 39-44.

Cleeren, G., Quirynen, M., Ozcelik, O. and Teughels, W. (2014) 'Role of 3D animation in periodontal patient education: a randomized controlled trial', *Journal of clinical periodontology,* 41(1), pp. 38-45.

Crawford, J. M., Adami, G., Johnson, B. R., Knight, G. W., Knoernschild, K., Obrez, A., Patston, P. A., Punwani, I., Zaki, A. M. and Licari, F. W. (2007) 'Curriculum restructuring at a North American dental school: rationale for change', *Journal of dental education,* 71(4), pp. 524-531.

Curnier, F. (2010) 'Teaching dentistry by means of virtual reality--the Geneva project', *International journal of computerized dentistry,* 13(3), pp. 251-263.

de Azevedo Rde, A., da Rosa, W. L., da Silva, A. F., Correa, M. B., Torriani, M. A. and Lund, R. G. (2015) 'Comparative Effectiveness of Dental Anatomy Carving Pedagogy: A Systematic Review', *Journal of dental education,* 79(8), pp. 914-921.

de Boer, I. R., Lagerweij, M. D., Wesselink, P. R. and Vervoorn, J. M. (2015) 'Evaluation of the appreciation of virtual teeth with and without pathology',

European journal of dental education : official journal of the Association for Dental Education in Europe, 19(2), pp. 87-94.

Dickson, K. A. and Stephens, B. W. (2015) 'It's all in the mime: Actions speak louder than words when teaching the cranial nerves', *Anatomical sciences education,* 8(6), pp. 584-592.

Dietrich, T., Walter, C., Oluwagbemigun, K., Bergmann, M., Pischon, T., Pischon, N. and Boeing, H. (2015) 'Smoking, Smoking Cessation, and Risk of Tooth Loss: The EPIC-Potsdam Study', *Journal of dental research,* 94(10), pp. 1369-1375.

Douglas, R. D., Hopp, C. D. and Augustin, M. A. (2014) 'Dental students' preferences and performance in crown design: conventional wax-added versus CAD', *Journal of dental education,* 78(12), pp. 1663-1672.

Drake, R. L., McBride, J. M., Lachman, N. and Pawlina, W. (2009) 'Medical education in the anatomical sciences: the winds of change continue to blow', *Anatomical sciences education,* 2(6), pp. 253-259.

Drake, R. L. and Pawlina, W. (2014) 'Multimodal education in anatomy: The perfect opportunity', *Anatomical sciences education,* 7(1), pp. 1-2.

Dudlicek, L. L., Gettig, E. A., Etzel, K. R. and Hart, T. C. (2004) 'Status of genetics education in U.S. dental schools', *Journal of dental education,* 68(8), pp. 809-818.

Dyer, G. S. and Thorndike, M. E. (2000) 'Quidne mortui vivos docent? The evolving purpose of human dissection in medical education', *Academic medicine : journal of the Association of American Medical Colleges,* 75(10), pp. 969-979.

Eisma, R., Lamb, C. and Soames, R. W. (2013) 'From formalin to Thiel embalming: What changes? One anatomy department's experiences', *Clinical anatomy,* 26(5), pp. 564-571.

El Tantawi, M. M., Abdelsalam, M. M., Mourady, A. M. and Elrifae, I. M. (2015) 'e-Assessment in a Limited-Resources Dental School Using an Open-Source Learning Management System', *Journal of dental education,* 79(5), pp. 571-583.

El Tantawi, M. M., El Kashlan, M. K. and Saeed, Y. M. (2013) 'Assessment of the efficacy of second life, a virtual learning environment, in dental education', *Journal of dental education,* 77(12), pp. 1639-1652.

Elangovan, S., Venugopalan, S. R., Srinivasan, S., Karimbux, N. Y., Weistroffer, P. and Allareddy, V. (2016) 'Integration of Basic-Clinical Sciences, PBL, CBL, and IPE in U.S. Dental Schools' Curricula and a Proposed Integrated Curriculum Model for the Future', *Journal of dental education,* 80(3), pp. 281-290.

Evans, J. L., Henderson, A. and Johnson, N. W. (2013) 'Traditional and interprofessional curricula for dental technology: perceptions of students in two programs in Australia', *Journal of dental education,* 77(9), pp. 1225-1236.

Faisal, M., Ahmad, S. A. and Ansari, U. (2015) 'Information and Communication Technology in Dental Education: Benefits and Drawbacks', *International J. of Multidisciplinary Approach and Studies,* 2(2), pp. 147-155.

Farnan, J., Paro, J. A., Higa, J., Edelson, J. and Arora, V. M. (2008) 'The YouTube generation: implications for medical professionalism', *Perspectives in biology and medicine,* 51(4), pp. 517-524.

Fehrenbach, M. J. (2016) *Illustrated Dental Embryology, Histology, and Anatomy - E-Book.* Elsevier Health Sciences.

Field, M. J. and Jeffcoat, M. K. (1995) 'Dental education at the crossroads: a report by the Institute of Medicine', *Journal of the American Dental Association (1939),* 126(2), pp. 191-195.

Fung, A., Kelly, P., Tait, G., Greig, P. D. and McGilvray, I. D. (2016) 'Creating an animation-enhanced video library of hepato-pancreato-biliary and transplantation surgical procedures', *Journal of visual communication in medicine,* 39(1-2), pp. 27-32.

Gadbury-Amyot, C. C., Singh, A. H. and Overman, P. R. (2013) 'Teaching with technology: learning outcomes for a combined dental and dental hygiene online hybrid oral histology course', *Journal of dental education,* 77(6), pp. 732-743.

Garrett, P. H., Faraone, K. L., Patzelt, S. B. and Keaser, M. L. (2015) 'Comparison of Dental Students' Self-Directed, Faculty, and Software-Based Assessments of Dental Anatomy Wax-Ups: A Retrospective Study', *Journal of dental education,* 79(12), pp. 1437-1444.

Glittenberg, C. and Binder, S. (2006) 'Using 3D computer simulations to enhance ophthalmic training', *Ophthalmic & physiological optics : the journal of the British College of Ophthalmic Opticians (Optometrists),* 26(1), pp. 40-49.

Goldman, E. (2010) 'Building a low-cost gross anatomy laboratory: a big step for a small university', *Anatomical sciences education,* 3(4), pp. 195-201.

Gonzalez, S. M. and Gadbury-Amyot, C. C. (2016) 'Using Twitter for Teaching and Learning in an Oral and Maxillofacial Radiology Course', *Journal of dental education,* 80(2), pp. 149-155.

Gould, D. J., Clarkson, M. J., Hutchins, B. and Lambert, H. W. (2014) 'How neuroscience is taught to North American dental students: results of the Basic Science Survey Series', *Journal of dental education,* 78(3), pp. 437-444.

Grohmann, I., Raith, S., Kesting, M., Rau, A., Mucke, T., Lethaus, B., Holzle, F. and Steiner, T. (2013) 'Experimental biomechanical study of the primary stability of different osteosynthesis systems for mandibular reconstruction with an iliac crest graft', *The British journal of oral & maxillofacial surgery,* 51(8), pp. 942-947.

Guillot, A., Champely, S., Batier, C., Thiriet, P. and Collet, C. (2007) 'Relationship between spatial abilities, mental rotation and functional anatomy learning', *Advances in health sciences education : theory and practice,* 12(4), pp. 491-507.

Guo, Y., Logan, H. L., Dodd, V. J., Muller, K. E., Marks, J. G. and Riley, J. L., 3rd (2014) 'Health literacy: a pathway to better oral health', *American journal of public health,* 104(7), pp. e85-91.

Guttmann, G. D. (2000) 'Animating functional anatomy for the web', *The Anatomical record,* 261(2), pp. 57-63.

Guttmann, G. D. (2003) 'The current status of the anatomical sciences curriculum in U.S. and Canadian dental schools', *Journal of dental education,* 67(3), pp. 375-379.

Guttmann, G. D., Ma, T. P. and MacPherson, B. R. (2003) 'Making gross anatomy relevant to dental students', *Journal of dental education,* 67(3), pp. 355-358.

Hammer, N., Loffler, S., Bechmann, I., Steinke, H., Hadrich, C. and Feja, C. (2015) 'Comparison of modified Thiel embalming and ethanol-glycerin fixation in an anatomy environment: Potentials and limitations of two complementary techniques', *Anatomical sciences education,* 8(1), pp. 74-85.

Hammer, N., Loffler, S., Feja, C., Sandrock, M., Schmidt, W., Bechmann, I. and Steinke, H. (2012) 'Ethanol-glycerin fixation with thymol conservation: a potential alternative to formaldehyde and phenol embalming', *Anatomical sciences education,* 5(4), pp. 225-233.

Hanson, C. (2011) 'Teaching extractions is no longer a pain', *Scottish Dental Magazine,* pp. 69-72.

Hanson, C., Wilkinson, T. and Macluskey, M. (2016) 'Do dental undergraduates think that Thiel-embalmed cadavers are a more realistic model for teaching exodontia?', *European journal of dental education : official journal of the Association for Dental Education in Europe,* Advance online publication doi:DOI: 10.1111/eje.12250.

Hayashi, S., Naito, M., Kawata, S., Qu, N., Hatayama, N., Hirai, S. and Itoh, M. (2016) 'History and future of human cadaver preservation for surgical training: from formalin to saturated salt solution method', *Anatomical science international,* 91(1), pp. 1-7.

Hendricson, W. D. (2012) 'Changes in educational methodologies in predoctoral dental education: finding the perfect intersection', *Journal of dental education,* 76(1), pp. 118-141.

Heylings, D. J. (2002) 'Anatomy 1999-2000: the curriculum, who teaches it and how?', *Medical education,* 36(8), pp. 702-710.

Hisley, K. C., Anderson, L. D., Smith, S. E., Kavic, S. M. and Tracy, J. K. (2008) 'Coupled physical and digital cadaver dissection followed by a visual test protocol provides insights into the nature of anatomical knowledge and its evaluation', *Anatomical sciences education,* 1(1), pp. 27-40.

Holzle, F., Franz, E. P., Lehmbrock, J., Weihe, S., Teistra, C., Deppe, H. and Wolff, K. D. (2012) 'Thiel embalming technique: a valuable method for teaching oral

surgery and implantology', *Clinical implant dentistry and related research,* 14(1), pp. 121-126.

Houck, W. A., Soares-Welch, C. V., Montori, V. M. and Li, J. T. (2002) 'Learning the thyroid examination--a multimodality intervention for internal medicine residents', *Teaching and learning in medicine,* 14(1), pp. 24-28.

Hoyek, N., Collet, C., Di Rienzo, F., De Almeida, M. and Guillot, A. (2014) 'Effectiveness of three-dimensional digital animation in teaching human anatomy in an authentic classroom context', *Anatomical sciences education,* 7(6), pp. 430-437.

Hoyek, N., Collet, C., Rastello, O., Fargier, P., Thiriet, P. and Guillot, A. (2009) 'Enhancement of mental rotation abilities and its effect on anatomy learning', *Teaching and learning in medicine,* 21(3), pp. 201-206.

Hwang, I., Tam, M., Lam, S. L. and Lam, P. (2012) 'Review of Use of Animation as a Supplementary Learning Material of Physiology Content in Four Academic Years', *Electronic Journal of e-Learning,* 10(4), pp. 368-377.

Ivanusic, J., Cowie, B. and Barrington, M. (2010) 'Undergraduate student perceptions of the use of ultrasonography in the study of "living anatomy"', *Anatomical sciences education,* 3(6), pp. 318-322.

Jackson, T. H., Hannum, W. H., Koroluk, L. and Proffit, W. R. (2011) 'Effectiveness of web-based teaching modules: test-enhanced learning in dental education', *Journal of dental education,* 75(6), pp. 775-781.

Jastrow, H. and Hollinderbaumer, A. (2004) 'On the use and value of new media and how medical students assess their effectiveness in learning anatomy', *Anatomical record. Part B, New anatomist,* 280(1), pp. 20-29.

Johnson, E. O., Charchanti, A. V. and Troupis, T. G. (2012) 'Modernization of an anatomy class: From conceptualization to implementation. A case for integrated multimodal-multidisciplinary teaching', *Anatomical sciences education,* 5(6), pp. 354-366.

Johnson, S., Purkiss, J., Holaday, L., Selvig, D. and Hortsch, M. (2015) 'Learning histology - dental and medical students' study strategies', *European journal of dental education : official journal of the Association for Dental Education in Europe,* 19(2), pp. 65-73.

Kakizawa, Y., Hongo, K. and Rhoton, A. L., Jr. (2007) 'Construction of a three-dimensional interactive model of the skull base and cranial nerves', *Neurosurgery,* 60(5), pp. 901-910; discussion 901-910.

Kassebaum, D. K., Hendricson, W. D., Taft, T. and Haden, N. K. (2004) 'The dental curriculum at North American dental institutions in 2002-03: a survey of current structure, recent innovations, and planned changes', *Journal of dental education,* 68(9), pp. 914-931.

Kassebaum, N. J., Bernabe, E., Dahiya, M., Bhandari, B., Murray, C. J. and Marcenes, W. (2014) 'Global Burden of Severe Tooth Loss: A Systematic Review and Meta-analysis', *Journal of dental research,* 93(7 Suppl), pp. 20s-28s.

Kato, A. and Ohno, N. (2009) 'Construction of three-dimensional tooth model by micro-computed tomography and application for data sharing', *Clinical oral investigations,* 13(1), pp. 43-46.

Keedy, A. W., Durack, J. C., Sandhu, P., Chen, E. M., O'Sullivan, P. S. and Breiman, R. S. (2011) 'Comparison of traditional methods with 3D computer models in the instruction of hepatobiliary anatomy', *Anatomical sciences education,* 4(2), pp. 84-91.

Kesner, M. H. and Linzey, A. V. (2005a) 'Can Computer-Based Visual-Spatial Aids Lead to Increased Student Performance in Anatomy & Physiology?', *The American Biology Teacher,* 67(4), pp. 206-212.

Kesner, M. H. and Linzey, A. V. (2005b) 'Can Computer-Based Visual-Spatial Aids Lead to Increased Student Performance in Anatomy & Physiology?', *Am Biol Teach,* 67(4), pp. 206-212.

Khatoon, B., Hill, K. B. and Walmsley, A. D. (2013) 'Can we learn, teach and practise dentistry anywhere, anytime?', *British dental journal,* 215(7), pp. 345-347.

Khatoon, B., Hill, K. B. and Walmsley, A. D. (2014) 'Dental students' uptake of mobile technologies', *British dental journal,* 216(12), pp. 669-673.

Kieser, J., Livingstone, V. and Meldrum, A. (2008) 'Professional storytelling in clinical dental anatomy teaching', *Anatomical sciences education,* 1(2), pp. 84-89.

Kilistoff, A. J., Mackenzie, L., D'Eon, M. and Trinder, K. (2013) 'Efficacy of a step-by-step carving technique for dental students', *Journal of dental education,* 77(1), pp. 63-67.

Kiviniemi, M. T. (2014) 'Effects of a blended learning approach on student outcomes in a graduate-level public health course', *BMC medical education,* 14, pp. 47.

Klueber, K. M. (2003) 'Neuroanatomy for the dentist in the twenty-first century', *Journal of dental education,* 67(3), pp. 366-369.

Knosel, M., Jung, K. and Bleckmann, A. (2011) 'YouTube, dentistry, and dental education', *Journal of dental education,* 75(12), pp. 1558-1568.

Kondrashova, T., De Wan, D., Briones, M. U. and Kondrashov, P. (2016) 'Integration of ultrasound imaging into pre-clinical dental education', *European journal of dental education : official journal of the Association for Dental Education in Europe*.

Kuhl, S., Kirmeier, R., Platzer, S., Bianco, N., Jakse, N. and Payer, M. (2016) 'Transcrestal maxillary sinus augmentation: Summers' versus a piezoelectric technique--an experimental cadaver study', *Clinical oral implants research,* 27(1), pp. 126-129.

Lam, M. T., Kwon, S. R., Qian, F. and Denehy, G. E. (2015) 'Evaluation of an Innovative Digital Assessment Tool in Dental Anatomy', *The journal of contemporary dental practice,* 16(5), pp. 366-371.

Latorre, R., Bainbridge, D., Tavernor, A. and Lopez Albors, O. (2016) 'Plastination in Anatomy Learning: An Experience at Cambridge University', *Journal of veterinary medical education,* 43(3), pp. 226-234.

Lin, S. C., Hsu, J. and Fan, V. Y. (2009) '"Silent virtuous teachers": anatomical dissection in Taiwan', *BMJ (Clinical research ed.),* 339, pp. b5001.

Lone, M., Vagg, T., Theocharopoulos, A., Cryan, J. F., Downer, E. J., McKenna, J. P. and Toulouse, A. (2017) 'Development of an online tooth morphology 3D quiz to enhance dental student learning'. *11th annual International Technology, Education and Development Conference,* 6-8 March. Valencia, Spain: IATED, 6153-6160.

Lowe, R. (2004a) 'Interrogation of a dynamic visualization during learning', *Learn Intr,* 14(3), pp. 257-274.

Lowe, R. (2004b) 'Interrogation of a dynamic visualization during learning', *Learning and Instruction,* 14(3), pp. 257-274.

Macluskey, M., Durham, J., Bell, A., Cowpe, J., Crean, S. J., Dargue, A., Dawson, L., Freeman, C., Jones, J., McDouagh, A., McHanwell, S., Marley, J., Myrddin, L., Millsopp, L., Oliver, R., Renton, T., Taylor, K. and Thomson, P. (2012) 'A national survey of UK final year students' opinion of undergraduate oral surgery teaching', *European journal of dental education : official journal of the Association for Dental Education in Europe,* 16(1), pp. e205-212.

MacPherson, B. R. and Brueckner, J. K. (2003) 'Enhancing the dental histology curriculum using computer technology', *Journal of dental education,* 67(3), pp. 359-365.

Maggio, M. P., Hariton-Gross, K. and Gluch, J. (2012) 'The use of independent, interactive media for education in dental morphology', *Journal of dental education,* 76(11), pp. 1497-1511.

Magne, P. (2015) 'A new approach to the learning of dental morphology, function, and esthetics: the "2D-3D-4D" concept', *The international journal of esthetic dentistry,* 10(1), pp. 32-47.

Manogue, M., McLoughlin, J., Christersson, C., Delap, E., Lindh, C., Schoonheim-Klein, M. and Plasschaert, A. (2011) 'Curriculum structure, content, learning and assessment in European undergraduate dental education - update 2010', *European journal of dental education : official journal of the Association for Dental Education in Europe,* 15(3), pp. 133-141.

Massey, N. D., Galil, K. A. and Wilson, T. D. (2013) 'Determining position of the inferior alveolar nerve via anatomical dissection and micro-computed tomography in preparation for dental implants', *Journal (Canadian Dental Association),* 79, pp. d39.

Mayer, R. E. (2002a) *Multimedia learning. Psychology of learning and motivation* Cambridge, MA: Academic Press.

Mayer, R. E. (2002b) 'Multimedia learning', in Brian, H.R. (ed.) *Psychology of Learning and Motivation*: Academic Press, pp. 85-139.

Mayer, R. E. and Moreno, R. (1998) 'A cognitive theory of multimedia learning: Implications for design principles', *Journal of Educational Psychology,* 91(2), pp. 358-368.

McAndrew, M. and Johnston, A. E. (2012) 'The role of social media in dental education', *Journal of dental education,* 76(11), pp. 1474-1481.

McCaul, L. K., Jenkins, W. M. and Kay, E. J. (2001) 'The reasons for extraction of permanent teeth in Scotland: a 15-year follow-up study', *British dental journal,* 190(12), pp. 658-662.

McClea, K. (2008) 'The Bequest Programme at the University of Otago: cadavers donated for clinical anatomy teaching', *The New Zealand medical journal,* 121(1274), pp. 72-78.

McHanwell, S. (2015) 'Teaching anatomical sciences to dental students', in Chan, L.K. & Pawlina, W. (eds.) *Teaching Anatomy: A Practical Guide.* 1st ed. New York, NY: Springer International., pp. 353-361.

McHanwell, S., Atkinson, M., Davies, C., Dyball, R., Morris, J., Ockleford, C., Parkin, I., Whiten, S. and Wilton, J. (2007) 'Adding ‘common sense’to ‘the need to know’in anatomy teaching', *Journal of anatomy,* 210(5), pp. 615-616.

McHarg, J. and Kay, E. J. (2008) 'The anatomy of a new dental curriculum', *British dental journal,* 204(11), pp. 635-638.

McLachlan, J. C., Bligh, J., Bradley, P. and Searle, J. (2004) 'Teaching anatomy without cadavers', *Medical education,* 38(4), pp. 418-424.

McLaughlin, J. E., Gharkholonarehe, N., Khanova, J., Deyo, Z. M. and Rodgers, J. E. (2015) 'The Impact of Blended Learning on Student Performance in a Cardiovascular Pharmacotherapy Course', *American Journal of Pharmaceutical Education,* 79(2), pp. 24-30.

Meacham, R. K., Boughter, J. D., Jr. and Sebelik, M. E. (2012) 'Ultrasound-guided fine-needle aspiration of the tongue base: a cadaver feasibility study', *Otolaryngology--head and neck surgery : official journal of American Academy of Otolaryngology-Head and Neck Surgery,* 147(5), pp. 864-869.

MedicalCouncil (2017) *Anatomy Responsibilities*. Available at: https://www.medicalcouncil.ie/Public-Information/Anatomy-Responsibilities/ (Accessed: 05.07.17 2017).

Mehrabi, A., Gluckstein, C., Benner, A., Hashemi, B., Herfarth, C. and Kallinowski, F. (2000) 'A new way for surgical education--development and evaluation of a

computer-based training module', *Computers in biology and medicine,* 30(2), pp. 97-109.

Mitov, G., Dillschneider, T., Abed, M. R., Hohenberg, G. and Pospiech, P. (2010) 'Introducing and evaluating MorphoDent, a Web-based learning program in dental morphology', *Journal of dental education,* 74(10), pp. 1133-1139.

Moreno, R. and Mayer, R. E. (1999) 'Cognitive principles of multimedia learning: The role of modality and contiguity', *Journal of educational psychology,* 91(2), pp. 358-368.

Morris, J. F. and Chirculescu, A. R. M. (2007) 'Structure and assessment of a short intense clinical anatomy course shortly before clinical studies', *Eur J Anat,* 11, pp. 95-98.

Moxham, B. J. (2012) 'What is best for the teaching of gross anatomy?', *Journal of anatomy,* 221(1), pp. 73-96.

Moxham, B. J., Emmanouil-Nikoloussi, E., Standley, H., Brenner, E., Plaisant, O., Brichova, H., Pais, D., Stabile, I., Borg, J. and Chirculescu, A. (2016) 'The attitudes of medical students in Europe toward the clinical importance of embryology', *Clinical anatomy (New York, N.Y.),* 29(2), pp. 144-150.

Moxham, B. J., Plaisant, O. and Pais, D. (2015) 'The place of neuroanatomy in the curriculum', *Eur J Anat,* 19(2), pp. 215-228.

Moxham, B. J., Plaisant, O., Smith, C. F., Pawlina, W. and McHanwell, S. (2014) 'An approach toward the development of core syllabuses for the anatomical sciences', *Anatomical sciences education,* 7(4), pp. 302-311.

Mukhopadhyay, S., Kruger, E. and Tennant, M. (2014) 'YouTube: a new way of supplementing traditional methods in dental education', *Journal of dental education,* 78(11), pp. 1568-1571.

Muller, F., Naharro, M. and Carlsson, G. E. (2007) 'What are the prevalence and incidence of tooth loss in the adult and elderly population in Europe?', *Clinical oral implants research,* 18 Suppl 3, pp. 2-14.

Myhrer, T., Evans, J. L., Haugen, H. K., Gorman, C., Kavanagh, Y. and Cameron, A. B. (2016) 'Exploring the consistency, transparency and portability of dental technology education: benchmarking across Norway, Ireland and Australia', *European journal of dental education : official journal of the Association for Dental Education in Europe,* 20(3), pp. 189-196.

Nadershahi, N. A., Bender, D. J., Beck, L. and Alexander, S. (2013) 'A case study on development of an integrated, multidisciplinary dental curriculum', *Journal of dental education,* 77(6), pp. 679-687.

Nagasawa, S., Yoshida, T., Tamura, K., Yamazoe, M., Hayano, K., Arai, Y., Yamada, H., Kasahara, E. and Ito, M. (2010) 'Construction of database for three-dimensional human tooth models and its ability for education and research--Carious tooth models', *Dental materials journal,* 29(2), pp. 132-137.

Nance, E. T., Lanning, S. K. and Gunsolley, J. C. (2009) 'Dental anatomy carving computer-assisted instruction program: an assessment of student performance and perceptions', *Journal of dental education,* 73(8), pp. 972-979.

Nazareth, A., Herrera, A. and Pruden, S. M. (2013) 'Explaining sex differences in mental rotation: role of spatial activity experience', *Cognitive processing,* 14(2), pp. 201-204.

Neha, Lalwani, S. and Dhingra, R. (2013) 'Plastinated knee specimens: a novel educational tool', *Journal of clinical and diagnostic research : JCDR,* 7(1), pp. 1-5.

Ng, Y. L., Mann, V., Rahbaran, S., Lewsey, J. and Gulabivala, K. (2008) 'Outcome of primary root canal treatment: systematic review of the literature -- Part 2. Influence of clinical factors', *International endodontic journal,* 41(1), pp. 6-31.

Nowinski, W. L., Johnson, A., Chua, B. C. and Nowinska, N. G. (2012) 'Three-dimensional interactive and stereotactic atlas of the cranial nerves and their nuclei correlated with surface neuroanatomy, vasculature and magnetic resonance imaging', *Journal of neuroscience methods,* 206(2), pp. 205-216.

Obrez, A., Briggs, C., Buckman, J., Goldstein, L., Lamb, C. and Knight, W. G. (2011) 'Teaching clinically relevant dental anatomy in the dental curriculum: description and assessment of an innovative module', *Journal of dental education,* 75(6), pp. 797-804.

Older, J. (2004) 'Anatomy: a must for teaching the next generation', *The surgeon : journal of the Royal Colleges of Surgeons of Edinburgh and Ireland,* 2(2), pp. 79-90.

Olowo-Ofayoku, A. and Moxham, B. J. (2014) 'Comparisons between the attitudes of medical and dental students toward the clinical importance of gross anatomy and physiology', *Clinical anatomy (New York, N.Y.),* 27(7), pp. 976-987.

Pandey, P. and Zimitat, C. (2007) 'Medical students' learning of anatomy: memorisation, understanding and visualisation', *Medical education,* 41(1), pp. 7-14.

Park, S. E. and Howell, T. H. (2015) 'Implementation of a flipped classroom educational model in a predoctoral dental course', *Journal of dental education,* 79(5), pp. 563-570.

Pereira, J. A., Pleguezuelos, E., Meri, A., Molina-Ros, A., Molina-Tomas, M. C. and Masdeu, C. (2007) 'Effectiveness of using blended learning strategies for teaching and learning human anatomy', *Medical education,* 41(2), pp. 189-195.

Perry, S., Bridges, S. M. and Burrow, M. F. (2015) 'A review of the use of simulation in dental education', *Simulation in healthcare : journal of the Society for Simulation in Healthcare,* 10(1), pp. 31-37.

Peters, M., Laeng, B., Latham, K., Jackson, M., Zaiyouna, R. and Richardson, C. (1995) 'A redrawn Vandenberg and Kuse mental rotations test: different versions and factors that affect performance', *Brain and cognition,* 28(1), pp. 39-58.

Peuker, E. T., Werkmeister, R., Pera, F., Joos, U. and Filler, T. J. (2001) '[Surgical procedures in mouth, jaw and facial surgery in Thiel embalmed body donors]', *Mund-, Kiefer- und Gesichtschirurgie : MKG,* 5(2), pp. 141-143.

Plasschaert, A. J., Lindh, C., McLoughlin, J., Manogue, M., Murtomaa, H., Nattestad, A. and Sanz, M. (2006) 'Curriculum structure and the European Credit Transfer System for European dental schools: part I', *European journal of dental education : official journal of the Association for Dental Education in Europe,* 10(3), pp. 123-130.

Postma, T. C. and White, J. G. (2017) 'Students' perceptions of vertical and horizontal integration in a discipline-based dental school', *European journal of dental education : official journal of the Association for Dental Education in Europe,* 21(2), pp. 101-107.

Rafai, N., Lemos, M., Kennes, L. N., Hawari, A., Gerhardt-Szep, S. and Classen-Linke, I. (2016) 'Anatomy meets dentistry! Linking anatomy and clinical practice in the preclinical dental curriculum', *BMC medical education,* 16(1), pp. 305.

Redwood, C. J. and Townsend, G. C. (2011) 'The dead center of the dental curriculum: changing attitudes of dental students during dissection', *Journal of dental education,* 75(10), pp. 1333-1344.

Reindl, K. M., White, A. R., Johnson, C., Vender, B., Slator, B. M. and McClean, P. (2015) 'The virtual cell animation collection: tools for teaching molecular and cellular biology', *PLoS biology,* 13(4), pp. e1002118.

Reissmann, D. R., Sierwald, I., Berger, F. and Heydecke, G. (2015) 'A model of blended learning in a preclinical course in prosthetic dentistry', *Journal of dental education,* 79(2), pp. 157-165.

Renard, E., Alliot-Licht, B., Gross, O., Roger-Leroi, V. and Marchand, C. (2015) 'Study of the impacts of patient-educators on the course of basic sciences in dental studies', *European journal of dental education : official journal of the Association for Dental Education in Europe,* 19(1), pp. 31-37.

Richardson-Hatcher, A., Hazzard, M. and Ramirez-Yanez, G. (2014) 'The cranial nerve skywalk: A 3D tutorial of cranial nerves in a virtual platform', *Anatomical sciences education,* 7(6), pp. 469-478.

Riederer, B. M. (2014) 'Plastination and its importance in teaching anatomy. Critical points for long-term preservation of human tissue', *Journal of anatomy,* 224(3), pp. 309-315.

Rizzolo, L. J. and Stewart, W. B. (2006) 'Should we continue teaching anatomy by dissection when ...?', *Anatomical record. Part B, New anatomist,* 289(6), pp. 215-218.

Robbins, B. D., Tomaka, A., Innus, C., Patterson, J. and Styn, G. (2008) 'Lessons from the dead: the experiences of undergraduates working with cadavers', *Omega,* 58(3), pp. 177-192.

Rosas, C., Rubi, R., Donoso, M. and Uribe, S. (2012) 'Dental students' evaluations of an interactive histology software', *Journal of dental education,* 76(11), pp. 1491-1496.

Rosenberg, H., Grad, H. A. and Matear, D. W. (2003) 'The effectiveness of computer-aided, self-instructional programs in dental education: a systematic review of the literature', *Journal of dental education,* 67(5), pp. 524-532.

Rosenberg, H., Kermalli, J., Freeman, E., Tenenbaum, H., Locker, D. and Cohen, H. (2006) 'Effectiveness of an electronic histology tutorial for first-year dental students and improvement in "normalized" test scores', *Journal of dental education,* 70(12), pp. 1339-1345.

Rowland, K. C. and Joy, A. (2015) 'The gross anatomy laboratory: a novel venue for critical thinking and interdisciplinary teaching in dental education', *Journal of dental education,* 79(3), pp. 295-300.

Ruiz, J. G., Cook, D. A. and Levinson, A. J. (2009) 'Computer animations in medical education: a critical literature review', *Medical education,* 43(9), pp. 838-846.

Salajan, F. D., Mount, G. J. and Prakki, A. (2015) 'An Assessment of Students' Perceptions of Learning Benefits Stemming from the Design and Instructional Use of a Web3D Atlas', *Electronic Journal of e-Learning,* 13(2), pp. 120-137.

Saltarelli, A. J., Roseth, C. J. and Saltarelli, W. A. (2014) 'Human cadavers Vs. multimedia simulation: A study of student learning in anatomy', *Anatomical sciences education,* 7(5), pp. 331-339.

Sandars, J. and Morrison, C. (2007) 'What is the Net Generation? The challenge for future medical education', *Medical teacher,* 29(2-3), pp. 85-88.

Schonwetter, D. J., Gareau-Wilson, N., Cunha, R. S. and Mello, I. (2016) 'Assessing the Impact of Voice-Over Screen-Captured Presentations Delivered Online on Dental Students' Learning', *Journal of dental education,* 80(2), pp. 141-148.

Schroeter, C. (1959) 'Practical application of tooth morphology', *J Prosthet Dent,* 9(5), pp. 867-873.

Sheth, S., Branstetter, B. F. t. and Escott, E. J. (2009) 'Appearance of normal cranial nerves on steady-state free precession MR images', *Radiographics : a review publication of the Radiological Society of North America, Inc,* 29(4), pp. 1045-1055.

Shigli, K., Agrawal, N., Nair, C., Sajjan, S., Kakodkar, P. and Hebbal, M. (2016) 'Use of PowerPoint presentation as a teaching tool for undergraduate students in the subject of gerodontology', *Journal of Indian Prosthodontic Society,* 16(2), pp. 187-192.

Smith, C. F., Finn, G. M., Stewart, J. and McHanwell, S. (2016) 'Anatomical Society core regional anatomy syllabus for undergraduate medicine: the Delphi process', *Journal of anatomy,* 228(1), pp. 2-14.

Snelling, J., Sahai, A. and Ellis, H. (2003) 'Attitudes of medical and dental students to dissection', *Clinical anatomy (New York, N.Y.),* 16(2), pp. 165-172.

Snyman, W. D. and Kroon, J. (2005) 'Vertical and horizontal integration of knowledge and skills - a working model', *European journal of dental education : official journal of the Association for Dental Education in Europe,* 9(1), pp. 26-31.

Sperber, G. H. (2003) 'Fabricating a face: the essence of embryology in the dental curriculum', *Journal of dental education,* 67(3), pp. 370-374.

Steiner, T., Raith, S., Eichhorn, S., Doebele, S., Trainotti, S., Muller, S., Eder, M., Kovacs, L., Burgkart, R., Wolff, K. D. and Holzle, F. (2012) 'Evaluation of a new optical measuring system for experiments on fractured human mandibles: a biomechanical feasibility study in maxillofacial surgery', *Clinical oral investigations,* 16(6), pp. 1535-1542.

Sugand, K., Abrahams, P. and Khurana, A. (2010) 'The anatomy of anatomy: a review for its modernization', *Anatomical sciences education,* 3(2), pp. 83-93.

Suvinen, T. I., Messer, L. B. and Franco, E. (1998) 'Clinical simulation in teaching preclinical dentistry', *European journal of dental education : official journal of the Association for Dental Education in Europe,* 2(1), pp. 25-32.

Swenberg, J. A., Moeller, B. C., Lu, K., Rager, J. E., Fry, R. C. and Starr, T. B. (2013) 'Formaldehyde carcinogenicity research: 30 years and counting for mode of action, epidemiology, and cancer risk assessment', *Toxicologic pathology,* 41(2), pp. 181-189.

Thiel, W. (1992) '[The preservation of the whole corpse with natural color]', *Annals of anatomy = Anatomischer Anzeiger : official organ of the Anatomische Gesellschaft,* 174(3), pp. 185-195.

Tou, S., Tou, W., Mah, D., Karatassas, A. and Hewett, P. (2013) 'Effect of preoperative two-dimensional animation information on perioperative anxiety and knowledge retention in patients undergoing bowel surgery: a randomized pilot study', *Colorectal disease : the official journal of the Association of Coloproctology of Great Britain and Ireland,* 15(5), pp. e256-265.

Trelease, R. B. (2002) 'Anatomical informatics: Millennial perspectives on a newer frontier', *The Anatomical record,* 269(5), pp. 224-235.

Tubbs, R. S., Sorenson, E. P., Sharma, A., Benninger, B., Norton, N., Loukas, M. and Moxham, B. J. (2014) 'The development of a core syllabus for the teaching of head and neck anatomy to medical students', *Clinical anatomy (New York, N.Y.),* 27(3), pp. 321-330.

Turney, B. W. (2007) 'Anatomy in a modern medical curriculum', *Annals of the Royal College of Surgeons of England,* 89(2), pp. 104-107.

Tversky, B., Morrison, J. B. and Betrancourt, M. (2002a) 'Animation: can it facilitate?', *International Journal of Human-Computer Studies,* 57(4), pp. 247-262.

Tversky, B., Morrison, J. B. and Betrancourt, M. (2002b) 'Animation: can it facilitate?', *Int J Hum-Comput St,* 57(4), pp. 247-262.

Vandenberg, S. G. and Kuse, A. R. (1978) 'Mental rotations, a group test of three-dimensional spatial visualization', *Perceptual and motor skills,* 47(2), pp. 599-604.

Verma, P. and Love, R. M. (2011) 'A Micro CT study of the mesiobuccal root canal morphology of the maxillary first molar tooth', *International endodontic journal,* 44(3), pp. 210-217.

Vernon, T. and Peckham, D. (2002) 'The benefits of 3D modelling and animation in medical teaching', *The Journal of audiovisual media in medicine,* 25(4), pp. 142-148.

von Hagens, G., Tiedemann, K. and Kriz, W. (1987) 'The current potential of plastination', *Anatomy and embryology,* 175(4), pp. 411-421.

Vuchkova, J., Maybury, T. and Farah, C. S. (2012) 'Digital interactive learning of oral radiographic anatomy', *European journal of dental education : official journal of the Association for Dental Education in Europe,* 16(1), pp. e79-87.

Wallen, E. S., Schulein, T. M. and Johnson, L. A. (1997) 'A computer program to aid in visual concept development in dentistry', *Computer methods and programs in biomedicine,* 52(2), pp. 105-115.

Ward, J. P., Gordon, J., Field, M. J. and Lehmann, H. P. (2001) 'Communication and information technology in medical education', *Lancet (London, England),* 357(9258), pp. 792-796.

Wilson, T. (2015a) 'Role of Image and Cognitive Load in Anatomical Multimedia', in Chan, L.K. & Pawlina, W. (eds.) *Teaching Anatomy*: Springer International Publishing, pp. 237-246.

Wilson, T. (2015b) 'Role of Image and Cognitive Load in Anatomical Multimedia', in Chan, L.K. & Pawlina, W. (eds.) *Teaching Anatomy: A Practical Guide.* 1st ed. New York, NY: Springer International., pp. 237-246.

Windisch, G., Weiglein, A. H. and Kiesler, K. (2004) 'Herniation of the mylohyoid muscle', *The Journal of craniofacial surgery,* 15(4), pp. 566-569.

Winkelmann, A. (2007) 'Anatomical dissection as a teaching method in medical school: a review of the evidence', *Medical education,* 41(1), pp. 15-22.

Wolff, K. D., Kesting, M., Mucke, T., Rau, A. and Holzle, F. (2008) 'Thiel embalming technique: a valuable method for microvascular exercise and teaching of flap raising', *Microsurgery,* 28(4), pp. 273-278.

Wright, E. F. and Hendricson, W. D. (2010) 'Evaluation of a 3-D interactive tooth atlas by dental students in dental anatomy and endodontics courses', *Journal of dental education*, 74(2), pp. 110-122.

Yeung, J. C., Fung, K. and Wilson, T. D. (2011) 'Development of a computer-assisted cranial nerve simulation from the visible human dataset', *Anatomical sciences education*, 4(2), pp. 92-97.

Yeung, J. C., Fung, K. and Wilson, T. D. (2012) 'Prospective evaluation of a web-based three-dimensional cranial nerve simulation', *Journal of otolaryngology - head & neck surgery = Le Journal d'oto-rhino-laryngologie et de chirurgie cervico-faciale*, 41(6), pp. 426-436.

Yue, C., Kim, J., Ogawa, R., Stark, E. and Kim, S. (2013) 'Applying the cognitive theory of multimedia learning: an analysis of medical animations', *Medical education*, 47(4), pp. 375-387.