

Title	Perplexing plain abdominal x-ray.
Author(s)	Crush, Lee; O'Connor, Owen J.; Plant, William D.; Clarkson, Michael R.; Shanahan, Fergus; Maher, Michael M.
Publication date	2011-02
Original citation	Crush, L., O'Connor, O. J., Plant, W., Clarkson, M. R., Shanahan, F. and Maher, M. M. (2011) 'Perplexing plain abdominal x-ray', Gut, 60(2), pp. 218 + 254. doi: 10.1136/gut.2010.215822
Type of publication	Article (peer-reviewed)
Link to publisher's version	https://gut.bmj.com/content/60/2/218 http://dx.doi.org/10.1136/gut.2010.215822 Access to the full text of the published version may require a subscription.
Rights	© 2011, Published by the BMJ Publishing Group Limited. For permission to use (where not already granted under a licence) please go to http://group.bmj.com/group/rights-licensing/permissions .
Item downloaded from	http://hdl.handle.net/10468/6609

Downloaded on 2019-02-23T11:07:16Z

Perplexing PFA

L Crush L, ¹ OJ O'Connor, ¹ W Plant, ² MR Clarkson, ² F Shanahan, ² MM Maher ¹

CO-AUTHORS

Dr Lee Crush. MB, MRCSI, Departments of Radiology, Cork University Hospital, Mercy University Hospital and University College Cork, Cork, Ireland

Dr Owen J. O'Connor. MD, FFRRCSI, Departments of Radiology, Cork University Hospital, Mercy University Hospital and University College Cork, Cork, Ireland

Dr William Plant. MD, Department of Medicine, Cork University Hospital and University College Cork, Cork, Ireland

Dr. Michael R. Clarkson. MD, FRCP, Department of Medicine, Cork University Hospital and University College Cork, Cork, Ireland

Professor Fergus Shanahan. MD, FRCP, Department of Medicine, Cork university Hospital and University College Cork, Ireland

Professor Michael M. Maher. MD, FRCR, Departments of Radiology, Cork University Hospital, Mercy University Hospital and University College Cork, Cork, Ireland

CORRESPONDING AUTHOR

Professor Michael M. Maher. MD, FRCR

Department of Radiology

Mercy University Hospital, Cork, Ireland

Email: m.maher@ucc.ie

Phone: 00353-861731929

Fax: 00353-214922857

KEYWORDS

Plain film of abdomen, retained barium, haemodialysis, lanthanum carbonate

CLINICAL PRESENTATION

A 62 year-old male presented to hospital with generalized abdominal pain of long standing duration. His background medical history was notable for end-stage kidney disease (ESKD) secondary to focal segmental glomerulosclerosis for which he required hemodialysis three times per week. Esophagogastroduodenoscopy, optical colonoscopy, barium meal and enema studies in the previous two years were normal apart from the detection of a small hiatus hernia. Physical exam revealed diffuse abdominal tenderness without guarding, rebound or focal tenderness. There was no palpable organomegaly or intraabdominal mass. The patient's medications included alfacalcidol 0.25 mcg once per day (od), sevelamer hydrochloride 800 mg three times per day (tds), lanthanum carbonate 1000 mg tds, omeprazole 40 mg od as well as medications for hypertension and anxiety. Due to the persistent nature of his abdominal discomfort, a plain film of the abdomen (fig 1a) was performed and compared with a radiograph performed one year earlier (fig 1b).

QUESTION

What are the major imaging findings on the PFA and based on the patient's history, what is the most likely explanation for the PFA finding?

ANSWER

Plain film of abdomen (fig 1) depicts numerous 5-10 mm foci of increased density, which are located in the anatomic path of the colon which were not present on the previous exam (fig 1b). The explanation for these imaging findings was not immediately apparent.

Analysis of the patient's imaging records revealed that a barium enema had been performed 30 months prior to the abdominal radiograph which demonstrated the opacities. Review of the earlier abdominal radiograph (Fig 1b) showed normal appearances with no focal hyperdensities present in the colon. Treatment with lanthanum carbonate had been commenced six months after the initial normal PFA. Following a literature review, we concluded that the interval development of focal hyperdensities within the colon in the 12 month interval between the two PFA's, was explained by the formation of lanthanum bound plaques of phosphate within the colon. These angular hypersensities could easily have been wrongly attributed to retained barium in the colon, had a review of previous imaging studies been omitted.

An imaging feature of lanthanum particles on plain abdominal radiography in patients on continuous lanthanum treatment, is that the focal hyperdensities observed change position between imaging studies, whereas retained barium has a globular appearance and long-term retention is usually confined to colonic diverticulae¹. The finding that the lanthanum plaques move between PFA's has clinical implications and suggests patient compliance with medication and there have been proposals in the nephrology literature that regular PFA's can be used as a means of monitoring patient compliance with medications. ¹

Patients with ESKD receiving haemodialysis develop hyperphosphataemia due to impaired phosphate excretion which increases their risk of renal bone disease and cardiovascular disease. ²

High serum [phosphate] combined with low serum [calcium] secondary to lack of vitamin D induces secondary hyperparathyroidism.² Lanthanum carbonate is a trivalent rare-earth element which tightly binds phosphate inhibiting absorption through the gastrointestinal resulting in excretion through the colon.³

The imaging findings on PFA in patients on lanthanum therapy are not widely appreciated. This case report is written to highlight typical imaging findings associated with ingestion of lanthanum and to reduce potential for diagnostic uncertainty which can arise, when these peculiar imaging findings on PFA are encountered. It is also important to highlight the importance of referring physicians providing information regarding lanthanum carbonate ingestion, when requesting a PFA.

License for Publication statement:

"The Corresponding Author has the right to grant on behalf of all authors and does grant on behalf of all authors, an exclusive licence (or non exclusive for government employees) on a worldwide basis to the BMJ Publishing Group Ltd and its Licensees to permit this article (if accepted) to be published in Gut editions and any other BMJPGJL products to exploit all subsidiary rights, as set out in our licence(<http://group.bmj.com/products/journals/instructions-for-authors/licence-forms>)."

Competing Interest:

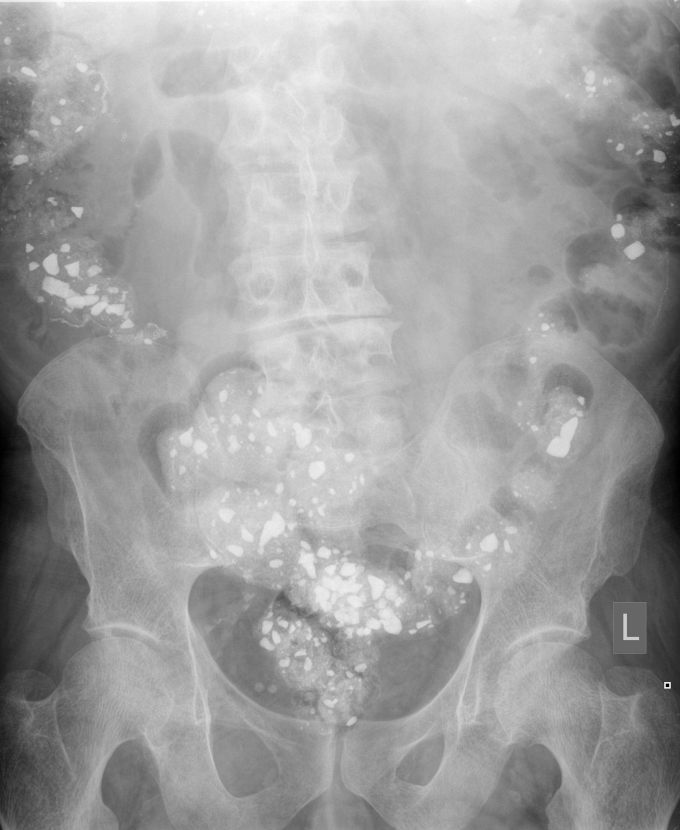There are no competing interests to declare.

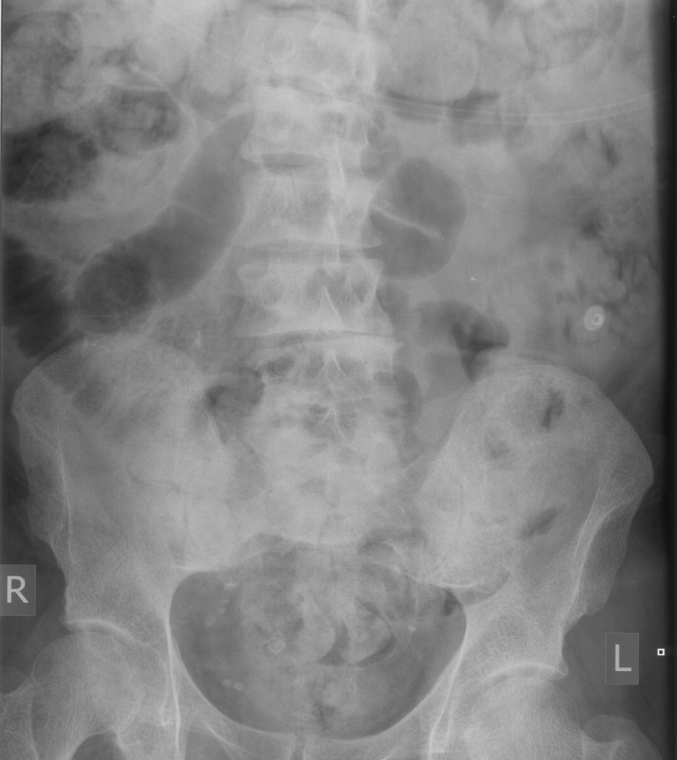
FIGURE LEGEND

Figure 1 (A and B) Plain films of abdomen performed at presentation (fig 1a) and one year earlier (fig 1b). There are multiple hyperdensities in the distribution of the colon due to ingested lanthanum carbonate which were not present following the barium enema but which developed following lanthanum carbonate ingestion.

REFERENCES

1. **David S**, Kirchhoff T, Haller H. Heavy metal rely on gut feelings: novel diagnostic approach to test drug compliance in patients with lanthanum intake. *Nephrol Dial Transplant* 2007;**22**:2091-92.
2. **Persey VP**, Behets GJ, DeBroe ME, D'Haese PC. Management of hyperphosphatemia in patients with end-stage renal disease: focus on lanthanum carbonate. *International journal of nephrology and renovascular disease* 2009;**2**: 1-8.
3. **Pennick M**, Dennis K, Damment SJ. Absolute bioavailability and disposition of lanthanum in healthy human subjects administered lanthanum carbonate. *J Clin Pharmacol* 2006;**46**(7):738-46.





R

L