

**UCC Library and UCC researchers have made this item openly available.
Please [let us know](#) how this has helped you. Thanks!**

Title	Decisions on repositioning of intruded permanent incisors; A review and case presentation
Author(s)	Hurley, Eimear; Stewart, Christopher J.; Gallagher, Christine; Kinirons, Martin J.
Publication date	2018
Original citation	Hurley, E., Stewart, C. J., Gallagher, C. and Kinirons, M. J. (2018) 'Decisions on repositioning of intruded permanent incisors; A review and case presentation'. European Journal of Paediatric Dentistry, 19 (2):101-104. doi: 10.23804/ejpd.2018.19.02.03
Type of publication	Article (peer-reviewed)
Link to publisher's version	http://ejpd.eu/EJPD_2018_2_2.pdf http://dx.doi.org/10.23804/ejpd.2018.19.02.03 Access to the full text of the published version may require a subscription.
Rights	© 2018, European Journal of Paediatric Dentistry.
Item downloaded from	http://hdl.handle.net/10468/9807

Downloaded on 2022-05-16T15:34:26Z



UCC

University College Cork, Ireland
Coláiste na hOllscoile Corcaigh

E. Hurley, C. Stewart, C. Gallagher, M. Kinirons

Cork University Dental School & Hospital, University College
Cork, Ireland

e-mail: E.Hurley@ucc.ie

DOI: 10.23804/ejpd.2018.19.02.03

Decisions on repositioning of intruded permanent incisors; a review and case presentation

ABSTRACT

Background Traumatic intrusion is a luxation type of injury where the tooth is displaced along the axis of the tooth, into the alveolus. This injury is regarded as serious because of the tissue damage that it causes. The traumatic movement is associated with severe damage to the periodontal ligament, pulpal tissue, root and alveolar socket. Despite its severity, the rare occurrence of this injury in permanent teeth has resulted in limited studies of immature and mature permanent incisors. The purpose of this paper is to review this luxation injury of permanent immature incisors, and to describe its diagnosis, treatment and management. In particular, we describe the repositioning strategies used in cases of intrusion injury. These include (i) monitoring spontaneous re-eruption, (ii) active orthodontic repositioning and (iii) surgical repositioning. Firstly, monitoring spontaneous re-eruption is observing and waiting for the intruded tooth to return to its original position. This process is not a normal developmental eruption and the outcome is not always predictable, nor is the time needed for this to happen. Secondly, active orthodontic repositioning is used to describe the process of rapidly moving the intruded tooth to its original position with the aid of an orthodontic appliance. Active orthodontic repositioning is often misunderstood as normal orthodontic movement. Orthodontic movement allows for periodontal ligament remodelling, using light intermittent forces. In contrast the active orthodontic repositioning used to move intruded incisors is rapid, and the primary aim is to achieve correct tooth position as rapidly as possible.

Thirdly, surgical repositioning uses surgical intervention to bring the tooth back to its original position. A case of an intruded immature permanent incisor is presented, with a particular emphasis on these critical decisions on repositioning and showing the use of the three modalities of treatment in sequence, in order to achieve an outcome.

Keywords Dental trauma, Intrusion, Immature permanent incisor, Monitoring spontaneous re-eruption, Active orthodontic repositioning, Surgical repositioning.

Introduction

Traumatic intrusion is a luxation injury where the tooth is displaced axially into the alveolus. This type of injury is more common in the primary dentition and accounts for 0.3-1.9% of the traumatic injuries seen in permanent teeth [Andreasen et al., 2006]. When a tooth is intruded, it is a complex injury, involving tearing and crushing of the periodontal ligament fibres, contusion of the alveolar bone, and breakdown of the neurovascular supply to the pulp [Andreasen et al., 2003]. As described by Andreasen et al. [2006] there is a high risk of inflammatory resorption, replacement resorption and ankylosis in these cases. We discuss the guidelines for treatment and management of both immature and mature apices of permanent incisors. The case gives the key details of the management of a patient and illustrates the critical choices that clinicians face when making decisions on the best way of ensuring optimal repositioning.

Treatment options for intruded mature and immature permanent incisors

Despite its severity, the rare occurrence of this injury in permanent teeth (0.3-1.9%) means that there are few studies and limited evidence to guide the management of intruded permanent incisors, whether immature or mature. There are some guidelines available, including Kinirons [1998], Andreasen et al. [2003], the AAPD Guidelines [American Academy of Pediatric Dentistry AAPD, 2011], the BSPD guidelines by Al-badri et al. [2010], and the IADT guidelines by Diangelis et al. [2012] and Flores et al. [2007]. Due to the rarity of this injury in permanent teeth compared to primary teeth [Diangelis et al., 2012; Kinirons et al., 1999], and the complicated nature of the healing process which follows, the prognosis for these teeth is often very uncertain [Wright et al., 2007].

A recent systematic review of the intrusive luxation of permanent teeth studies was completed [AlKhalifa and AlAzemi, 2014]. Only cohort studies which compared spontaneous eruption, surgical and orthodontic extrusion were assessed. Out of 117 records screened, only 3

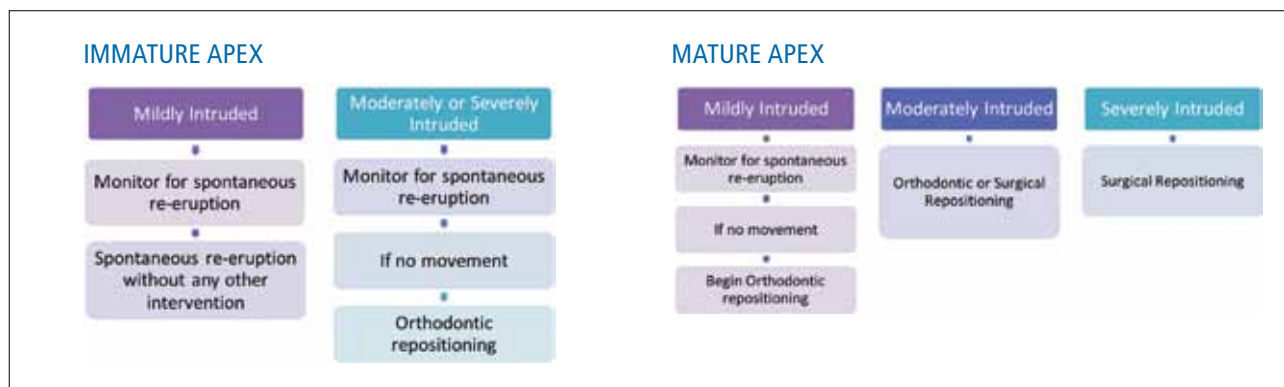


FIG. 1 A summary of the repositioning options for intruded immature and mature permanent incisors.

studies were included as part of their conclusion; these were Andreasen et al. [2006b], Wiggen et al. [2008] and Tsilingaridis et al. [2012]. For each of these three retrospective studies, they each had a range of patients: 114 patients (aged 6–67 years), 39 patients (6–17 years) and 48 patients (6–16 years). The follow up period varied from 1 year, 1–12 years and finally 6–130 months for each of the studies and the time needed for spontaneous re-eruption was median 6.3 months [Andreasen et al., 2006b], mean 5.6 months [Wiggen et al., 2008] and mean 3.9 months [Tsilingaridis et al., 2012]. This study concluded, due to insufficient evidence, neither surgical nor orthodontic repositioning are a superior treatment option over one another, and highlighted the need for more observational studies, to support current guidelines.

There are general recommendations & considerations that should be followed.

Initial assessment

- History and clinical examination.
- Medical and dental history.
- Trauma history.
- Examination for associated facial or intra-oral injuries.
- Pulp testing.
- Sutures if required.

Radiographic examination

One or more views (periapical/occlusal) as recommended by the International Association for Dental Traumatology [Flores et al., 2007; Diangelis et al., 2012].

Splinting

Splint for 4 weeks in the case of surgical repositioning, that is flexible and that allows physiologic movement of the tooth to encourage healing [Andreasen et al., 2006b]

Ancillary measures

Use of antibiotics in cases where there is soft tissue injury and contamination

For treatment of immature and mature permanent

teeth, three treatment modalities are available:

1. Monitoring spontaneous re-eruption;
2. Active orthodontic repositioning;
3. Surgical repositioning.

The decision on repositioning will vary according to the maturity of the root, and the severity of intrusion. Guidelines have been developed to help optimise treatment for traumatically intruded permanent teeth in children [Kinirons, 1998; Andreasen et al., 2003; Flores et al., 2007; Al-badri et al., 2010; AAPD., 2011; Diangelis et al., 2012]. It has been shown that an important factor for the monitoring spontaneous re-eruption is the stage of root development [Humphrey et al. 2003; Al-Badri et al., 2002]. The purpose of this paper is to describe and share a case of moderate traumatic intrusion of an immature permanent maxillary central incisor. Figure 1 illustrate the treatment guidelines for immature and mature permanent incisors, interpreting the guidelines [Kinirons, 1998; Andreasen et al., 2003; Flores et al., 2007; Al-badri et al., 2010; AAPD., 2011; Diangelis et al., 2012].

Case report

A girl aged 7.5 years fell while playing outside and sustained an intrusion injury to her immature maxillary left central incisor (UL2). She was an irregular attendee of our dental clinic and her oral hygiene was poor. The tooth was moderately intruded and the incisal edge was visible. The adjacent dentition was not affected. The patient was prescribed a chlorohexidine mouthwash and advised on a soft diet for 2 weeks.

Stages

1. Monitoring spontaneous re-eruption.
Figure 2 shows the moderate degree of intrusion of the upper left permanent central incisor. The patient was advised to wait and it was decided to monitor for spontaneous re-eruption as indicated in the guidelines. This was monitored by their own dental practitioner.

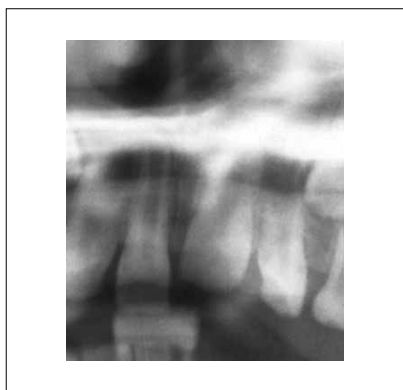

FIG. 2 The upper left permanent central incisor (UL1) with an immature apex is moderately intruded in a 7.5 year old. It was decided to monitor for spontaneous re-eruption as indicated in the guidelines.

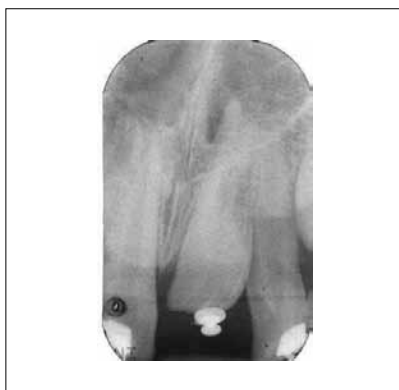

FIG. 3 Active rapid orthodontic repositioning of the UL1 intruded tooth was attempted at 4 months but the tooth resisted and no movement occurred.

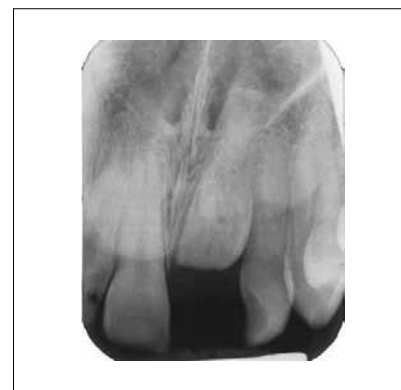

FIG. 4 On subsequent examination there was evidence of ankylosis and the tooth became submerged. As all other options have failed, a decision was made to surgically reposition.

2. Active orthodontic repositioning.

As there was no evidence of movement after 4 months and the tooth was rigid, the practitioner attempted active rapid orthodontic repositioning of the intruded tooth but the tooth resisted and no movement occurred (Fig. 3). There was evidence of ankylosis and the tooth rapidly became submerged. A space maintainer was provided to retain the space pending definitive treatment and the patient was referred to the Dental Hospital. On examination the tooth was deeply embedded and the crown was not visible (Fig. 4).

3. Surgical repositioning.

As the tooth was submerged and all other repositioning options had failed, a decision was made to surgically explore the area with a view to providing definitive treatment. A flapless approach was employed and the tooth was drawn down axially to the occlusal level. The crown and root were intact and the socket was compressed, the soft tissues were sutured and a flexible wire and composite splint was fitted and retained until the tooth mobility reading was normal

4. Follow-up at two years

The tooth was clinically firm and the patient is very content with the appearance (Fig. 5). It was not tender to percussion, it remained positive to vitality testing and the periapical condition was normal. The oral hygiene and gingival conditions were fair and the gingival crevice readings for the tooth were 2 mm. The gingival attachment labial to the upper left central incisor remains slightly higher than that seen in the adjacent teeth. The post-operative periapical radiograph illustrates its current position, with root

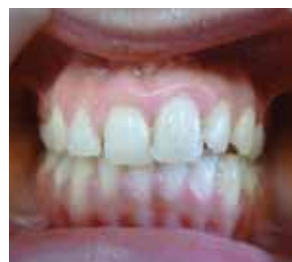

FIG. 5 The surgically repositioned upper left central incisor (UL1) after splint removal.

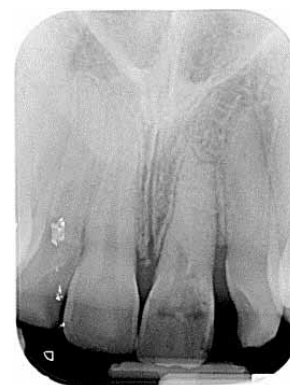

FIG. 6 Radiograph taken 1 year after surgery. There is evidence of sclerosis of the root canal of the UL1.

canal obliteration apically, but coronal pulpal tissue evident, distal bone loss, but no periapical pathology (Fig. 6). The tooth is being monitored regularly for endodontic treatment need.

This patient, since presentation, has been progressed through all three modes of repositioning treatment described in the Dental Trauma Guidelines [Kinirons, 1998; Andreasen et al., 2003; Flores et al., 2007; Albadri et al., 2010; AAPD., 2011; Diangelis et al., 2012]; from the initial decision to allow monitoring spontaneous re-eruption, to next attempted active orthodontic repositioning, and finally to achieve surgical repositioning (Fig. 7). The treatment provided resulted in a situation which is functional and is aesthetically acceptable to the patient for the present.

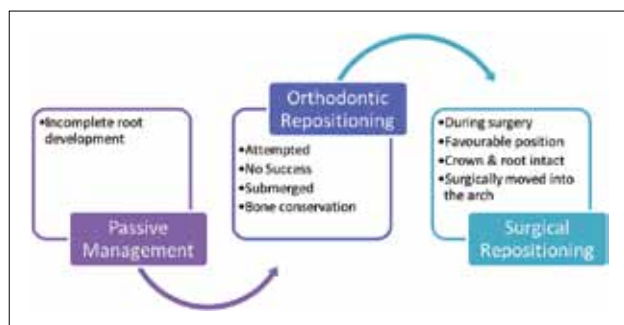


FIG. 7 Treatment phases used in the case presented.

Discussion and conclusion

Owing to the relatively poor evidence and absence of randomised control trials comparing the outcomes of different treatment options for intruded permanent teeth, the best course of treatment has been controversial. There have been some retrospective studies published, supporting different treatment options [Andreasen et al., 2006a; Stewart et al., 2012; Neto et al., 2009]. The Clinical Guidelines [Kinirons, 1998; Andreasen et al., 2003; Flores et al., 2007; Al-badri et al., 2010; AAPD., 2011; Diangelis et al., 2012], generally recommend monitoring for spontaneous re-eruption for all immature permanent teeth and for mature teeth where the intrusion is mild, and if no movement is seen, then an active orthodontic repositioning method should be undertaken. The time taken for monitoring spontaneous re-eruption varies with the following studies finding that the time needed for spontaneous re-eruption was median 6.3 months [Andreasen et al., 2006b], mean 5.6 months [Wigen et al., 2008] and mean 3.9 months [Tsilingaridis et al., 2012]. This spontaneous re-eruption is not a normal developmental eruption, as the tooth movement is by unknown forces, and is unpredictable due to the pathology [Humphrey et al., 2003; Kenny et al., 2003]. Active orthodontic repositioning meanwhile is somewhat different from normal orthodontic movement. Orthodontic repositioning allows for periodontal ligament remodelling, using light intermittent forces, whereas active orthodontic repositioning is used to rapidly correct the intruded incisor position and is not specifically designed to achieve periodontal ligament remodelling [Humphrey et al., 2003; Kenny et al., 2003]. The IADT guidelines recommend active repositioning if no spontaneous re-eruption is evident within 2-4 weeks [Diangelis et al., 2012], however more research in into this time frame is needed. Active orthodontic repositioning is recommended from the outset for moderately or severely intruded mature permanent teeth and surgical repositioning may be required in severe cases [Al-badri et al., 2010]. In this case, the recommended protocols were followed (Fig. 1), firstly monitoring spontaneous re-eruption, and then active orthodontic repositioning and

finally surgical repositioning was required. This resulted in the upper left central incisor being retained, back in the arch and functional. This case highlights the fact that, although there is often a debate over whether to choose active orthodontic or surgical repositioning, it may be necessary to progress from one modality to the other, if and when this is required to achieve the best outcome.

References

- › Al-Badri S, Kinirons MJ, Cole B, Welbury R. Factors affecting resorption in traumatically intruded permanent incisors in children. *Dent Traumatol* 2002;18:73–76.
- › Al-badri S, Zaitoun H, Kinirons MJ. UK National Clinical Guidelines in Paediatric Dentistry: treatment of traumatically intruded permanent incisor teeth in children. *Int J Paediatr Dent* 2010; 20:1–2.
- › AlKhalifa JD, AlAzemi AA. Intrusive luxation of permanent teeth: a systematic review of factors important for treatment decision-making. *Dent Traumatol* 2014; 30:169–175.
- › American Academy of Pediatric Dentistry(AAPD). Guideline on Management of Acute Dental Trauma. Reference Manual; Clinical Guidel 2011;32: 230–238.
- › Andreasen JO, Bakland LK, Matras RC, Andreasen FM. Traumatic intrusion of permanent teeth. Part 1. An epidemiological study of 216 intruded permanent teeth. *Dent Traumatol* 2006; 22:83–89.
- › Andreasen JO, Bakland LK, Andreasen FM. Traumatic intrusion of permanent teeth. Part 2. A clinical study of the effect of preinjury and injury factors, such as sex, age, stage of root development, tooth location, and extent of injury including number of intruded teeth on 140 intruded permanent . *Dental traumatology : official publication of International Association for Dental Traumatol* 2006a; 22: 90–98.
- › Andreasen JO, Bakland LK, Andreasen FM. Traumatic intrusion of permanent teeth. Part 3. A clinical study of the effect of treatment variables such as treatment delay, method of repositioning, type of splint, length of splinting and antibiotics on 140 teeth. *Dent Traumatol* 2006b; 22: 99–111.
- › Andreasen JO, Andreasen FM, Bakland LK. Traumatic dental injuries; a manual. Second edition .Blackwell Munksgaard Publishers. 2003; pp 13.
- › Diangelis AJ, Andreasen JO, Ebeleseder KA, Kenny DJ, Trope M, Sigurdsson A, Andersson L, Bourguignon C, Flores MT, Hicks M.L, Lenzi A.R, Malmgren B, Moule AJ, Pohl Y, Tsukiboshi M. International Association of Dental Traumatology guidelines for the management of traumatic dental injuries: 1. Fractures and luxations of permanent teeth. *Dent Traumatol* 2012; 28: 2–12.
- › Flores MT, Andersson L, Andreasen JO, Bakland LK, Malmgren B, Barnett F, Bourguignon C, DiAngelis A, Hicks L, Sigurdsson A, Trope M, Tsukiboshi M, Von Arx T. Guidelines for the management of traumatic dental injuries. I. Fractures and luxations of permanent teeth. *Dental Traumatol* 2007; 23:66–71.
- › Humphrey JM, Kenny DJ, Barrett EJ. Clinical outcomes for permanent incisor luxations in a pediatric population. I. Intrusions. *Dent Traumatol* 2003;19:266–273.
- › Kenny DJ, Barrett EJ, Casas MJ. Avulsions and intrusions: the controversial displacement injuries. *J Can Dent Assoc* 2003;69:308–313.
- › Kinirons, MJ. UK National Clinical Guidelines in Paediatric Dentistry. Treatment of traumatically intruded permanent incisor teeth in children. *Int J Paediatr Dent* 1998; 1–3.
- › Kinirons MJ, Boyd DH, Gregg TA. Inflammatory and replacement resorption in reimplanted permanent incisor teeth: a study of the characteristics of 84 teeth. *Endod Dent Traumatol* 1999;15:269–272.
- › Neto JJSM, Gondim JO, de Carvalho FM, Giro EMA. Longitudinal clinical and radiographic evaluation of severely intruded permanent incisors in a pediatric population. *Dent Traumatol* 2009; 25:510–514.
- › Stewart C, Dawson M, Phillips J, Shafi I, Kinirons M.J, Welbury R. A study of the management of 55 traumatically intruded permanent incisor teeth in children. *Eur Arch Paediatr Dent* 2012;10:25–28.
- › Tsilingaridis G, Malmgren B, Andreasen J.O, Malmgren O. Intrusive luxation of 60 permanent incisors: a retrospective study of treatment and outcome. *Dent Traumatol* 2012;28:416–422.
- › Wigen T.I, Agnalt R, Jacobsen I. Intrusive luxation of permanent incisors in Norwegians aged 6-17 years: a retrospective study of treatment and outcome. *Dent Traumatol* 2008;24:612–618.
- › Wright G, Bell A, McGlashan G, Vincent C, Welbury R. Dentoalveolar trauma in Glasgow: an audit of mechanism and injury. *Dent Traumatol* 2007;23:226–31.