

Title	Metastatic meningioma: positron emission tomography CT imaging findings
Authors	Brennan, Cressida R.;O'Connor, Owen J.;O'Regan, Kevin N.;Keohane, Catherine;Dineen, J.;Hinchion, John;Sweeney, Brian J.;Maher, Michael M.
Publication date	2010-01
Original Citation	Brennan, C., O'Connor, O. J., O'Regan, K. N., Keohane, C., Dineen, J., Hinchion, J., Sweeney, B. and Maher, M. M. (2010) 'Metastatic meningioma: positron emission tomography CT imaging findings'. The British Journal of Radiology, 83(996), pp. e259-e262. <a href="http://www.birpublications.org/doi/abs/10.1259/bjr/11276652">http://www.birpublications.org/doi/abs/10.1259/bjr/11276652</a>
Type of publication	Article (peer-reviewed)
Link to publisher's version	<a href="http://dx.doi.org/10.1259/bjr/11276652">10.1259/bjr/11276652</a>
Rights	© 2010 The British Institute of Radiology.
Download date	2025-07-02 00:40:45
Item downloaded from	<a href="https://hdl.handle.net/10468/2890">https://hdl.handle.net/10468/2890</a>

## CASE REPORT

# Metastatic meningioma: positron emission tomography CT imaging findings

<sup>1</sup>C BRENNAN, <sup>1</sup>O J O'CONNOR, <sup>1</sup>K N O'REGAN, <sup>2</sup>C KEOHANE, <sup>2</sup>J DINEEN, <sup>3</sup>J HINCHION, <sup>2</sup>B SWEENEY and <sup>1</sup>M M MAHER

<sup>1</sup>Department of Radiology, Cork University Hospital and University College Cork, Cork, Ireland, <sup>2</sup>Neuroscience Divisions, Cork University Hospital and University College Cork, Cork, Ireland, and <sup>3</sup>Department of Cardiothoracic Surgery, Cork University Hospital, Wilton, Cork, Ireland

**ABSTRACT.** The imaging findings of a case of metastasing meningioma are described. The case illustrates a number of rare and interesting features. The patient presented with haemoptysis 22 years after the initial resection of an intracranial meningioma. CT demonstrated heterogeneous masses with avid peripheral enhancement without central enhancement. Blood supply to the larger lesion was partially from small feeding vessels from the inferior pulmonary vein. These findings correlate with a previously published case in which there was avid uptake of fluoro-18-deoxyglucose peripherally with lesser uptake centrally. The diagnosis of metastasing meningioma was confirmed on percutaneous lung tissue biopsy.

Received 22 July 2009  
Revised 21 September 2009  
Accepted 8 October 2009

DOI: 10.1259/bjr/11276652

© 2010 The British Institute of Radiology

Typically, meningiomas are slow-growing benign neoplasms of the central nervous system derived from meningotheial cells; these neoplasms account for about 25% of intracranial tumours [1]. Meningiomas are graded from I to III indicating increasing grades of malignancy according to World Health Organization (WHO) criteria [1]. Meningiomas are usually indolent, slow-growing tumours and surgery is curative in the majority of cases [2, 3]. We present a rare case of a woman who had resection of an intracranial meningioma performed 22 years previously. The patient presented with haemoptysis and on imaging was found to have bilateral pulmonary lesions; these were confirmed as metastatic meningioma following CT-guided percutaneous biopsy. This report focuses primarily on the imaging features of a meningioma that metastasised to lung. Particular reference is given to CT and combined positron emission tomography and CT (PET/CT) appearances. The role of percutaneous lung biopsy in histological confirmation of the diagnosis is also briefly discussed.

## Case report

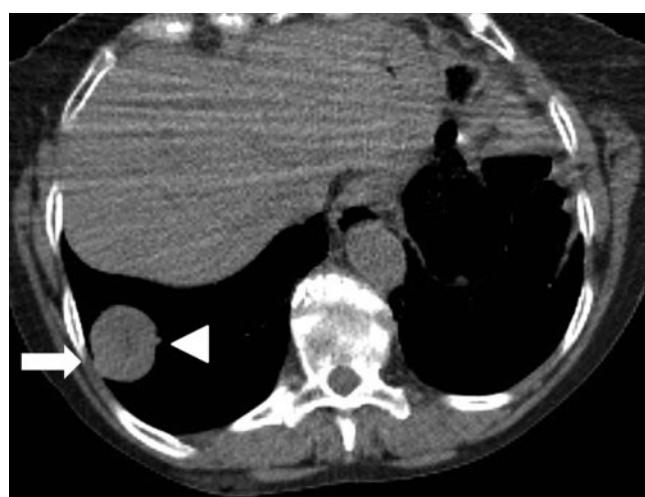A 74-year-old woman presented with haemoptysis. She had a history of intracranial meningioma, resected 22 years previously in 1985. The patient had undergone two further resections for intracranial local recurrence in 1988 and 1992 (3 years and 7 years following initial resection, respectively). A chest radiograph revealed

two well-circumscribed masses, one at each lung base without a pleural abnormality. CT scan of the thorax was performed and included unenhanced, arterial phase (25 s post-iv contrast administration) and portal venous-phase (75 s post-iv contrast administration) imaging (Figure 1). CT demonstrated two well-circumscribed rounded lesions, which were peripherally located in the lungs: a 3.8 cm mass in the right lower lobe and a second 2.7 cm mass in the left lower lobe. The lesions had low-density centres (21 HU) that did not significantly enhance post-iv contrast administration (29 HU in arterial and portal venous phase images). The periphery of the lesions enhanced from 50 HU on the unenhanced images to 111 HU on the arterial phase images and de-enhanced to 83 HU on portal venous-phase images. The periphery of these lesions, therefore, enhanced avidly post-iv contrast administration; the lesions were noted to have prominent feeding vessels in their walls, which were fed by branches of the inferior pulmonary veins. CT scan of the brain (pre and post iv contrast administration) showed no evidence of recurrent or metastatic disease.

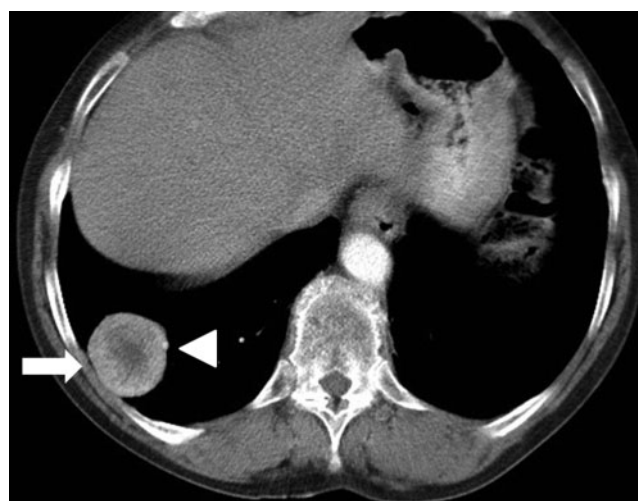Full-body combined fluoro-18-deoxyglucose (FDG) PET/CT imaging demonstrated avid FDG uptake within both lung lesions with standard uptake values (SUV) of 8.7 on the right and 7.1 on the left (Figure 2). There was slightly less FDG uptake in the centre of each lesion. There was no other focal area of uptake of FDG to suggest metastatic disease elsewhere.

The patient was referred for CT-guided percutaneous lung biopsy. Under fluoroscopic CT guidance, a 10-cm 19/20-gauge coaxial core biopsy needle system (Temno; Cardical Healthcare, Dublin, OH) was advanced into the larger of the two lesions located in the right lower lobe.

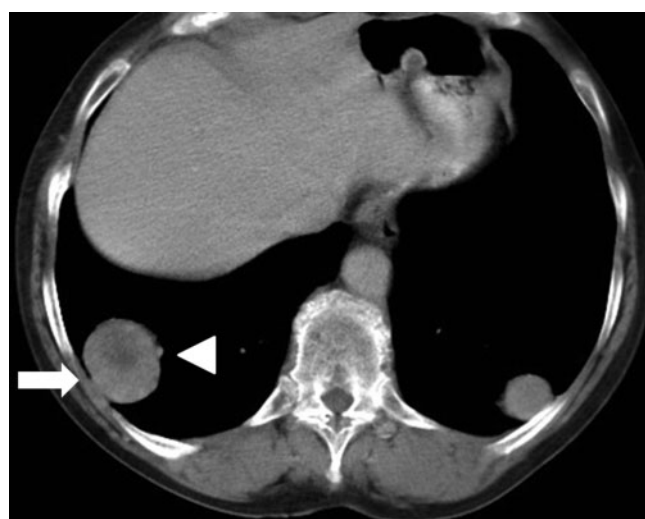
Address correspondence to: Professor Michael M Maher, Department of Radiology, Cork University Hospital, Wilton, Cork, Ireland. E-mail: m.maher@ucc.ie



(a)

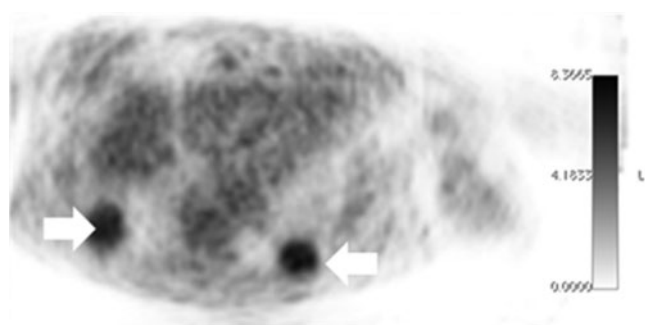


(b)

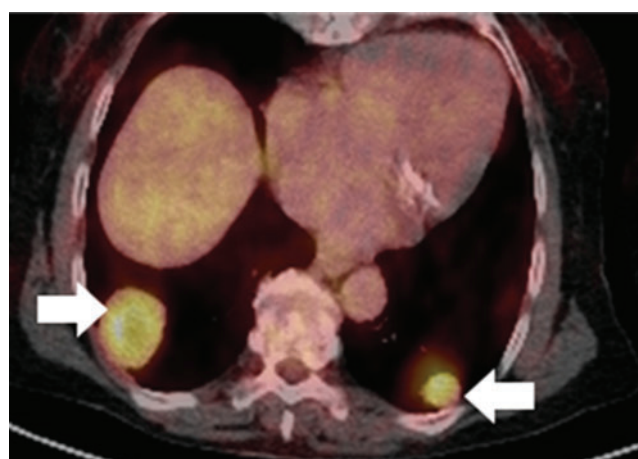


(c)

**Figure 1.** CT in (a) the control, (b) arterial and (c) portal venous phases post-iv contrast administration. There is a 3.8-cm well-circumscribed rounded lesion in the right lower lobe (arrow). Decreased attenuation is seen in the centre of the lesion. The lesion has a prominent feeding vessel in the wall (arrowhead), which was fed by a branch of the right inferior pulmonary vein.



(a)



(b)

**Figure 2.** (a, b) Full-body combined fluoro-18-deoxyglucose positron emission tomography (FDG-PET)/CT imaging demonstrated avid uptake of FDG within both lung lesions; standard uptake values were 8.7 on the right and 7.1 on the left. There was slightly decreased FDG uptake in the centre of the lesions.

Four cores of tissue were obtained. During the biopsy, the operators noted that the lesions were very vascular; however, there were no post-procedure complications. Histological examination demonstrated multiple foci of tumour within lung parenchyma, identical in appearance to the original intracranial meningioma. The original meningioma was parasagittal and all three intracranial specimens showed areas of necrosis indicating increased risk of recurrence (atypical meningioma WHO Grade II). The recurrent tumour in 1998 showed tumour invasion of the sagittal sinus. Both the original and metastatic tumour cells stained positive with antigens to both epithelial membrane antigen and vimentin, typical of meningiomas, on immunocytochemistry. Both the intracranial and metastatic tumour showed areas of central tumour necrosis. Repeat cranial imaging did not show any residual or recurrent neoplasm. The patient was reviewed by a cardiothoracic surgeon, who recommended surgical resection. The patient declined surgical intervention. On clinical follow-up 10 months following diagnosis of the pulmonary lesions, the patient was asymptomatic and had noted no further episodes of haemoptysis.

## Discussion

The majority of meningiomas are benign tumours of the central nervous system and arise from the leptomeninges [1, 3]. They account for approximately 25% of all intracranial tumours [1, 3]. Grade I meningiomas are regarded as benign, because of their slow growth and rare tendency to recur locally or metastasise [3, 4]. Grade II meningiomas, as reported in this case, have an increased risk of recurrence. The 5 year recurrence rate for meningiomas with benign histological features is approximately 3% [5]. Consequently, surgery is the treatment of choice and the only definitive cure [6].

Distant extracranial metastases from primary intracranial meningiomas have been previously described but are rare; the incidence of metastasis is less than 1 in 1000. Although primary meningiomas are 2–4 times more likely to occur in females, the male to female ratio of metastatic disease is 3:2 [7]. The reported age range for metastases is 1 week to 83 years, although 75% of cases are found in patients between 40 and 60 years of age [7]. A previous series reported the time from initial diagnosis to discovery of metastases to be approximately 5 years. Some 60% of extracranial metastases from meningioma are found in the lung, while the liver, lymph nodes and bone are less common sites [4, 8–11]. Haematogenous spread of tumour cells as a result of venous sinus invasion is the most likely mechanism of metastasis [12]. A second route of dissemination is through the cerebrospinal fluid, leading to tumour of the neuraxis [7].

Irrespective of the route of dissemination, 75% of patients with metastatic meningioma will have had previous surgery on the primary lesion [7]. As discussed above, venous sinus invasion is the most plausible explanation for the development of metastases. Parasagittal meningiomas have a higher rate of metastasis [6]. In our patient, the original intracranial meningioma was parasagittal and vascular invasion of the sagittal sinus was reported in the recurrent tumour removed in 1988. The most unusual

feature of our patient's presentation was the length of time to discovery of distant metastases. In our view, as invasion of the sagittal sinus was present in 1988 and there was no further evidence of intracranial disease since 1992, it is likely that pulmonary metastases were present for at least 15 years. The discovery of metastatic meningioma more than 20 years from initial diagnosis is extremely rare. The mean duration from initial diagnosis to development of metastases is 6 years, although there is one report from Japan of pulmonary metastatic meningioma 26 years post craniotomy [13, 14].

The imaging features of the metastases in this case are interesting. Firstly, there were only two nodules detectable on imaging. This is consistent with previous reports, which indicated that pulmonary metastases number more than three in only 13% of cases [15]. Rapid enhancement of pulmonary lesions post iv contrast, as seen in the present case, is similar to that of intracranial meningiomas. In this case, lesions were of lower attenuation centrally with poor central enhancement. A previous report by Yekeler et al [6] described the MRI features of pulmonary metastatic meningioma and reported higher signal intensity centrally on  $T_2$  weighted sequences, suggesting a central "cystic" component. The central "cystic" component for metastatic meningioma to lung had not been previously reported, but had been described with selected intracranial meningiomas [6]. In the current case, it is likely that the central low-density areas within both lesions seen on CT would show relative increased signal intensity on  $T_2$  weighted images when compared with the periphery, as described in the case report by Yekeler et al [6], especially in view of the central necrosis on histology.

There are few examples of the use of PET in the initial characterisation and surveillance of meningiomas. In 2007, Rutten et al [16] described the combination of CT and MRI as limited in the diagnosis of local skull involvement from adjacent intracranial meningioma. In their study, the authors demonstrated that skull-base tumours could be clearly visualised with  $^{18}\text{F}$ -tyrosine PET, even after radiation therapy [16, 17]. Primary intracranial meningioma is typically reported as having low FDG uptake, because glucose metabolism in meningioma is similar to that of surrounding tissue [15]. There have been a few isolated reports describing the imaging features of metastatic meningioma on FDG-PET imaging. Ghodsian et al [18] described a moderately hypermetabolic sacral metastatic mass by FDG-PET/CT. This was a Grade III malignant meningioma on histology. Meirelles et al [19] recently described a pulmonary meningioma that manifested as a solitary pulmonary nodule and had very high metabolic activity on PET scan. The current case also showed avid uptake of FDG; the SUV was  $>7$  in each pulmonary lesion. The uptake was more avid in the periphery and slightly less in the centre of both lesions, corresponding to the central areas of low density on CT. It was useful to note that there were no other foci of abnormal FDG uptake elsewhere to suggest other metastases. It is reassuring to note that 10 months after the PET/CT with clinical follow-up, the patient remains asymptomatic with no evidence of local or distant spread. The diagnosis of pulmonary metastatic meningioma was confirmed histologically by CT-guided percutaneous biopsy, which has been



previously reported [20]. This diagnosis enabled the cardiothoracic surgeon to discuss treatment options with the patient, confident that he was dealing with metastatic meningioma. In this case the patient declined surgical resection and remains asymptomatic.

## Conclusion

Metastatic meningioma is a rare cause of pulmonary mass. The present case demonstrates one such case in which the metastatic lesions have decreased attenuation centrally with higher attenuation peripherally and avid peripheral enhancement following intravenous contrast administration on CT. A feeding vessel was identified on CT and on FDG-PET both lesions were found to be FDG-avid, particularly peripherally.

## References

- Louis D, Ohgaki H, Wiestler OD, Cavenee WK, Burger PC, Jouvet A, et al. The 2007 World Health Organization classification of tumours of the central nervous system. *Acta Neuropathol* 2007;114:97–109.
- Rockhill J, Mrugala M, Chamberlain MC. Intracranial meningiomas: an overview of diagnosis and treatment. *Neurosurg Focus* 2007;23:E1.
- Norden AD, Drappatz J, Wen PY. Advances in meningioma therapy. *Curr Neurol Neurosci Rep* 2009;9:231–40.
- Asioli S, Senetta R, Maldi E, D'Ambrosio E, Satolli MA, Bussolati G, et al. "Benign" metastatic meningioma: clinicopathological analysis of one case metastasising to the lung and overview on the concepts of either primitive or metastatic meningiomas of the lung. *Virchows Arch* 2007;450:591–4.
- Saleman M. Malignant meningiomas. In: al-Mefty O, editor. *Meningiomas*. New York: Raven, 1995:50–74.
- Yekeler E, Dursun M, Yilmazbayhan D, Tunaci A. Multiple pulmonary metastases from intracranial meningioma: MR imaging findings. *Diagn Interv Radiol* 2005;11:28–30.
- Fulkerson DH, Horner TG, Hattab EM. Histologically benign intraventricular meningioma with concurrent pulmonary metastasis: case report and review of the literature. *Clin Neurol Neurosurg* 2008;110:416–19.
- Figuerola BE, Quint DJ, McKeever PE, Chandler WF. Extracranial metastatic meningioma. *Br J Radiol* 1999;72:513–16.
- Falleni M, Roz E, Dessy E, Del Curto B, Braidotti P, Gianelli U, Pietra GG. Primary intrathoracic meningioma: histopathological, immunohistochemical and ultrastructural study of two cases. *Virchows Arch* 2001;439:196–200.
- Kodama K, Osamu D, Higashiyama M, Horai T, Tateishi R, Nakagawa H. Primary and metastatic pulmonary meningioma. *Cancer* 1991;67:1412–17.
- Karasick JL, Mullan SF. A survey of metastatic meningiomas. *J Neurosurg* 1974;40:206–12.
- Keppes JJ. Meningiomas: Biology, pathology and differential diagnosis. In: Masson monographs in diagnostic pathology, vol 4. New York: Masson, 1982:190–200.
- Stoller JK, Kavuru M, Mehta AC, Weinstein CE, Estes ML, Gephardt GN. Intracranial meningioma metastatic to the lung. *Cleve Clin J Med* 1987;54:521–7.
- Ishibashi H, Ohta S, Hirose M, Furuhashi K, Suzuki M, Nakajima N. Pulmonary metastatic meningioma 26-years after craniotomy. *Kyobu Geka* 2008;61:478–81.
- Kaminski JM, Movsas B, King E, Yang C, Kronz JD, Alli PM, et al. Metastatic meningioma to the lung with multiple pleural metastases. *Am J Clin Oncol* 2001;24:579–82.
- Rutten I, Cabay JE, Withofs N, Lemaire C, Aerts J, Baart V, et al. PET/CT of skull base meningiomas using 2-18F-fluoro-L-tyrosine: initial report. *J Nucl Med* 2007;48:720–5.
- Conti PS, Cham DK, editors. *PET/CT: a case based approach book*. Singapore: Springer, 2005:472.
- Ghodsian M, Obrzut SL, Hyde CC, Watts WJ, Schiepers C. Evaluation of metastatic meningioma with 2-deoxy-2-[18F] fluoro-D-glucose PET/CT. *Clin Nucl Med* 2005;30:717–20.
- Meirelles GS, Ravizzini G, Moreira AL, Akhurst T. Primary pulmonary meningioma manifesting as a solitary pulmonary nodule with a false-positive PET scan. *J Thorac Imaging* 2006;21:225–7.
- Kovoor JM, Jayakumar PN, Srikanth SG, Indira B, Devi MG. Solitary pulmonary metastasis from intracranial meningiothelial meningioma. *Australasian Radiol* 2002;46:65–8.