

Title	Anakinra for recalcitrant pyoderma gangrenosum
Authors	O'Connor, Cathal;Gallagher, Catriona;Hollywood, Aoife;Paul, Lindsay;O'Connell, Michael
Publication date	2021-06-16
Original Citation	O'Connor, C., Gallagher, C., Hollywood, A., Paul, L. and O'Connell, M. (2021) 'Anakinra for recalcitrant pyoderma gangrenosum', Clinical and Experimental Dermatology. doi: 10.1111/ced.14809
Type of publication	Article (peer-reviewed)
Link to publisher's version	10.1111/ced.14809
Rights	© 2021, the Authors. Clinical and Experimental Dermatology published by John Wiley & Sons Ltd on behalf of the British Association of Dermatologists. This is an open access article under the terms of the Creative Commons Attribution License, which permits use, distribution and reproduction in any medium, provided the original work is properly cited. - https://creativecommons.org/licenses/by/4.0/
Download date	2025-08-02 02:18:25
Item downloaded from	https://hdl.handle.net/10468/11763

Anakinra for recalcitrant pyoderma gangrenosum

C. O'Connor,^{1,2}  C. Gallagher,¹  A. Hollywood,¹  L. Paul¹  and M. O'Connell¹¹Department of Dermatology, University Hospital Waterford, Waterford, Ireland; and ²Department of Medicine, University College Cork, Cork, Ireland

doi:10.1111/ced.14809

Summary

Pyoderma gangrenosum (PG) is an autoinflammatory neutrophilic dermatosis characterized by rapidly enlarging, painful ulcers. Anakinra is a recombinant interleukin (IL)-1 receptor antagonist that blocks the activity of IL-1 α and IL-1 β by competitively inhibiting IL-1 binding to the IL-1 type 1 receptor. We present a series of two patients with recalcitrant PG, who had limited therapeutic options and multiple comorbidities and multiple previous treatment failures, who obtained 100% healing with anakinra. Compared with conventional first-line therapies for PG, the safety profile of anakinra may be preferable for patients with multiple comorbidities. Further research is needed to assess the safety and efficacy of anakinra for PG.

Pyoderma gangrenosum (PG) is an autoinflammatory neutrophilic dermatosis characterized by rapidly enlarging, painful ulcers.¹ Half of patients with PG have an underlying inflammatory disease.² Anakinra is a recombinant interleukin (IL)-1 receptor antagonist that blocks the activity of IL-1 α and IL-1 β .³ We present a series of two patients treated with anakinra for recalcitrant PG.

Report

Patient 1, a 51-year-old woman with a history of obesity, was referred with painful inframammary and inguinal ulceration (Fig. 1a,b). Skin biopsy showed neutrophilic infiltration of the epidermis, consistent with PG. Haematological investigations detected positive lupus anticoagulant, β 2-glycoprotein and anticardiolipin antibodies, consistent with antiphospholipid syndrome, in the context of three previous miscarriages. There was no family history of neutrophilic dermatoses.

Therapy with prednisolone 80 mg produced rapid clinical improvement. However, relapse occurred with minimal reduction in dosage. Ciclosporin provided

modest effect, but had to be withdrawn after 1 month due to nephrotoxicity. Infliximab was stopped following secondary failure. Complications related to these therapies had included recurrent herpes zoster, multidrug-resistant urinary tract infections and steroid-induced diabetes mellitus.

Inpatient hospital admission was required for intravenous methylprednisolone, followed by intravenous immunoglobulin (IVIG) and rituximab infusions, which delivered significant benefit for almost 1 year. At that time, the disease relapsed severely, and rituximab and IVIG were stopped.

Mycophenolate mofetil and doxycycline were then trialled with minimal effect. The patient's quality of life had deteriorated substantially and she required assisted accommodation because of immobility. Owing to progressive disease with an associated renal injury requiring dialysis, further inpatient admission was required for intravenous methylprednisolone. Efficacy was achieved with oral cyclophosphamide but this was stopped after 9 months due to nausea and concerns about long-term safety.

Given the patient's history of treatment-resistant disease, therapy with anakinra was initiated, with 4 weeks of loading at 2 mg/kg daily, followed by 100 mg once daily. This agent had a rapid and profound effect on symptoms, with 100% healing after 4 months of treatment. Clinical improvement facilitated a slow withdrawal of prednisolone after 4 years of continuous oral steroid therapy. The patient's

Correspondence: Dr Cathal O'Connor, Department of Dermatology, University Hospital Waterford, Dunmore Road, Waterford X91 ER8E, Ireland
E-mail: drcathaloconnor@gmail.com

Conflict of interest: the authors declare that they have no conflicts of interest.

Accepted for publication 15 June 2021

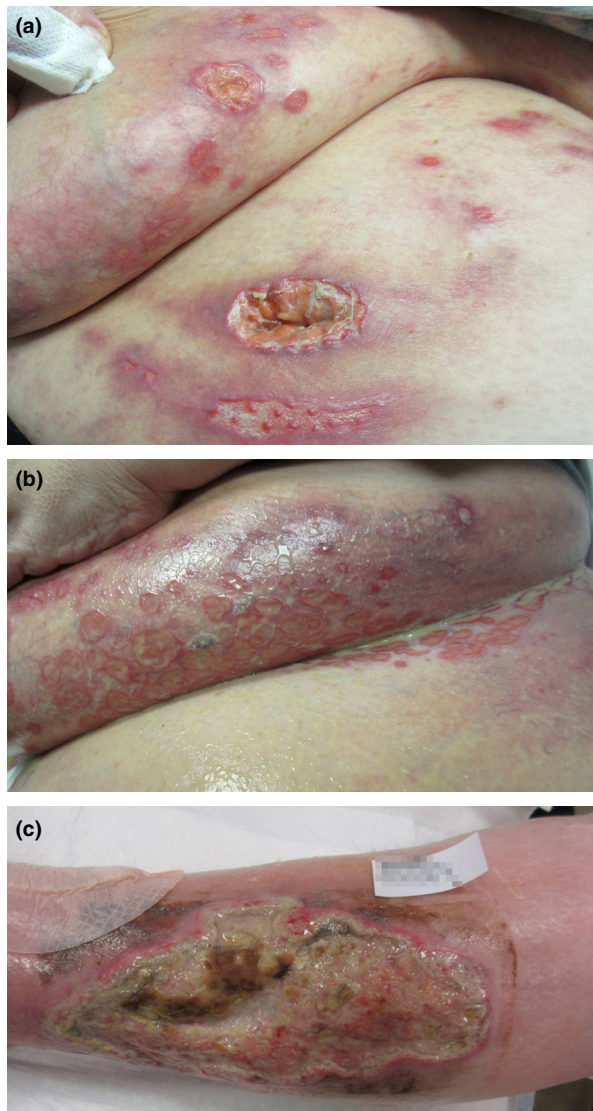


Figure 1 (a,b) Patient 1: (a) multiple ulcerations with violaceous undermined edges on the breast and inframammary area; (b) extensive ulceration in the inguinal folds with slough. (c) Patient 2: deep ulceration on the pretibial area with an undermined violaceous edge and granulation tissue.

iatrogenic diabetes requiring insulin has reversed and she is now off all diabetic medication. She intentionally lost 22 kg in the first 4 months of treatment. Her PG remains in remission, 24 months following initiation of IL-1 blockade.

Patient 2 was a 67-year-old woman who was referred with severe painful ulceration on her legs (Fig. 1c). She was on adalimumab and methotrexate for rheumatoid arthritis (RA). She also had a history of chronic kidney disease, hypertension, peripheral vascular disease and

dyslipidaemia. Oral prednisolone 45 mg daily was started with good initial effect; however, the following month, the patient was admitted to the hospital with an upper gastrointestinal (GI) bleed. Upper GI endoscopy showed gastric and duodenal ulceration, and the patient was placed on a protein pump inhibitor (PPI). Second-line therapeutic strategies were limited by the patient's multiple comorbidities, and there was concern about prescribing ciclosporin given her pre-existing renal disease. The patient declined infliximab infusions because she was unable to access regular transport to hospital. Owing to the patient's severe disease, her multiple comorbidities and the fact that anakinra is licensed for RA, anakinra was introduced, and adalimumab and methotrexate were stopped. Her PG slowly stabilized, with 50% reduction in ulcer size after 6 months and 100% healing after 12 months. Repeat upper GI endoscopy showed healing of the peptic ulcers following 2 months of PPI therapy. Oral prednisolone was tapered to stop over 8 months. Both the PG and RA remain quiescent 24 months following initiation of IL-1 blockade.

PG is a rare disease with an incompletely understood aetiology.¹ A 2018 Delphi consensus provided updated diagnostic criteria for PG.⁴ Misdiagnosis is frequent and associated conditions often go undetected.² Treatment of PG remains largely anecdotal, with only two published randomized controlled trials.^{5,6} With no national or international guidelines, management is challenging. Treatment choice is based on the severity and extent of PG and patient comorbidities.² Up to 30% of patients with PG have underlying inflammatory bowel disease (IBD), higher than the rate of 20% in the UK population reported by Langan *et al.*⁷ Pustular and peristomal variants of PG are more commonly seen in patients who also have IBD. Inflammatory arthritis is present in approximately 10% of patients. Solid organ malignancy is seen in 5% of patients, while haematological malignancy is present in < 5% and is more frequently associated with the bullous variant. PG can be seen in up to 15% of patients with antiphospholipid syndrome, with localized thrombosis thought to precipitate the secondary inflammatory reaction.⁸ Other conditions such as cryoglobulinaemia are only rarely associated with PG. A three-fold increased risk of premature death has been identified in patients with PG in the UK.⁷

Currently, PG is considered a neutrophil-mediated autoinflammatory disease, involving aberrant activation of the inflammasome. This is supported by recent studies that have provided novel insight into innate immune system mutations and upregulation of the Janus kinase signalling pathway in lesional skin. Other factors include involvement of the adaptive immune

system, and external triggers such as pathergy and genetic predisposition. It is poorly understood how these factors interact to influence the disease.

Several monogenic autoinflammatory diseases associated with PG are caused by mutations in genes that upregulate activity of IL-1, such as *PSTPIP1*,⁹ causing PAPA syndrome (pyogenic arthritis, pyoderma gangrenosum and acne) and PASH syndrome (pyoderma gangrenosum, acne and suppurative hidradenitis). The *PSTPIP1* mutant inhibits the anti-inflammatory effect of pyrin, leading to release of proinflammatory cytokines such as IL-1 β , IL-6, IL-8 and tumour necrosis factor (TNF)- α , further amplifying the inflammatory response. These conditions respond favourably to IL-1 blockade, providing a theoretical basis for the use of anakinra in nonsyndromic PG. Other case series have highlighted the role of IL-1-driven inflammation in autoimmune disease-associated PG.¹⁰

Our case series shows that excellent response to anakinra is possible despite multiple previous drug failures. Conventional first-line therapies for PG such as high-dose corticosteroids, ciclosporin and TNF- α inhibition may be problematic due to adverse events (AEs) in the context of other inflammatory conditions or comorbidities. However, anakinra is associated with low rates of serious AEs.³ Further research is needed to assess the safety and efficacy of anakinra for nonsyndromic PG.

Acknowledgement

We thank the patients for their written informed consent to the publication of their case details.

Learning points

- PG is an autoinflammatory neutrophilic dermatosis characterized by rapidly enlarging, painful ulcers.
- Half of patients with PG have an underlying inflammatory disease; approximately 30% have IBD, 10% have inflammatory arthritis, 5% have haematological malignancy and 5% have solid organ malignancy.
- Patients with PG in the UK have been shown to have a three-fold increased risk of premature death.
- Several monogenic autoinflammatory diseases associated with PG are caused by mutations in genes that upregulate the activity of interleukin (IL)-1, such as *PSTPIP1*, causing PAPA syndrome and PASH syndrome.

- Anakinra is a recombinant IL-1 receptor antagonist that blocks the activity of IL-1 α and IL-1 β by competitively inhibiting IL-1 binding to the IL-1 type 1 receptor, which is expressed in a wide variety of tissues and organs.
- The safety profile of anakinra may be preferable to conventional treatments, such as corticosteroids or ciclosporin, for patients with multiple comorbidities, but further research is needed to assess the safety and efficacy of anakinra for PG.

References

- 1 Ahn C, Negus D, Huang W. Pyoderma gangrenosum: a review of pathogenesis and treatment. *Expert Rev Clin Immunol* 2018; **14**: 225–33.
- 2 Teagle A, Hargest R. Management of pyoderma gangrenosum. *J R Soc Med* 2014; **107**: 228–36.
- 3 Kullenberg T, Löfqvist M, Leinonen M *et al.* Long-term safety profile of anakinra in patients with severe cryopyrin-associated periodic syndromes. *Rheumatology (Oxford)* 2016; **55**: 1499–506.
- 4 Maverakis E, Ma C, Shinkai K *et al.* Diagnostic criteria of ulcerative pyoderma gangrenosum: a Delphi consensus of international experts. *JAMA Dermatol* 2018; **154**: 461–6.
- 5 Ormerod AD, Thomas KS, Craig FE *et al.* Comparison of the two most commonly used treatments for pyoderma gangrenosum: results of the STOP GAP randomised controlled trial. *BMJ* 2015; **350**: jh2958.
- 6 Brooklyn TN, Dunnill MG, Shetty A *et al.* Infliximab for the treatment of pyoderma gangrenosum: a randomised, double blind, placebo controlled trial. *Gut* 2006; **55**: 505–9.
- 7 Langan SM, Groves RW, Card TR, Gulliford MC. Incidence, mortality, and disease associations of pyoderma gangrenosum in the United Kingdom: a retrospective cohort study. *J Invest Dermatol* 2012; **132**: 2166–70.
- 8 Cañas CA, Durán CE, Bravo JC *et al.* Leg ulcers in the antiphospholipid syndrome may be considered as a form of pyoderma gangrenosum and they respond favorably to treatment with immunosuppression and anticoagulation. *Rheumatol Int* 2010; **30**: 1253–7.
- 9 Alavi A, French LE, Davis MD *et al.* Pyoderma gangrenosum: an update on pathophysiology, diagnosis and treatment. *Am J Clin Dermatol* 2017; **18**: 355–72.
- 10 Beynon C, Chin MF, Hunasehally P *et al.* Successful treatment of autoimmune disease-associated pyoderma gangrenosum with the IL-1 receptor antagonist anakinra: a case series of 3 patients. *J Clin Rheumatol* 2017; **23**: 181–3.