

Title	Pembrolizumab-induced follicular eruption and response to isotretinoin
Authors	O'Connor, Cathal;Power, Derek G.;Gleeson, Catherine;Heffron, Cynthia
Publication date	2021-11-17
Original Citation	O'Connor, C., Power, D.G., Gleeson, C. and Heffron, C. (2022) 'Pembrolizumab-induced follicular eruption and response to isotretinoin', Immunotherapy, 14(3), pp. 179–184. doi: 10.2217/imt-2021-0001.
Type of publication	Article (peer-reviewed)
Link to publisher's version	https://doi.org/10.36349/easjpbs.2022.v04i05.002 - 10.2217/imt-2021-0001
Rights	© 2021 Future Medicine Ltd
Download date	2025-04-29 00:58:45
Item downloaded from	https://hdl.handle.net/10468/13802



UCC

University College Cork, Ireland
Coláiste na hOllscoile Corcaigh



Pembrolizumab-induced follicular eruption and response to isotretinoin

Journal:	<i>Immunotherapy</i>
Manuscript ID	IMT-2021-0001.R1
Manuscript Type:	Case Report
Keywords:	Antibody therapeutics, Dermatology, Checkpoint Inhibitors

SCHOLARONE™
Manuscripts

Abstract

Background: Pembrolizumab is a monoclonal antibody targeting programmed cell death receptor-1 (PD-1). Folliculitis secondary to pembrolizumab has rarely been reported in the treatment of malignant melanoma (MM).

Case: A 49 year old with a history of mild lower limb folliculitis developed metastatic MM, and immunotherapy with pembrolizumab was initiated. Following 19 doses of pembrolizumab, a folliculocentric pustular eruption developed on the lower legs. Biopsy was consistent with folliculitis. Treatment with topical corticosteroids, high dose prednisolone, lymecycline, clarithromycin, trimethoprim, and clindamycin was unsuccessful. Pembrolizumab was stopped after 22 cycles, but the folliculitis persisted. Oral isotretinoin was required for disease control.

Discussion: Drug-induced follicular eruptions have rarely been described with anti PD-1 therapy. Isotretinoin may be required to achieve remission.

First draft submitted: 05 January 2021; Accepted for publication: 28 October 2021; Published online: TBC

Lay Abstract

Pembrolizumab (trade name Keytruda) is a type of immune therapy that stimulates the body's immune system to fight cancer cells. This immune therapy can cause a variety of rashes. In this article, we describe a patient who developed a rash around hair follicles that is not commonly described with pembrolizumab. A man with a history of mildly infected hair follicles on his legs was diagnosed with advanced melanoma and was treated with pembrolizumab. After 19 treatments, he developed a rash on his legs, centered around hair follicles. Treatment with steroid ointments, steroid tablets, and antibiotic tablets was not helpful. Pembrolizumab was stopped, but the rash persisted. A medicine called isotretinoin was required to control the rash. This type of

1
2
3 rash has rarely been described with this kind of immune therapy, and isotretinoin might
4
5 be required to treat it.
6
7
8
9

10 **Key words**

11
12 Folliculitis; acneiform eruption; adverse drug reactions; pembrolizumab; melanoma
13
14
15
16

17 **Case Presentation**

18
19
20
21 Pembrolizumab is a monoclonal antibody that targets programmed cell death
22
23 receptor-1 (PD-1) [1]. It is used in the treatment of several malignancies including
24
25 malignant melanoma (MM), non-small cell lung cancer, head and neck squamous cell
26
27 carcinoma, and urothelial carcinoma [2]. Adverse cutaneous effects are common
28
29 (approximately 40%) with pembrolizumab and may reflect an enhanced therapeutic
30
31 response in the treatment of MM [3]. Folliculitis or acneiform eruptions secondary to
32
33 pembrolizumab have rarely been reported.
34
35
36
37
38
39

40 A 49-year-old man had a 1.4mm Breslow thickness, non-ulcerated MM excised from
41
42 his right arm in 2012. Wide local excision and sentinel lymph node biopsy were
43
44 negative for MM. Mild lower limb folliculitis was noted on melanoma follow up in 2015,
45
46 which resolved with topical therapy. Right axillary lymphadenopathy developed in
47
48 2016 and fine needle aspiration of a lymph node was consistent with metastatic MM,
49
50 which was BRAF V600 wild type. Radiological staging in 2016 demonstrated
51
52 pulmonary metastases and further imaging in 2017 showed suprarenal metastases.
53
54 In 2017, immunotherapy with pembrolizumab was initiated.
55
56
57
58
59
60

1
2
3 Following his 19th dose of pembrolizumab, a folliculocentric eruption with some
4 follicular pustules developed on the lower legs (Figure 1A and 1B). The folliculitis did
5 not extend distally to involve skin covered with socks. Skin biopsy showed a striking
6 acute and chronic folliculitis and perifolliculitis as illustrated (Figures 2A-2C). In
7 addition, there was a prominent superficial perivascular lymphocytic infiltrate as well
8 as some lichenoid changes suggestive of lichen simplex chronicus.
9

10
11 The extensive follicular eruption, coupled with some elements of a lymphocytic
12 folliculitis on histology, was consistent with a follicular lichenoid drug reaction. An
13 infective aetiology was also considered considering his previous history of bacterial
14 folliculitis. However, treatment with topical corticosteroids and oral prednisolone 60mg
15 (0.75mg/kg) once daily for four weeks provided minimal benefit. Given the lack of
16 response to immunosuppression, a bacterial aetiology was reconsidered. A trial of oral
17 lymecycline (408mg once daily for three months) was unsuccessful. The folliculitis
18 deteriorated with further doses of pembrolizumab (Figure 3). Immunotherapy was
19 stopped after 22 cycles, and the eruption improved but persisted. Repeat biopsy was
20 similar to prior biopsies with an acute and chronic folliculitis and perifolliculitis. Oral
21 clarithromycin (500mg twice daily) and trimethoprim (300mg twice daily) were
22 unhelpful. Oral clindamycin (300mg twice daily) provided some improvement. Despite
23 the sparing of folliculitis in areas under compression by regular socks, prescribed
24 compression stockings were not helpful.
25
26
27
28
29
30
31
32
33
34
35
36
37
38
39
40
41
42
43
44
45
46
47
48
49
50
51

52 Ultimately oral isotretinoin was required for disease control. Initially isotretinoin (20mg
53 once daily) was combined with clindamycin, with significant improvement. Clindamycin
54 was then withdrawn, with sustained improvement on isotretinoin monotherapy (30mg
55
56
57
58
59
60

1
2
3 once daily). Following twelve months of therapy with isotretinoin, the follicular eruption
4
5 has remained quiescent. Recent repeat imaging showed no new lesions.
6
7
8
9

10 **Discussion**

11
12
13
14 Pembrolizumab is a humanized monoclonal IgG4 antibody approved for the therapy
15
16 of several malignancies, including MM [1]. Disruption of the PD-1 receptor and PD-1
17
18 ligands (PDL-1) permits engagement of T-cells in cytotoxic anti-cancer effects [4].
19
20 Therefore, it acts as an immune checkpoint inhibitor and has shown significant survival
21
22 benefits in patients with advanced MM [5].
23
24
25
26
27

28
29 Approximately 40% of patients develop cutaneous adverse effects with
30
31 pembrolizumab, with maculopapular eruptions, pruritus, and hypopigmentation being
32
33 most commonly seen [3]. However, potentially life-threatening reactions such as
34
35 Stevens-Johnson syndrome have been reported [6]. Hypopigmentation is more
36
37 frequently seen in patients treated for MM [7]. The development of cutaneous adverse
38
39 effects, especially hypopigmentation in patients with MM, is associated with
40
41 significantly longer progression-free intervals [3].
42
43
44
45
46

47
48 Drug-induced follicular eruptions have been described with oral corticosteroids,
49
50 androgenic hormones, EGFR inhibitors, calcineurin inhibitors, lithium, and
51
52 anticonvulsants [8]. However, the clinical presentations vary significantly according to
53
54 the causative drug. Corticosteroid- and androgen-induced follicular eruptions mainly
55
56 manifest as monomorphic pustules, whereas the follicular eruption associated with
57
58 EGFR inhibitors is not monomorphic and is associated with significant pruritus and
59
60

1
2
3 crust formation. The variations in clinical manifestations may be due to effects on toll-
4 like receptors, [9] keratinocyte differentiation, [10] or neutrophil chemotaxis [11]. Drug-
5 induced follicular eruptions have rarely been reported with anti PD-1 therapy, although
6 they have been described with cytotoxic T-lymphocyte-associated antigen 4 (CTLA-4)
7 immunotherapy with ipilimumab [12].
8
9
10
11
12
13
14
15
16

17 While drug-induced follicular or acneiform eruptions usually occur relatively quickly
18 following initiation of treatment, delayed presentations may occur, particularly with
19 complex biologic medicines such as pembrolizumab. The temporal improvement in
20 folliculitis with cessation of pembrolizumab is also supportive of drug-induced
21 aetiology. The follicular eruption in this case was strikingly monomorphic and
22 inflammatory, with a lack of comedones and cysts, typical of drug-induced folliculitis.
23 It was also unusually severe and resistant to therapy, given that previous folliculitis
24 had been very mild and responsive to basic topical antimicrobial therapy. This eruption
25 may have represented an exacerbation of previous folliculitis or a *de novo* follicular
26 eruption with superimposed bacterial folliculitis. In either case, pembrolizumab had a
27 temporal relationship with its development and exacerbation.
28
29
30
31
32
33
34
35
36
37
38
39
40
41
42
43
44

45 Lichenoid eruptions have been well-described in relation to anti-PD1 therapy, [13] but
46 not in a folliculocentric pattern. There are also reports of neutrophilic dermatoses in
47 patients on anti-PD1 immunotherapy [14-16]. This unusual presentation could fit with
48 a follicular lichenoid reaction with some neutrophilic folliculitis. This might explain the
49 poor response to antibiotics and the success seen with isotretinoin. Retinoids can be
50 beneficial in treating lichenoid drug reactions, especially if the drug reaction is
51 persistent of if continued therapy with the causative drug is necessary [17]. Retinoids
52
53
54
55
56
57
58
59
60

1
2
3 modify keratinocyte differentiation and are therefore useful in disorders of
4
5 keratinization such as acneiform eruptions [18]. Additionally, the previous history of
6
7 folliculitis could explain why some of the follicles showed pustules and neutrophils on
8
9 biopsy during the anti-PD1 treatment.
10
11
12

13
14 Cessation of the causative drug or switching to an alternative agent should be
15
16 considered when there is significant impairment related to follicular drug eruptions.
17
18 However, persistence of the cutaneous eruption can be seen, especially with drugs
19
20 with a long half-life such as pembrolizumab [19]. Treatment of persistent follicular
21
22 eruptions can be difficult. Tetracyclines may be useful when used prophylactically [20]
23
24 but isotretinoin may be required to achieve remission [21].
25
26
27
28
29

30
31 This case highlights the difficulties in ascertaining the underlying aetiology of follicular
32
33 eruptions with immunotherapy and supports the early use of retinoids for persistent
34
35 follicular eruptions with anti-PD1 therapy.
36
37
38
39

40 **Summary Points**

- 41
- 42
- 43
- 44
- 45 • Pembrolizumab is a monoclonal antibody that targets programmed cell death
- 46 receptor-1 (PD-1).
- 47
- 48
- 49 • Adverse cutaneous effects are common (approximately 40%) with pembrolizumab
- 50 and may reflect an enhanced therapeutic response.
- 51
- 52
- 53
- 54 • Folliculitis or acneiform eruptions secondary to pembrolizumab have rarely been
- 55 reported.
- 56
- 57
- 58
- 59
- 60

- We report a 49-year-old man with metastatic melanoma who developed a folliculocentric pustular eruption following 19 doses of pembrolizumab.
- The clinical and histological features shared overlap between a lichenoid and neutrophilic folliculitis, complicating categorization.
- Treatment with oral corticosteroids and oral antibiotics was unhelpful.
- Treatment with oral isotretinoin was rapidly beneficial, which may be due to its modification of keratinocyte differentiation.
- Management of pembrolizumab-induced folliculitis can be difficult, and oral retinoids should be considered as an early option to induce remission.

Financial & competing interests disclosure

The authors have no relevant affiliations or financial involvement with any organization or entity with a financial interest in or financial conflict with the subject matter or materials discussed in the manuscript. This includes employment, consultancies, honoraria, stock ownership or options, expert testimony, grants, or patents received or pending, or royalties.

No writing assistance was utilized in the production of this manuscript.

Ethical conduct of research

The authors state that they have obtained verbal and written informed consent from the patient/patients for the inclusion of their medical and treatment history within this case report.

Figure Legends

Figure 1A-B

Perifollicular papulopustular eruption of lower legs with sparing of skin where socks were providing pressure.

Figure 2A-C

A – Low power view of skin biopsy with hair follicle plugged with neutrophils and surrounding dermis with an acute and chronic inflammatory infiltrate.

B – High power view of hair follicle with acute folliculitis highlighting the neutrophilic infiltration of the follicular epithelium and neutrophilic infiltrate and hair shaft within the follicle

C – High power view of hair follicle with acute folliculitis and perifolliculitis with the overlying epidermis showing some epidermal hyperplasia, hyperkeratosis and changes of lichen simplex chronicus

Figure 3

Progression of folliculitis with further cycles of pembrolizumab, showing almost confluent erythema of the anterior shins.

References

1. Robert C, Soria JC, Eggermont AM. Drug of the year: programmed death-1 receptor/programmed death-1 ligand-1 receptor monoclonal antibodies. *Eur. J. Cancer* 49(14), 2968-2971 (2013).
2. Merck. Annex 1: Summary of Product Characteristics. Keytruda. www.ema.europa.eu/en/documents/product-information/keytruda-epar-product-information_en.pdf
3. Sanlorenzo M, Vujic I, Daud A *et al.* Pembrolizumab cutaneous adverse events and their association with disease progression. *JAMA Dermatol.* 151(11), 1206-1212 (2015). ***This article provides real-world data on the prevalence and types of adverse skin reactions seen with pembrolizumab.**
4. Sahni S, Valecha G, Sahni A. Role of anti-PD-1 antibodies in advanced melanoma: the era of immunotherapy. *Cureus* 10(12), e3700 (2018). ***This article provides a key overview of anti-PD1 immunotherapy in the treatment of melanoma.**
5. Hamid O, Robert C, Daud A *et al.* Five-year survival outcomes for patients with advanced melanoma treated with pembrolizumab in KEYNOTE-001. *Ann. Oncol.* 30(4), 582-588 (2019).
6. O'Connor C, Jordan E, O'Connell M. Atypical Stevens–Johnson syndrome caused by pembrolizumab in the treatment of metastatic melanoma – Are corticosteroids a safe treatment option? *J. Dermatol. Surg.* 24, 137-139 (2020).
7. Dai J, Belum VR, Wu S, Sibaud V, Lacouture ME. Pigmentary changes in patients treated with targeted anticancer agents: A systematic review and meta-analysis. *J. Am. Acad. Dermatol.* 77(5), 902-910.e2 (2017).

- 1
2
3 8. Du-Thanh A, Kluger N, Bensalleh H, Guillot B. Drug-induced acneiform eruption.
4
5 12(4), 233-245 (2011). ***This article provides a deep review of acneiform drug**
6
7 **eruptions.**
- 8
9
10 9. Shibata M, Katsuyama M, Onodera T, Ehama R, Hosoi J, Tagami H.
11
12 Glucocorticoids enhance toll-like receptor 2 expression in human keratinocytes
13
14 stimulated with propionibacterium acnes or proinflammatory cytokines. *J. Invest.*
15
16 *Dermatol.* 129(2), 375-382 (2009).
- 17
18
19 10. Vedak P, John JS, Kroshinsky D. Review and management of acneiform eruptions
20
21 in patients with immune disorders. *Am. J. Clin. Dermatol.* 18(3), 333-341 (2017).
- 22
23
24 11. Yeung CK, Chan HH. Cutaneous adverse effects of lithium. *Am. J. Clin. Dermatol.*
25
26 5(1), 3-8 (2004).
- 27
28
29 12. Dika E, Ravaioli GM, Fanti PA *et al.* Cutaneous adverse effects during ipilimumab
30
31 treatment for metastatic melanoma: a prospective study. *Eur. J. Dermatol.* 27(3),
32
33 266-270 (2017).
- 34
35
36 13. Coscarart A, Martel J, Lee MP, Wang AR. Pembrolizumab-induced
37
38 pseudoepitheliomatous eruption consistent with hypertrophic lichen planus. *J.*
39
40 *Cutan. Pathol.* 47(3), 275-279 (2020).
- 41
42
43 14. Ravi V, Maloney NJ, Worswick S. Neutrophilic dermatoses as adverse effects of
44
45 checkpoint inhibitors: A review. *Dermatol. Ther.* 32(5), e13074 (2019).
- 46
47
48 15. Matsubara T, Uchi H, Haratake N *et al.* Acute generalized exanthematous
49
50 pustulosis caused by the combination of pembrolizumab plus chemotherapy in a
51
52 patient with squamous-cell carcinoma. *Clin. Lung Cancer* 21(2), e54-e56 (2020).
- 53
54
55 16. De Bock M, Hulstaert E, Kruse V, Brochez L. Psoriasis vulgaris exacerbation
56
57 during treatment with a PD-1 checkpoint inhibitor: case report and literature
58
59 review. *Case Rep. Dermatol.* 10(2), 190-197 (2018).
- 60

- 1
2
3 17. Dalmau J, Peramiqel L, Puig L, Fernández-Figueras MT, Roé E, Alomar A.
4
5 Imatinib-associated lichenoid eruption: acitretin treatment allows maintained
6
7 antineoplastic effect. *Br. J. Dermatol.* 154(6), 1213-1216 (2016).
8
9
10 18. Melnik BC. Apoptosis may explain the pharmacological mode of action and
11
12 adverse effects of isotretinoin, including teratogenicity. *Acta Derm. Venereol.*
13
14 97(2), 173-181 (2017).
15
16
17 19. Dang TO, Ogunniyi A, Barbee MS, Drilon A. Pembrolizumab for the treatment of
18
19 PD-L1 positive advanced or metastatic non-small cell lung cancer. *Expert Rev.*
20
21 *Anticancer Ther.* 16(1), 13-20 (2016).
22
23
24 20. Micantonio T, Fagnoli MC, Ricevuto E, Ficarella C, Marchetti P, Peris K. Efficacy
25
26 of treatment with tetracyclines to prevent acneiform eruption secondary to
27
28 cetuximab therapy. *Arch. Dermatol.* 141(9), 1173-1174 (2005).
29
30
31 21. Navarro-Triviño FJ, de Jaime Ruiz P, Porrás Segovia A, Garrido Torres-Puchol V.
32
33 Oral isotretinoin for the treatment of aripiprazol-induced acneiform rash. *Dermatol.*
34
35 *Ther.* 31(4), e12637 (2018).
36
37
38
39
40
41
42
43
44
45
46
47
48
49
50
51
52
53
54
55
56
57
58
59
60

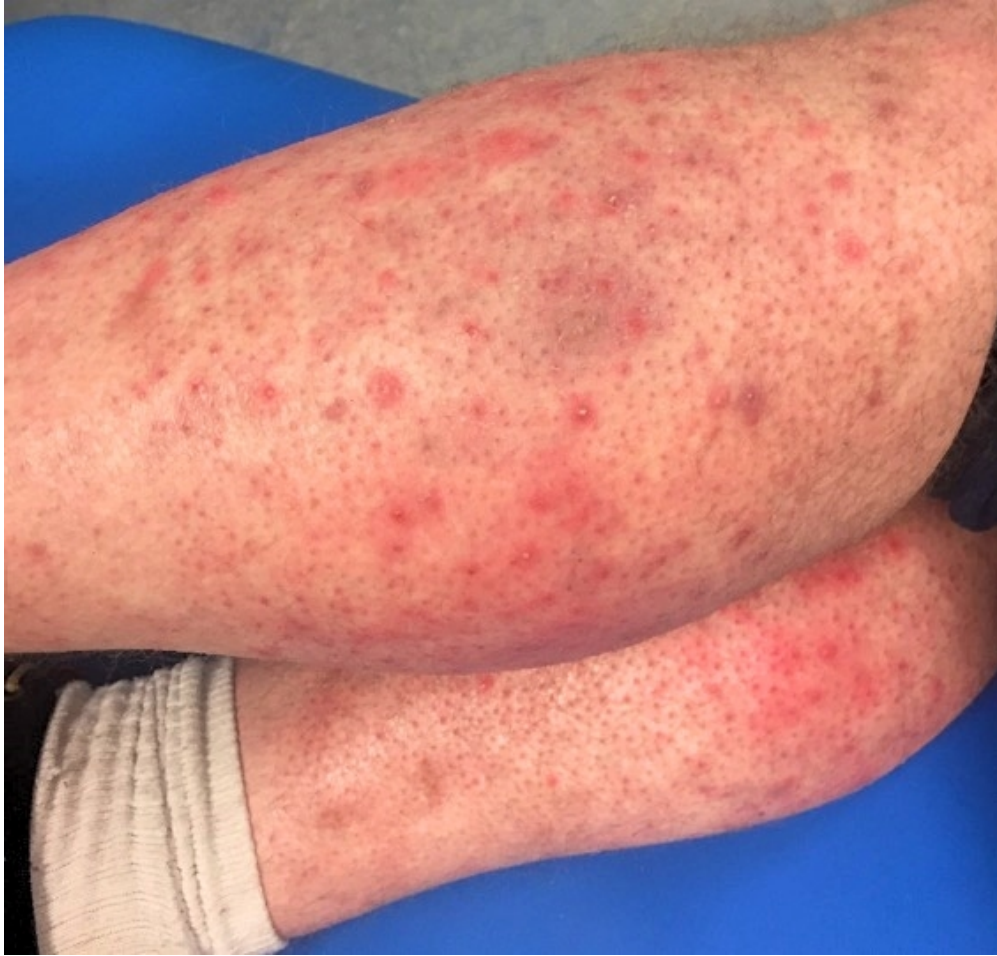

Figure 1A-B

Perifollicular papulopustular eruption of lower legs with sparing of skin where socks were providing pressure.

199x190mm (72 x 72 DPI)

1
2
3
4
5
6
7
8
9
10
11
12
13
14
15
16
17
18
19
20
21
22
23
24
25
26
27
28
29
30
31
32
33
34
35
36
37
38
39
40
41
42
43
44
45
46
47
48
49
50
51
52
53
54
55
56
57
58
59
60

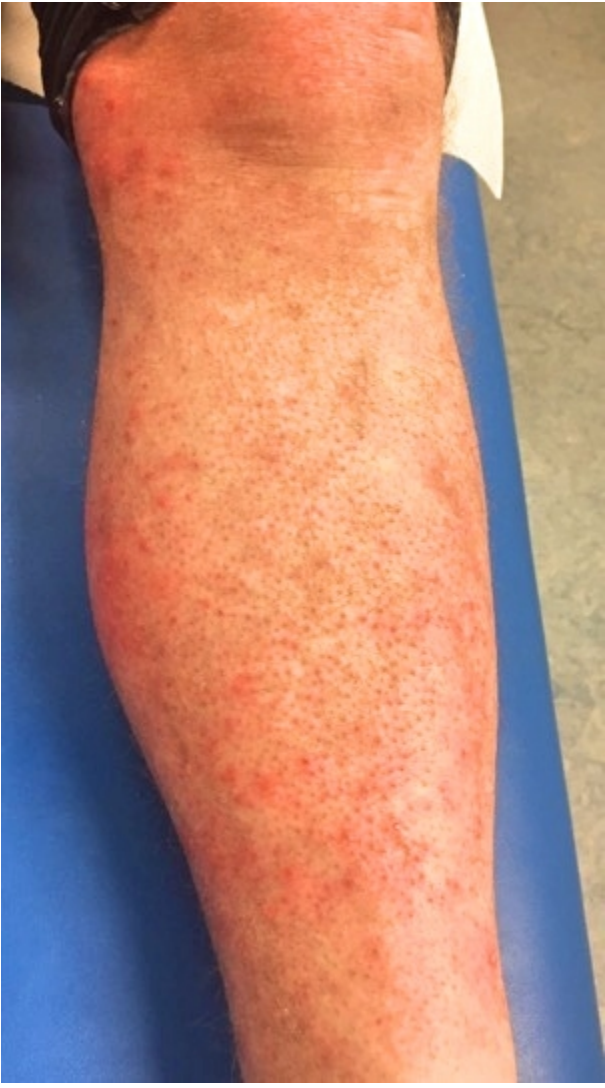

Figure 1A-B
Perifollicular papulopustular eruption of lower legs with sparing of skin where socks were providing pressure.
106x190mm (72 x 72 DPI)

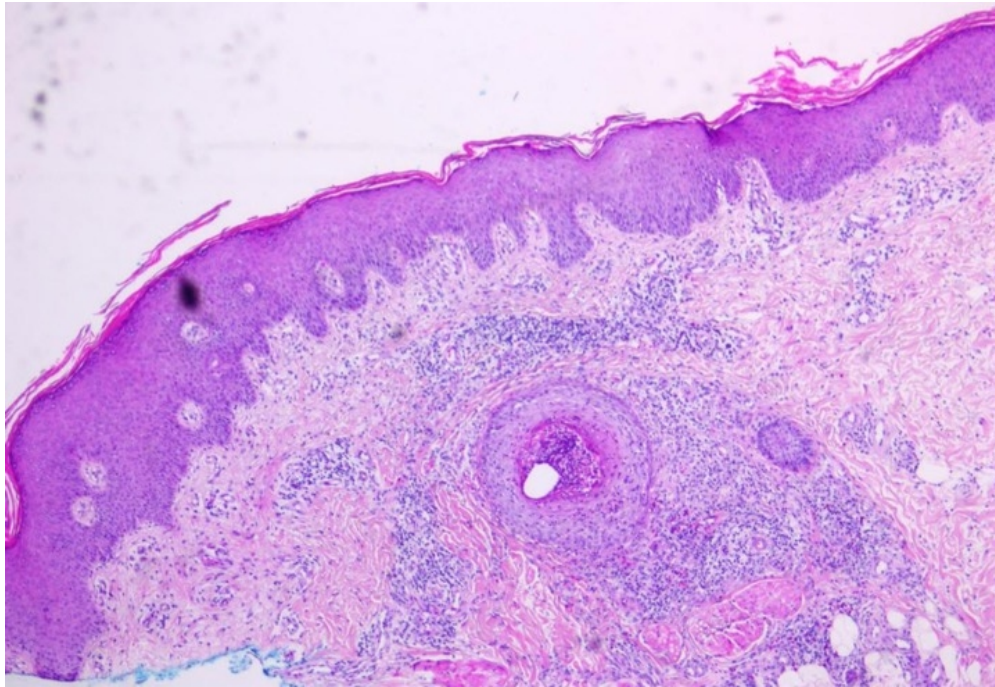


Figure 2A – Low power view of skin biopsy with hair follicle plugged with neutrophils and surrounding dermis with an acute and chronic inflammatory infiltrate.

60x41mm (300 x 300 DPI)

1
2
3
4
5
6
7
8
9
10
11
12
13
14
15
16
17
18
19
20
21
22
23
24
25
26
27
28
29
30
31
32
33
34
35
36
37
38
39
40
41
42
43
44
45
46
47
48
49
50
51
52
53
54
55
56
57
58
59
60

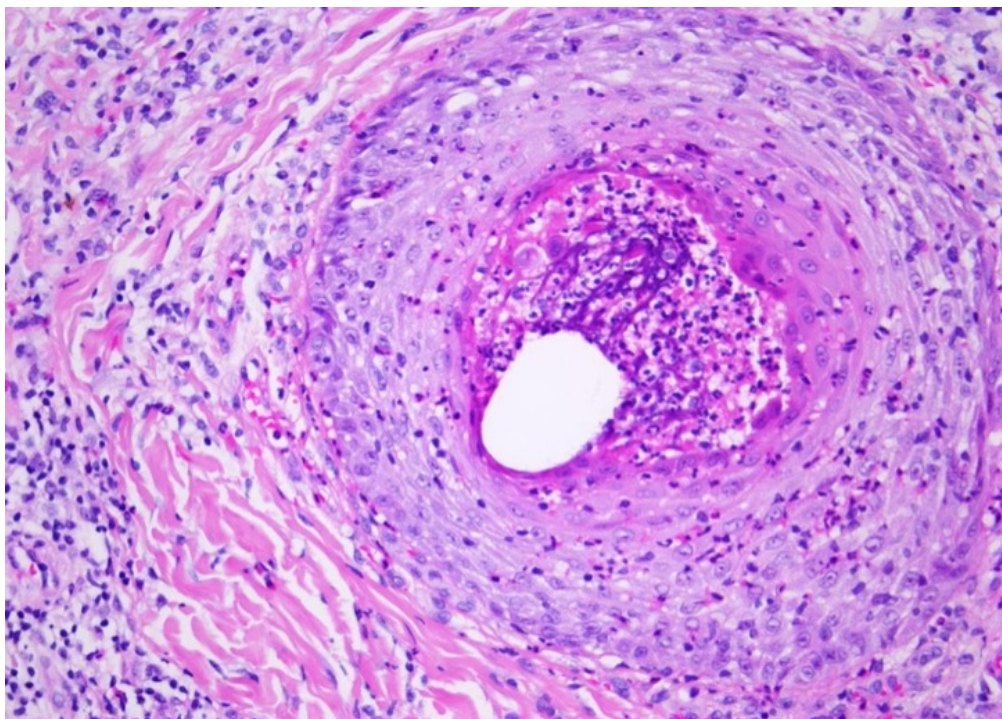


Figure 2B – High power view of hair follicle with acute folliculitis highlighting the neutrophilic infiltration of the follicular epithelium and neutrophilic infiltrate and hair shaft within the follicle.

60x43mm (300 x 300 DPI)

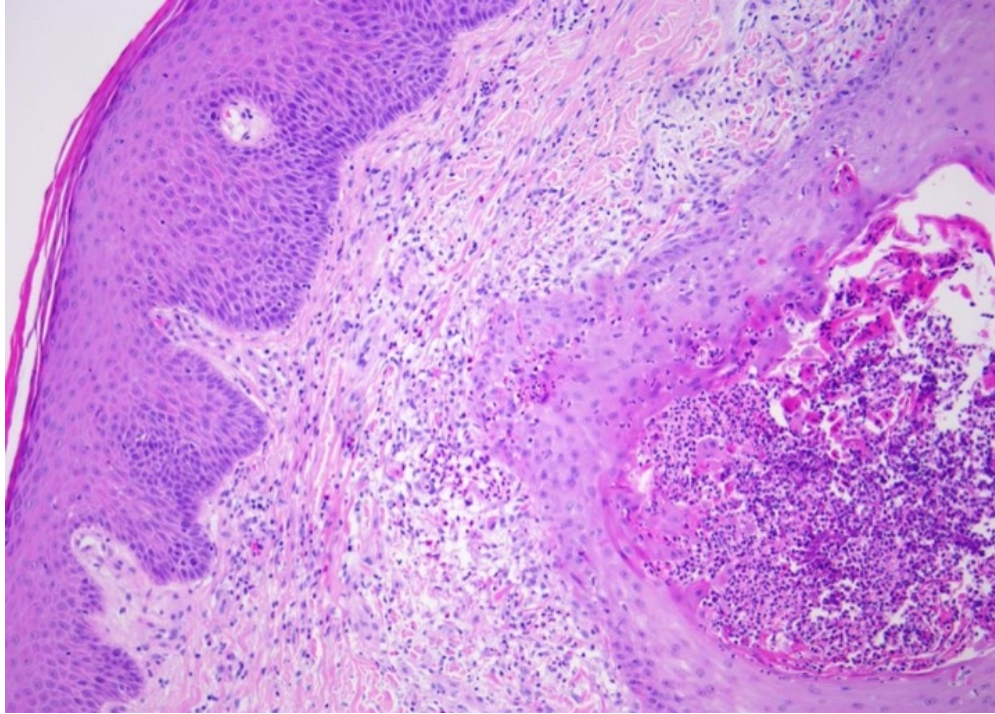


Figure 2C – High power view of hair follicle with acute folliculitis and perifolliculitis with the overlying epidermis showing some epidermal hyperplasia, hyperkeratosis and changes of lichen simplex chronicus.

60x43mm (300 x 300 DPI)

1
2
3
4
5
6
7
8
9
10
11
12
13
14
15
16
17
18
19
20
21
22
23
24
25
26
27
28
29
30
31
32
33
34
35
36
37
38
39
40
41
42
43
44
45
46
47
48
49
50
51
52
53
54
55
56
57
58
59
60

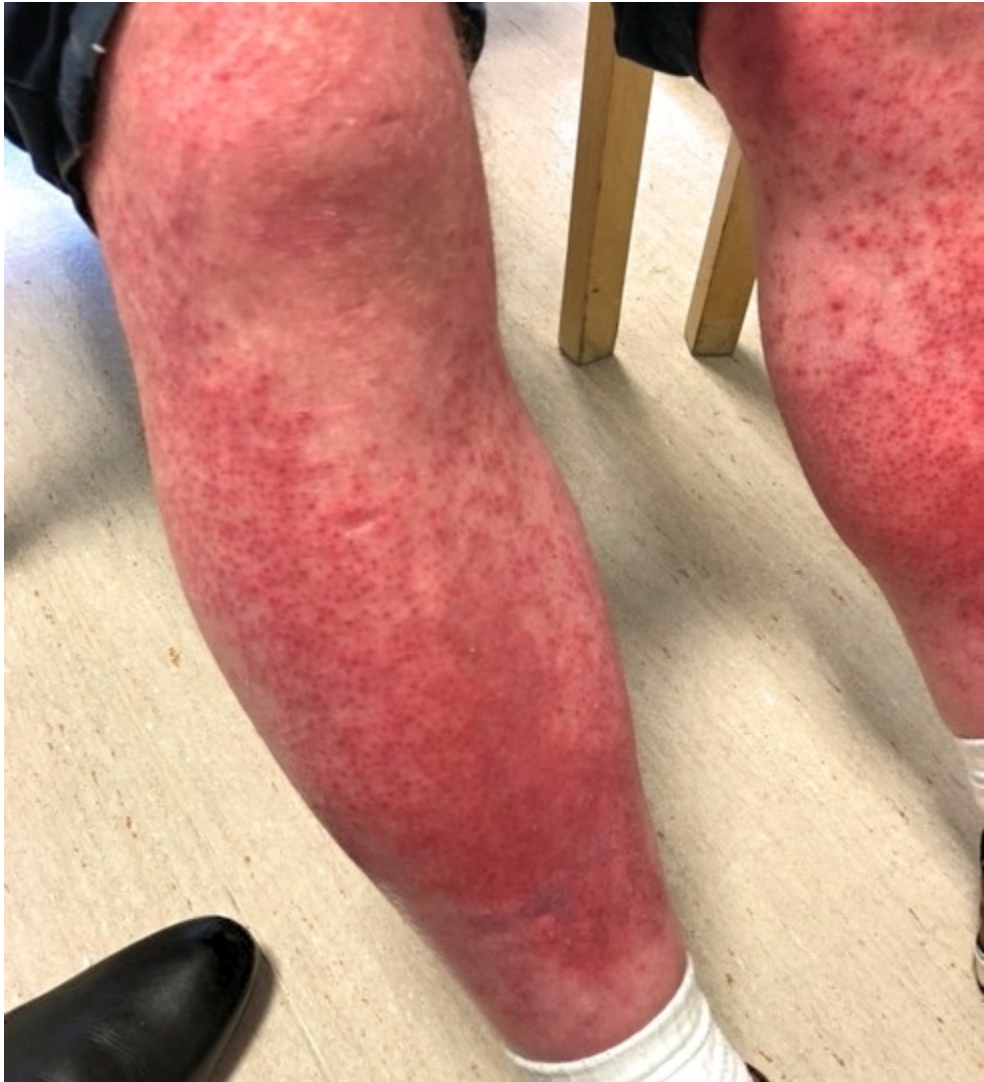

Figure 3 - Progression of folliculitis with further cycles of pembrolizumab, showing almost confluent erythema of the anterior shins.

172x190mm (72 x 72 DPI)