

Title	Bronchoscopy in the investigation of outpatients with hemoptysis at a lung cancer clinic
Authors	Arooj, Parniya;Bredin, Emily;Henry, Michael T.;Khan, Kashif A.;Plant, Barry J.;Murphy, Desmond M.;Kennedy, Marcus P.
Publication date	2018-04-12
Original Citation	Arooj, P., Bredin, E., Henry, M. T., Khan, K. A., Plant, B. J., Murphy, D. M. and Kennedy, M. P. (2018) 'Bronchoscopy in the investigation of outpatients with hemoptysis at a lung cancer clinic', Respiratory Medicine, 139, pp. 1-5. doi: 10.1016/j.rmed.2018.04.007
Type of publication	Article (peer-reviewed)
Link to publisher's version	http://www.sciencedirect.com/science/article/pii/S095461111830115X - 10.1016/j.rmed.2018.04.007
Rights	© 2018 Elsevier Ltd. All rights reserved. This manuscript version is made available under the CC-BY-NC-ND 4.0 license. - http://creativecommons.org/licenses/by-nc-nd/4.0/
Download date	2025-01-26 06:12:14
Item downloaded from	https://hdl.handle.net/10468/6180

Accepted Manuscript

Bronchoscopy in the investigation of outpatients with hemoptysis at a lung cancer clinic

Parniya Arooj, Emily Bredin, Michael T. Henry, Kashif A. Khan, Barry J. Plant, Desmond Murphy, Marcus P. Kennedy



PII: S0954-6111(18)30115-X

DOI: [10.1016/j.rmed.2018.04.007](https://doi.org/10.1016/j.rmed.2018.04.007)

Reference: YRMED 5422

To appear in: *Respiratory Medicine*

Received Date: 14 October 2017

Revised Date: 22 December 2017

Accepted Date: 11 April 2018

Please cite this article as: Arooj P, Bredin E, Henry MT, Khan KA, Plant BJ, Murphy D, Kennedy MP, Bronchoscopy in the investigation of outpatients with hemoptysis at a lung cancer clinic, *Respiratory Medicine* (2018), doi: 10.1016/j.rmed.2018.04.007.

This is a PDF file of an unedited manuscript that has been accepted for publication. As a service to our customers we are providing this early version of the manuscript. The manuscript will undergo copyediting, typesetting, and review of the resulting proof before it is published in its final form. Please note that during the production process errors may be discovered which could affect the content, and all legal disclaimers that apply to the journal pertain.

Main text word count 2841

Abstract word count 263

Title: Bronchoscopy in the Investigation of Outpatients with Hemoptysis at a Lung Cancer Clinic.

Parniya Arooj ^a, Emily Bredin ^a, Michael T Henry ^a, Kashif A Khan ^a, Barry J Plant ^a,
Desmond Murphy ^a, Marcus P Kennedy ^{a*}

^a Department of Respiratory Medicine, Cork University Hospital, Co. Cork, Ireland

* **Corresponding author:** Dr. Marcus Kennedy,

Dept. of Respiratory Medicine, Cork University Hospital, Wilton, Cork City, Ireland.

E-mail: Marcus.Kennedy@hse.ie

Phone: +353214920169

ABSTRACT:

Background: In the investigation of lung cancer, current practice in many healthcare systems would support bronchoscopy regardless of CT findings in patients with hemoptysis. We sought to identify the cause, the diagnostic yield of CT and bronchoscopy and the requirement for bronchoscopy in at risk patients with hemoptysis with a normal CT scan through our rapid access lung cancer clinic (RALC).

Methods: Initially, a chart review was performed on all patients with hemoptysis (2011-2012) and thereafter a prospective analysis was performed (2013-2016).

Results: Our analysis represents the largest study to date in outpatients with hemoptysis. In our retrospective study, 155 patients reported hemoptysis. Causes were lower respiratory tract infections (RTIs) (47%) and lung cancer (16%). Our prospective study included 182 patients. The causes of hemoptysis were RTIs (50%) and lung cancer (18%). There were no false negative CT-scans for lung cancer. 47/57 present with lung cancer underwent bronchoscopy and 43/47 were positive for lung cancer (92%). Patients with hemoptysis and lung cancer have a higher stage of malignancy with a predominance of squamous cell lung carcinoma. Smoking status, the duration of hemoptysis or description of hemoptysis were not predictive of lung cancer however lung cancer was not identified in patients age <50.

Conclusions: One sixth of patients presenting with hemoptysis to our lung cancer clinic had lung cancer. No patient identified with cancer related haemoptysis had a CT negative for lung cancer and a combination of bronchoscopy plus endobronchial ultrasound trans-bronchial needle aspiration (EBUS-TBNA) in those patients with a CT suspicious of lung cancer is 92% sensitive for lung cancer causing hemoptysis.

Key words:

Bronchoscopy

CT Thorax

EBUS-TBNA

Hemoptysis

Lung Cancer

Abbreviations:

CT: Computerized Tomography

RALC: Rapid Access Lung Cancer

EBUS-TBNA: Endobronchial Ultrasound guided Trans -bronchial Needle Aspiration

NSCLC: Non-Small Cell Lung Cancer

INTRODUCTION:

Hemoptysis is defined as the expectoration of blood that originates from the pulmonary parenchyma or airways. Most cases are benign, self-limiting events but in less than 5% cases it may be life threatening which warrants urgent investigation and treatment [1]. Common causes of hemoptysis include chronic bronchitis, bronchiectasis, pneumonia, fungal infections, tuberculosis, and malignancy. Many patients however present with pseudo-hemoptysis, that is blood originating from nasopharynx or gastrointestinal tract and it is important to rule out bleeding from these alternative sites. Guidelines regarding the referral and investigation of hemoptysis in patients at risk for lung cancer are available and in general consistent [2, 3]. The recommendations include a chest x-ray in all and progression to a computerized tomography (CT) scan and referral to a specialist in patients with an abnormal chest x-ray or normal chest x-ray who are older, or smokers or who have persistent hemoptysis. The previous UK NICE guidelines (which will be updated in 2018) recommended bronchoscopy in all patients who are undergoing CT imaging [2]. However, the recently published “National Optimal Clinical Pathway for suspected and confirmed lung cancer: Referral to treatment” report by a UK Independent Cancer Taskforce has suggested a change in strategy and includes patient pathway flow diagrams. It recommends triaging patients who have symptoms suggestive of lung cancer or a suspicious chest x-ray to CT scan. If the CT scan is negative for cancer and symptoms are self-limited, the patient does not require a bronchoscopy to rule out lung cancer. If the patient has persistent hemoptysis but a CT negative for cancer, the patient may be triaged to a non-cancer clinic with or without bronchoscopy (4). However, there is a paucity of guidance regarding the investigation of patients at risk for cancer with normal CT scan and hemoptysis.

In Ireland in 2010, the referral pathway for patients with symptoms suspicious of lung cancer being referred to our designated cancer centers in our national health system was streamlined. Patients presenting with hemoptysis to primary care are now referred to dedicated Rapid Access Lung Cancer (RALC) clinics for review and diagnostic testing. In parallel to UK NICE guidelines, it is our current practice to proceed with CT scan and bronchoscopy on all patients who have hemoptysis referred to RALC clinic excluding patients with pseudo-hemoptysis, who have poor performance status or do not consent, or where clinic radiological work-up suggests another cause of hemoptysis not requiring bronchoscopy (e.g. pulmonary embolus). It is important to state that this referral pathway accounts for approximately 50% of all patients diagnosed with lung cancer at our institution (approximately 200/year) and does not include symptomatic patients presenting to the emergency department with lung cancer. The role of bronchoscopy in the evaluation of sub massive hemoptysis with CT imaging suggesting a central airway lesion is undisputed. However, the role of bronchoscopy is controversial in patients reporting hemoptysis with normal CT. We sought to identify the cause, the diagnostic yield of CT scan and bronchoscopy and the requirement for bronchoscopy in at risk of patients with hemoptysis with a normal CT scan through our rapid access lung cancer clinic (RALC).

METHODS: We present data from both an initial retrospective followed by a subsequent prospective study. After local ethical approval from the UCC-CUH Cork research ethics board, a chart review was performed on all patients presenting with hemoptysis to the RALC at Cork University Hospital in 2011-2012 (ECM 4(d) 05/02/2013). The gold standard diagnosis for the cause of hemoptysis was a composite of confirmatory pathological or microbiological diagnosis with at least 6 months' clinic radiological follow-up. The cause of hemoptysis was broken down to the number of groups including cancer, infection, bronchiectasis, pulmonary embolus and idiopathic. A negative bronchoscopy meant the bronchoscopy did not identify the cause of hemoptysis not that there was no bleeding from the airway. If, with completion of above follow up, no cause for hemoptysis was identified, it was labeled idiopathic. However, if inadequate follow up was performed, hemoptysis was labeled "no-gold standard diagnosis". Simple statistics were used to compare groups. Based on our retrospective analysis, after ethical approval with waiver of requirement of patient consent, a prospective study was performed on all patients presenting to our Rapid Access Lung Cancer (RALC) clinic between 2013 and January 2016 (ECN 3(nn) 06/08/2013). Data was collected on a proforma at the time of presentation to RALC and thus more complete than our retrospective study. In both studies, we acquired data on the following variables: age, gender, smoking status, duration of hemoptysis, current medications, commencement and response of antibiotics, results of CT scan and bronchoscopy. In our Centre, since 2012 the majority of CT studies were done on a scanner which was at least 64-slice VCT capable. Prior to 2012 some scans were done on a 4-slice scanner but still with multi-slice CT-technology. CT images typically include all of both lung fields with upper abdominal slices. Bronchoscopy is performed under conscious sedation with flexible bronchoscopes with complete evaluation of airway anatomy. Where appropriate, endobronchial ultrasound guided trans-bronchial needle aspiration (EBUS-TBNA) and guided bronchoscopy using radial

probe ultrasound is also utilized. Our radiology, microbiology and pathology departments were not aware of our protocol and thus reporting of CT images and tissue samples were not biased by our study protocol.

Descriptive statistics were used for demographics, Categorical variables were compared using Graph pad © using un-paired t tests, Chi square and Fischer's exact tests where appropriate.

ACCEPTED MANUSCRIPT

RESULTS: In total 337 patients referred to RALC with hemoptysis were included, 155 cases in the retrospective study and 182 cases in the prospective study (**Figure 1**). Patient demographics and etiology of hemoptysis are presented in **Table 1**.

Duration and Type of hemoptysis:

Hemoptysis was classified as *single* if there is one episode, *persistent* if bleeding continues for longer than 2 weeks and *non-persistent* if it lasts less than 2 weeks. In our retrospective review the duration of haemoptysis was *single episode* n=31 (20% of patients), n=77 (50%) *non-persistent* (<2 weeks) and *persistent* (>2 weeks) n=46 (30%). *Persistent haemoptysis* was significantly more frequent in patients diagnosed with lung cancer (16/24 (66%) p=.0001). Similarly, in our prospective study, 41.8(23.5%) patients presented with a *single episode* of hemoptysis, 41.8% (N=76) with *non-persistent* (<2 weeks) hemoptysis and 35.9% (N=65) with *persistent hemoptysis* (> 2 weeks). Lung cancer patient were more likely to have *persistent hemoptysis* (23/33 (70%) s (p=0.0034)). However, it is important to note that of the 46 retrospective patients presenting with persistent hemoptysis, only 16 had cancer (35%) and of the 65 prospective patients with persistent hemoptysis, only 23 had cancer (35%).

We also analyzed the association between hemoptysis type and lung cancer in our prospective study. However, there was no association between frank blood (3/33 vs 30/149) or blood mixed with sputum and lung cancer (p=0.712). Lung cancer was also not more frequent in those reporting over 30 mls hemoptysis (4/33) as opposed to less than 30 mls (p=0.493).

Smoking Status:

The majority of patients presenting to our RALC clinic with lung cancer were current or ex-smokers 291/337. (52/291(18%)) of smokers had hemoptysis and lung cancer. However, 5/57 patients with hemoptysis and lung cancer were never smokers (8.7%). In never-smokers presenting with hemoptysis (46), 5 had lung cancer (10.86%) which was similar to our total group of patients (57 cancers /337 hemoptysis (17%). Hence, there was no difference in the incidence of lung cancer between smokers with hemoptysis (current or ex) and never smokers with hemoptysis ($p=0.294$).

CT scan in investigation of hemoptysis: (Table 2)

In both studies, all patients had chest CT performed as a part of their investigation. In our retrospective analysis 24 (16%) had lung cancer and all CTs were positive for lung cancer. Similarly, in our prospective study, 33 (18%) had lung cancer and all had chest CT positive for lung cancer. In combination, the specificity of CT imaging in patients with lung cancer for hemoptysis was 100%. Of the 57 patients with a CT scan suggestive of lung cancer, 42 had a mass or lung nodule (78%), 8 (14%) had an area of parenchymal opacity or consolidation and 7 (12%) had an endobronchial lesion.

Bronchoscopy in Investigation of hemoptysis: (Table 3 and 4)

In our retrospective study, 19/24 (79%) lung cancer patients underwent bronchoscopy for the investigation of hemoptysis. 18/19 (95%) bronchoscopies were diagnostic for lung cancer. Also 7/19 (37%) had bronchoscopy alone while 12/19 (63%) had bronchoscopy with EBUS-

TBNA to evaluate hemoptysis. Similarly, our prospective study showed 28/33 (85%) had bronchoscopy to investigate the cause of hemoptysis. 25/28 (89.2%) had bronchoscopy diagnostic for lung cancer. 21/28 (75%) had both bronchoscopies with EBUS-TBNA. In retrospective study 102/155 (66%) patients with hemoptysis underwent bronchoscopy. 71/102(70%) bronchoscopy showed no etiology of hemoptysis. In prospective study 142/182 (78%) patients had bronchoscopy to investigate the cause of hemoptysis. In 99/142(70%) bronchoscopy did not identify any cause of hemoptysis. In our study most non-malignant etiologies of hemoptysis on bronchoscopy were lower respiratory tract infections (pneumonia and bronchitis). In total 57/336 (17%) had hemoptysis secondary to lung cancer and 47/57 underwent bronchoscopy and 43/47 were positive for lung cancer (92%).

Hemoptysis and Lung cancer stages: (Table 5)

40/57 (70%) of lung cancer patients presenting to RALC had stage 3-4 lung cancer which is significantly higher than we previously reported for all patients presenting with lung cancer to our RALC (49%) ($p=.0067$) [4].

Histological subtypes of lung cancer:

In a similar fashion to our overall lung cancer cohort presenting to RALC, most tumors were non-small cell lung cancer (NSCLC) (46/57 (80.7%). However, more lung cancer patients with hemoptysis had squamous cell cancer NSCLC (27/46 (59%)) than non-squamous NSCLC in comparison to all patients presenting to our RALC with lung cancer (26%) ($p=.0005$) [5].

DISCUSSION: Our study of 337 patients which includes a large modern prospective cohort presenting to a lung cancer clinic with hemoptysis has allowed us to analyze in detail the utility of investigations performed for lung cancer and investigate patient symptom and tumor types related to lung cancer in patients with hemoptysis.

Given the fact that chest x-rays miss many patients with lung cancer and hemoptysis [6, 7], it is routine practice that all patients undergo CT imaging. Chest CT has the ability to identify abnormalities in patients with hemoptysis secondary to lung cancer and also provide accurate staging compared to chest x-rays and standard bronchoscopy [1, 8]. It has the ability of visualizing distal airways beyond the level of bronchoscope and found to be more sensitive than bronchoscopy in evaluating endobronchial lesions [9 -12]. Guidelines and studies have also suggested that in all patients with suspected lung cancer presenting with hemoptysis (excluding massive hemoptysis or an unstable patient), CT should be carried out before bronchoscopy [2, 3, 8, 13]. In those patients who have a CT negative for lung cancer, the recent UK National Optimal Pathway publication suggested that further testing including bronchoscopy is not required to rule out cancer and bronchoscopy may be performed at the discretion of the physician triaging the patient where hemoptysis is not self-limited [4]. Chest CT is more efficient and superior, noninvasive and highly useful in the clinical context of underlying causes of hemoptysis [8, 10, 14]. It was also found that CT scan localize bleeding site in 63% to 100% patients with hemoptysis [10, 15]. In a study by Revel et al [16], CT and bronchoscopy findings of 80 patients were reviewed with haemoptysis. CT was more efficient than bronchoscopy for the etiological investigation of the bleeding (77% vs 8%, respectively).

McGuinness [8], found the diagnostic yield of CT and bronchoscopy to be 61% and 43% respectively, and that CT was positive in 50% of cases with a negative bronchoscopy.

Furthermore, Miller et al [17] showed that 50% of patients with negative bronchoscopy

findings have positive CT. In a study by Hirshberg et al [11], 208 patients with hemoptysis were reviewed, 70 (34%) patients had CT chest and 47/70(67%) had positive findings on CT scans. 137(66%) out of 208 had bronchoscopy performed and 57(42%) of them had positive bronchoscopy. CT scan missed three lung cancer cases in patients with hemoptysis. This study concluded that the combined use of CT chest and bronchoscopy gave the best diagnostic yield for lung cancer. A recent Danish study [18] concluded that 16 of 269 patients with hemoptysis had lung cancer; all 16 patients had positive CT scan. No patients with normal CT scan had a positive bronchoscopy for malignancy. Similarly, in our 337 patients we identified no patient with lung cancer who had a false negative chest CT scan. In our Centre, a combination of bronchoscopy plus EBUS-TBNA is 92% sensitive for lung cancer in patients presenting to a rapid access lung cancer clinic with hemoptysis.

In **Table 6**, we have listed all publications [8, 11, 14, 16, 18-22] that we could identify reporting on CT imaging in patients with hemoptysis. Combined with our study this table includes a total of 2053 patients presenting with hemoptysis, of whom 262 (13%) had lung cancer and CT missed six cases of lung cancer (98% sensitivity). Three of these cases were from the 1980s with poor quality CT imaging [11]. Therefore, in patients with hemoptysis, the occurrence of CT occult neoplasm using modern day CT imaging is extremely rare. Of note in high risk asymptomatic smokers undergoing screening for lung cancer, a recent large publication suggested the addition of Auto Fluorescence Bronchoscopy to low-dose CT was futile in the detection of lung cancer. We are not stating that despite the quality of current CT imaging, CT occult neoplasms including carcinoma do not occur [23]. However, we postulate that these neoplasms are too small to cause hemoptysis or other symptoms and thus maybe only found in screening trials, in patients with a history of lung cancer or in patients with synchronous tumors.

Regarding younger patients with hemoptysis, in our study patients diagnosed with lung cancer were older with mean age of 61 and youngest patient with hemoptysis and lung cancer was 52 years old. In actual fact in all of these studies of 2053 patients with hemoptysis, no lung cancer was diagnosed in patients less than 50 years old. We therefore question the utility of investigations for lung cancer in younger patients with hemoptysis in future guidelines, however in this population CT imaging identifies other causes such as infection and bronchiectasis.

Similarly, to previous studies, we identified nonsmokers with hemoptysis and lung cancer. In the cohort of Hirshberg et al [11], 3 (14.2%) lung cancer patients were non-smokers. In our study 5 out of 57 cases of lung cancers were non-smokers and there was no difference in the incidence of lung cancer between smokers and non-smokers ($p=0.294$). Thus, in our opinion smoking status should not influence investigations for lung cancer in patients with hemoptysis.

In our study, patients with lung cancers had hemoptysis of long duration. McGuinness et al [8] found persistent hemoptysis in 5 out of 7 lung cancer cases, similarly Jackson et al [24] and Jacob et al [25] also demonstrated that persistent hemoptysis was significantly more frequent in patients who had lung cancer. We found that two thirds of the patients with lung cancer had persistent hemoptysis. However, given the fact that many patients without cancer presented with persistent hemoptysis and 4 patients with cancer presented with single episode hemoptysis, in our opinion the duration of hemoptysis should not influence investigations. Similarly, we did not find that patient reporting on quantity or type of hemoptysis (frank vs blood mixed with sputum) useful.

We identified differences in the histological subtype of type of lung cancer associated with hemoptysis between our study and prior studies. Small cell carcinoma found to be most common lung cancer in two prior studies at 52% and 46% respectively [11,19] Thirumaran et

al [22] noted 76% non- small cell lung cancer (NSCLC) and 7.7% small cell lung cancer. However, in our study more patients presented with hemoptysis secondary to NSCLC (80.7%) and 59% of NSCLC were squamous cell which was statistically a higher incidence of squamous cell cancer than we have previously published (26%) [5]. Regarding the stage of presentation, 40/57(70%) of lung cancer patients presenting to RALC had stage 3-4 lung cancer which is significantly higher than we previously reported for all patients presenting with lung cancer to our RALC ($p=.0067$) [5].

CONCLUSIONS:

In conclusion, in patients with hemoptysis being investigated for lung cancer, a negative CT scan for malignancy rules out lung cancer as the cause of hemoptysis with 98% sensitivity regardless of patients age, smoking status or duration of bronchoscopy. A decision to proceed to bronchoscopy may be made at the discretion of the triaging physician in hemoptysis that is not self-limited as it may help to identify other causes of hemoptysis. In patients with hemoptysis caused by lung cancer, bronchoscopy with EBUS-TBNA is accurate in diagnosing malignancy. Patients with hemoptysis and lung cancer tend to have a higher stage of malignancy with a predominance of squamous cell carcinoma. Smoking status, the duration of hemoptysis or description of hemoptysis should not influence the investigation of hemoptysis in patients referred for investigation of lung cancer.

Conflict of Interest: No conflict of interest exists for Arooj P, Bredin E, Henry MT, Khan KA, Plant BJ, Murphy D, and Kennedy MP. No support from any organization for the submitted work; no financial support and material was received from any organizations that might have an interest in the submitted work; no other relationship or activities that could appear to have influenced the submitted work.

Acknowledgement: All above mentioned authors contributed in the preparation of the article.

ACCEPTED MANUSCRIPT

REFERENCES:

- [1] J Lordan, A Gascoigne, P Corris . The pulmonary physician in critical care • Illustrative case 7: Assessment and management of massive haemoptysis. *Thorax*. 2003 Sep; 58(9): 814–819. doi: 10.1136/thorax.58.9.814
- [2] NICE Guidelines for the management of Haemoptysis, (2003)
<https://www.nuh.nhs.uk/handlers/downloads.ashx?id=61346>
- [3] Giudice MED, Young S-M, Vella ET, et al. Systematic review of guidelines for the management of suspected lung cancer in primary care. *Canadian Family Physician*. 2014;60(8): e395-e404.
- [4] National Optimal Lung Cancer Pathway and Implementation Guide August 2017.
http://content.smallerearthtech.co.uk/system/file_uploads/16086/original/National_Optimal_LUNG_Pathway_Aug_2017.pdf
- [5] Stewart P, Henry MT, Murphy DM, Henry MT, Plant BJ, Pekoz A, Guiry S, and Kennedy MP Supporting Lung Cancer Screening: Symptomatic vs Asymptomatic lung cancer at rapid access lung cancer clinic in the Republic of Ireland.Oral Presentation at Irish Thoracic Society November 2012. *Ir J Med Sci* (2012) 181: S428.
- [6] Santiago S, Tobias J, Williams AJ. A reappraisal of the causes of hemoptysis. *Arch Inte Med*. 1991;151(12):2449–2451. doi: 10.1001/archinte.1991.00400120087015.
- [7] Herth F, Ernst A, Becker HD. Long-term outcome and lung cancer incidence in patients with hemoptysis of unknown origin. *Chest* 2001;120:1592–4.
- [8] McGuinness G, Beacher JR, Harkin TJ, Garay SM, Rom WN, Naidich DP. Hemoptysis: prospective high-resolution CT/bronchoscopic correlation. *Chest*. 1994;105(4):1155–1162. doi: 10.1378/chest.105.4.1155
- [9] Naidich DP, Funt S, Ettenger NA, Arranda C. Hemoptysis: CT-bronchoscopic correlations in 58 cases. *Radiology*. 1990;177(2):357–362. doi: 10.1148/radiology.177.2.2217769.
- [10] Hsiao EI, Kirsch CM, Kagawa FT, Wehner JH, Jensen WA, Baxter RB. Utility of fiberoptic bronchoscopy before bronchial artery embolization for massive hemoptysis. *Am J Roentgenol*. 2001;177:861–867
- [11] Hirshberg B, Biran I, Glazer M, Kramer MR. Hemoptysis: etiology, evaluation, and outcome in a tertiary referral hospital. *Chest*. 1997;112(2):440–444. doi: 10.1378/chest.112.2.440.
- [12] Sirajuddin A, Mohammed TL. A 44-year-old man with hemoptysis: a review of pertinent imaging studies and radiographic interventions. *Cleve Clin J Med*. 2008;75:601–607.

- [13] Jean-Baptiste E. Clinical assessment and management of massive hemoptysis. *Crit Care Med.* 2000;28:1642–1647.
- [14] Pires FS, Teizeira N, Coelho F, Damas C. Hemoptysis – etiology evaluation and treatment in a university hospital. *Portuguese J Pulmo* 2011; 17:7-14.
- [15] Abal AT, Nair PC, Cherian J. Haemoptysis: aetiology, evaluation and outcome—a prospective study in a third-world country. *Respir Med.* 2001;95:548–552.
- [16] Revel MP, Fournier LS, Hennebicque AS, et al. Can CT replace bronchoscopy in the detection of the site and cause of bleeding in patients with large or massive hemoptysis? *Am J Roentgenol.* 2002;179:1217–1224.
- [17] Millar AB, Boothroyd AE, Edwards D, Hetzel MR. The role of computed tomography (CT) in the investigation of unexplained haemoptysis. *Respir Med.* 1992;86:39–44.
- [18] Bønløkke S, Guldbrandt LM, Rasmussen TR. Bronchoscopy in patients with haemoptysis and normal computed tomography of the chest is unlikely to result in significant findings. *Dan Med J.* 2015;62:A5123.
- [19] Tsumakidou M, Chrysofakis G, Tsiligianni I, Maltezas G, Siafakas NM, Tzanakis N. A prospective analysis of 184 hemoptysis cases – diagnostic impact of chest X-Ray, computed tomography, bronchoscopy. *Respiration.* 2006;73:808–14.
- [20] Uzun O, Atasoy Y, Findik S, Atici AG, Erkan L. A prospective evaluation of hemoptysis cases in a tertiary referral hospital. *Clin Respir J.* 2010;4:131–8.
- [21] Lee YJ, Lee SM, Park JS, Yim JJ, Yang SC, Kim YW, Han SK, Lee JH, Lee CT, Yoon HI, Yoo CG. The clinical implications of bronchoscopy in hemoptysis patients with no explainable lesions in computed tomography. *Respir Med.* 2012;106:413–9
- [22] Thirumaran M, Sundar R, Sutcliffe IM, Currie DC. Is investigation of patients with haemoptysis and normal chest radiograph justified? *Thorax.* 2009;64:854–6.
- [23] Alain Tremblay, Niloofar Taghizadeh *et al.* Low Prevalence of High Grade Lesions Detected with Autofluorescence Bronchoscopy in the Setting of Lung Cancer Screening in the Pan-Canadian Lung Cancer Screening Study. *Chest.* 2016 Apr 30 : S0012-3692(16)48727-1. Published online 2016 Apr 30.
doi: 10.1016/j.chest.2016.04.019
- [24] Jackson CV, Savage PJ, Quinn DL. Role of fiberoptic bronchoscopy in patients with hemoptysis and a normal chest roentgenogram. *Chest* 1985;87: 142-4
- [25] Bidwell JL, Pachner RW. Hemoptysis: diagnosis and management. *Am Fam Physician.* 2005;72:1253–1260

Table 1: Causes of hemoptysis and patient demographics.

	Retrospective N=155	Prospective N=182	Total N=337
Causes:			
Lung cancer	24(16%)	33(18%)	57(17%)
Infections*	73(47%)	91(50%)	164(49%)
Bronchiectasis	3(2%)	17(9%)	20(6%)
PE	2(1%)	0(0%)	2(1%)
Sarcoidosis	2(1%)	0(0%)	2(1%)
Other [§]	4(3%)	6(4%)	10(3%)
Idiopathic	25(16%)	35(19%)	60(18%)
No gold standard	22(14%)	0(0%)	22(7%)
Total	155(100%)	182(100%)	337(100%)
Age(mean±SD)	59(±12.2)	61(±10.2)	60(±11.2)
Gender			
Male	82(53%)	116(64%)	198(59%)
Female	73(47%)	66(36%)	139(41%)
Total	155(100%)	182(100%)	337(100%)

*pneumonia, acute bronchitis

[§] Vasculitis, TB

Table 2: CT Findings in 337 Patients with Hemoptysis.

Gold standard Diagnosis	CT Performed N (%)	Diagnostic CT[‡] N (%)	Normal CT N(%)
Retrospective:			
Lung cancer	24(100%)	24(100%)	0(0%)
Infection*	73(100%)	29(40%)	44(43%)
Bronchiectasis	3(100%)	3(100%)	0(0%)
PE	2(100%)	2(100%)	0(0%)
Sarcoidosis	2(100%)	2(100%)	0(0%)
Other [§]	4(100%)	3(75%)	1(14.2%)
Idiopathic	25(100%)	0(0%)	25(100%)
No gold standard	22(100%)	0(0%)	22(100%)
Total	155(100%)		
Prospective:			
Lung cancer	33(100%)	33(100%)	0(0%)
Infection*	91(100%)	46(50%)	45(33%)
Bronchiectasis	17(100%)	17(100%)	0(0%)
PE	0(0%)	0(0%)	0(0%)
Sarcoidosis	0(0%)	0(0%)	0(0%)
Other [§]	6(100%)	4(66%)	2(20%)
Idiopathic	35(100%)	0(0%)	35(100%)
No gold standard	0(0%)	0(0%)	0(0%)
Total	182(100%)		

*pneumonia, acute bronchitis

[‡] Any abnormal finding that contribute to the gold standard diagnosis

[§] Vasculitis, TB

Table 3:

Bronchoscopy findings in 337 Patients with Hemoptysis.

Gold standard Diagnosis	Number of cases N(%)	Bronchoscopy Performed N (%)	Diagnostic Bronchoscopy[‡] N (%)
Retrospective:			
Lung cancer	24(16%)	19(79%)	18(95%)
Infection*	73(47%)	54(74%)	9(17%)
Bronchiectasis	3(2%)	1(50%)	0(0%)
PE	2(1%)	0(0%)	0(0%)
Sarcoidosis	2(1%)	2(100%)	2(100%)
Other [§]	4(3%)	3(75%)	2(66%)
Idiopathic	25(16%)	13(52%)	0(0%)
No gold standard	22(14%)	10(45%)	0(0%)
Total	155(100%)	102(66%)	31(30%)
Prospective:			
Lung cancer	33(18%)	28(85%)	25(89%)
Infection*	91(50%)	71(78%)	14(20%)
Bronchiectasis	17(9%)	15(88%)	0(0%)
PE	0(0%)	0(0%)	0(0%)
Sarcoidosis	0(0%)	0(0%)	0(0%)
Other [§]	6(4%)	6(100%)	4(66%)
Idiopathic	35(19%)	22(63%)	0(0%)
No gold standard	0(0%)	0(0%)	0(0%)
Total	182(100%)	142(78%)	43(30%)

*pneumonia, acute bronchitis

[‡] Any abnormal finding that contribute to the gold standard diagnosis[§] Vasculitis, TB

Table 4: Bronchoscopy Findings in 57 patients with Lung Cancer and Hemoptysis.

Study	Lung Cancer	Bronchoscopy performed N (%)	Bronchoscopy Diagnostic *N (%)
Retrospective	24	19(79%)	18(95%)
Prospective	33	28(85%)	25(89%)
Total	57	47(82%)	43(92%)

*Any abnormal finding that contribute to the gold standard diagnosis

Table 5: Duration of Hemoptysis and Stage in 57 Patients with Lung Cancer and Hemoptysis.

Duration of hemoptysis N(%)	Stage 1a N(%)	Stage 1b N(%)	Stage 2a N(%)	Stage 2b N(%)	Stage 3a N(%)	Stage 3b N(%)	Stage 4 N(%)
Persistent 39 (68%)	3(8%)	2(5%)	3(8%)	3(8%)	9(23%)	12(30%)	12(30%)
Non-Persistent 14 (24%)	1(7%)		2(14%)	2(14%)	1(7%)	2(14%)	
Single 4 (7%)					1(25%)	1(25%)	2(50%)
Total 57(100%)*	4(7%)	2(4%)	5(9%)	5(9%)	11(19%)	15(26%)	14(25%)

*40/57(70%) of lung cancer patients presenting to RALC had stage 3-4 lung cancer which is significantly higher than we previously reported for all patients presenting with lung cancer to our RALC (p=.0067) [5].

Table 6: Sensitivity of CT Thorax for Lung Cancer in Patients with Hemoptysis: Comparison with other studies.

Journal published	Author	Study Type	Study Time period	Total Number Cases	Lung Cancer	False negative CTs for cancer
	Arooj et al	Prospective Retrospective	2013-2016 2011-2012	337	57(17%)	0
Danish Medical J	Bonlokke et al	Retrospective	2000-2010	269	16 (6%)	0
Clinical Respiratory J	Uzun et al	Prospective	2005-2009	178	51(28.6%)	0
Respir Med	Lee et al	Retrospective	2003-2009	228	1(0.43%)	1
Portuguese J Pulmonology	Pires et al	Retrospective	2004-2008	237	33(15.8%)	1
Thorax	Thirumaran et al	Retrospective	2001-2005	275	25 (11%)	1 ‡
Interventional Pulmonology	Tsoumakidou et al	Prospective	2001-2003	184	24(13%)	0
Am J Roentgen	Revel et al	Retrospective	1995-1999	80	9(11%)	0
Chest	Hirshberg et al	Retrospective	1980-1995	208	39(19%)	3
Chest	McGuinness et al	Prospective	1991-1992	57	7(12%)	0
Total				2053	262(13%)	6(98%)

*In 2053 patients presenting with hemoptysis, sensitivity of CT scans for lung cancer 256/262=98%

‡Not clear from publication whether this was a lung cancer or upper airway malignancy

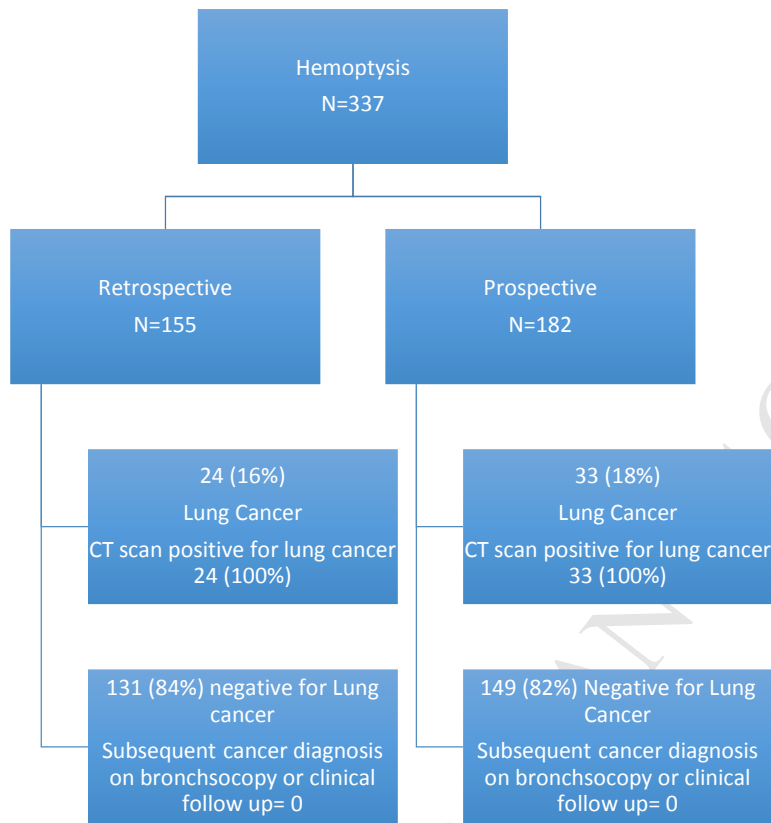
Figure 1: 337 Patients Presenting to our Rapid Access Lung Cancer Clinic with Hemoptysis.

Table 1: Causes of hemoptysis and patient demographics.

	Retrospective N=155	Prospective N=182	Total N=337
Causes:			
Lung cancer	24(16%)	33(18%)	57(17%)
Infections*	73(47%)	91(50%)	164(49%)
Bronchiectasis	3(2%)	17(9%)	20(6%)
PE	2(1%)	0(0%)	2(1%)
Sarcoidosis	2(1%)	0(0%)	2(1%)
Other [§]	4(3%)	6(4%)	10(3%)
Idiopathic	25(16%)	35(19%)	60(18%)
No gold standard	22(14%)	0(0%)	22(7%)
Total	155(100%)	182(100%)	337(100%)
Age(mean±SD)	59(±12.2)	61(±10.2)	60(±11.2)
Gender			
Male	82(53%)	116(64%)	198(59%)
Female	73(47%)	66(36%)	139(41%)
Total	155(100%)	182(100%)	337(100%)

*pneumonia, acute bronchitis

[§] Vasculitis, TB

Table 2: CT Findings in 337 Patients with Hemoptysis.

Gold standard Diagnosis	CT Performed N (%)	Diagnostic CT[‡] N (%)	Normal CT N(%)
Retrospective:			
Lung cancer	24(100%)	24(100%)	0(0%)
Infection*	73(100%)	29(40%)	44(43%)
Bronchiectasis	3(100%)	3(100%)	0(0%)
PE	2(100%)	2(100%)	0(0%)
Sarcoidosis	2(100%)	2(100%)	0(0%)
Other [§]	4(100%)	3(75%)	1(14.2%)
Idiopathic	25(100%)	0(0%)	25(100%)
No gold standard	22(100%)	0(0%)	22(100%)
Total	155(100%)		
Prospective:			
Lung cancer	33(100%)	33(100%)	0(0%)
Infection*	91(100%)	46(50%)	45(33%)
Bronchiectasis	17(100%)	17(100%)	0(0%)
PE	0(0%)	0(0%)	0(0%)
Sarcoidosis	0(0%)	0(0%)	0(0%)
Other [§]	6(100%)	4(66%)	2(20%)
Idiopathic	35(100%)	0(0%)	35(100%)
No gold standard	0(0%)	0(0%)	0(0%)
Total	182(100%)		

*pneumonia, acute bronchitis

[‡] Any abnormal finding that contribute to the gold standard diagnosis

[§] Vasculitis, TB

Table 3:

Bronchoscopy findings in 337 Patients with Hemoptysis.

Gold standard Diagnosis	Number of cases N(%)	Bronchoscopy Performed N (%)	Diagnostic Bronchoscopy[‡] N (%)
Retrospective:			
Lung cancer	24(16%)	19(79%)	18(95%)
Infection*	73(47%)	54(74%)	9(17%)
Bronchiectasis	3(2%)	1(50%)	0(0%)
PE	2(1%)	0(0%)	0(0%)
Sarcoidosis	2(1%)	2(100%)	2(100%)
Other [§]	4(3%)	3(75%)	2(66%)
Idiopathic	25(16%)	13(52%)	0(0%)
No gold standard	22(14%)	10(45%)	0(0%)
Total	155(100%)	102(66%)	31(30%)
Prospective:			
Lung cancer	33(18%)	28(85%)	25(89%)
Infection*	91(50%)	71(78%)	14(20%)
Bronchiectasis	17(9%)	15(88%)	0(0%)
PE	0(0%)	0(0%)	0(0%)
Sarcoidosis	0(0%)	0(0%)	0(0%)
Other [§]	6(4%)	6(100%)	4(66%)
Idiopathic	35(19%)	22(63%)	0(0%)
No gold standard	0(0%)	0(0%)	0(0%)
Total	182(100%)	142(78%)	43(30%)

*pneumonia, acute bronchitis

[‡] Any abnormal finding that contribute to the gold standard diagnosis[§] Vasculitis, TB

Table 4: Bronchoscopy Findings in 57 patients with Lung Cancer and Hemoptysis.

Study	Lung Cancer	Bronchoscopy performed N (%)	Bronchoscopy Diagnostic *N (%)
Retrospective	24	19(79%)	18(95%)
Prospective	33	28(85%)	25(89%)
Total	57	47(82%)	43(92%)

*Any abnormal finding that contribute to the gold standard diagnosis

Table 5: Duration of Hemoptysis and Stage in 57 Patients with Lung Cancer and Hemoptysis.

Duration of hemoptysis N(%)	Stage 1a N(%)	Stage 1b N(%)	Stage 2a N(%)	Stage 2b N(%)	Stage 3a N(%)	Stage 3b N(%)	Stage 4 N(%)
Persistent 39 (68%)	3(8%)	2(5%)	3(8%)	3(8%)	9(23%)	12(30%)	12(30%)
Non-Persistent 14 (24%)	1(7%)		2(14%)	2(14%)	1(7%)	2(14%)	
Single 4 (7%)					1(25%)	1(25%)	2(50%)
Total 57(100%)*	4(7%)	2(4%)	5(9%)	5(9%)	11(19%)	15(26%)	14(25%)

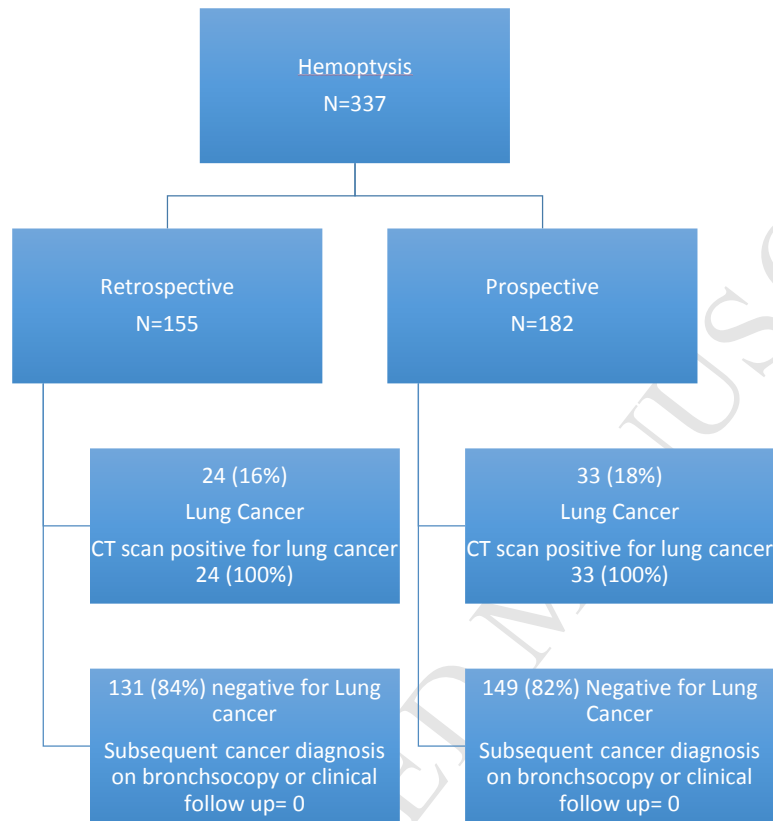
*40/57(70%) of lung cancer patients presenting to RALC had stage 3-4 lung cancer which is significantly higher than we previously reported for all patients presenting with lung cancer to our RALC (p=.0067) [5].

Table 6: Sensitivity of CT Thorax for Lung Cancer in Patients with Hemoptysis: Comparison with other studies.

Journal published	Author	Study Type	Study Time period	Total Number Cases	Lung Cancer	False negative CTs for cancer
	Arooj et al	Prospective Retrospective	2013-2016 2011-2012	337	57(17%)	0
Danish Medical J	Bonlokke et al	Retrospective	2000-2010	269	16 (6%)	0
Clinical Respiratory J	Uzun et al	Prospective	2005-2009	178	51(28.6%)	0
Respir Med	Lee et al	Retrospective	2003-2009	228	1(0.43%)	1
Portuguese J Pulmonology	Pires et al	Retrospective	2004-2008	237	33(15.8%)	1
Thorax	Thirumaran et al	Retrospective	2001-2005	275	25 (11%)	1 ‡
Interventional Pulmonology	Tsoumakidou et al	Prospective	2001-2003	184	24(13%)	0
Am J Roentgen	Revel et al	Retrospective	1995-1999	80	9(11%)	0
Chest	Hirshberg et al	Retrospective	1980-1995	208	39(19%)	3
Chest	McGuinness et al	Prospective	1991-1992	57	7(12%)	0
Total				2053	262(13%)	6(98%)

*In 2053 patients presenting with hemoptysis, sensitivity of CT scans for lung cancer 256/262=98%

‡Not clear from publication whether this was a lung cancer or upper airway malignancy

Figure 1: 337 Patients Presenting to our Rapid Access Lung Cancer Clinic with Hemoptysis.

- In patients with hemoptysis being investigated for lung cancer, a negative CT scan for malignancy rules out lung cancer as the cause of hemoptysis with 98% sensitivity regardless of patients age, smoking status or duration of bronchoscopy.
- In patients with hemoptysis caused by lung cancer, bronchoscopy with EBUS-TBNA is accurate in diagnosing malignancy.
- Patients with hemoptysis and lung cancer tend to have a higher stage of malignancy with a predominance of squamous cell carcinoma.
- Smoking status, the duration of hemoptysis or description of hemoptysis should not influence the investigation of hemoptysis in patients referred for investigation of lung cancer.
- Recently published **UK Optimal Pathways for Lung Cancer** suggests a significant change in management of patients with suspected lung cancer and similar to our findings, it suggests that in patients with symptoms suggestive of lung cancer but a negative CT for lung cancer, bronchoscopy is not required to rule out lung cancer
(http://content.smallerearthtech.co.uk/system/file_uploads/16086/original/National_Optimal_LUNG_Pathway_Aug_2017.pdf)