

Title	Diagnosis and management of femoroacetabular impingement: a review of the literature
Authors	O'Shea, Aidan;Crowley, Claire;Crowley, Diarmuid
Publication date	2018-01
Original Citation	O'Shea, A., Crowley, C. and Crowley, D. (2018) 'Diagnosis and management of femoroacetabular impingement: a review of the literature', <i>Physiotherapy Practice and Research</i> , 39(1), pp. 5-13. doi:10.3233/PPR-170101
Type of publication	Article (peer-reviewed)
Link to publisher's version	10.3233/PPR-170101
Rights	© 2018, the Authors. Published by IOS Press. All rights reserved. This document is the Accepted Manuscript version of a Published Work that appeared in final form in <i>Physiotherapy Practice and Research</i> , 39(1). The final publication is available at IOS Press through <a href="http://dx.doi.org/10.3233/PPR-170101">http://dx.doi.org/10.3233/PPR-170101</a>
Download date	2024-07-12 09:46:16
Item downloaded from	<a href="https://hdl.handle.net/10468/6432">https://hdl.handle.net/10468/6432</a>



# UCC

**University College Cork, Ireland**  
 Coláiste na hOllscoile Corcaigh

# Diagnosis and Management of Femoroacetabular Impingement: A Review of the Literature

Authors:

1. Aidan O' Shea MSc, Physiotherapy, School of Clinical Therapies, College of Medicine and Health, University College Cork, College Road, Cork, Ireland
2. Dr Claire Crowley, Department of Radiology, Cork University Hospital, Wilton, Cork, Ireland
3. Diarmuid Crowley, Physiotherapy Department, East Oxford Health Centre, Manzil Way, Oxford, OX4 1XD, UK.

Corresponding Author:

1. Aidan O' Shea, Physiotherapy, School of Clinical Therapies, College of Medicine and Health, University College Cork, College Road, Cork.

Email: [aidan.oshea@ucc.ie](mailto:aidan.oshea@ucc.ie) Tel: +353 21 4205665

Word Count: 3462

## **Abstract**

Femoroacetabular impingement (FAI) is being increasingly diagnosed as a cause of hip pain among young and middle-aged adults, and is now recognised as a likely cause of early osteoarthritis (OA) of the hip. There are two main forms, “cam” impingement and “pincer” impingement, although the vast majority of cases have a combination of both forms known as “mixed” impingement. Over time, repetitive abnormal contact between the femoral head and acetabulum can result in chondral, labral, and eventually osseous pathology. A detailed history and physical examination in conjunction with radiological imaging help in the diagnosis of FAI. Diagnosis is made difficult by the fact that many asymptomatic patients have the characteristic features of FAI on imaging. Most patients should have a trial of conservative management prior to consideration for surgery. Arthroscopic and open surgical treatments are available, with neither showing superior outcomes. In general, early outcomes of surgical treatment appear to be favourable, however these outcomes are limited to a hip joint with little or no evidence of OA. Further high quality research is required to investigate the optimal approach to diagnosing and managing this complex condition.

**Keywords:** Femoroacetabular, Impingement, Hip, Cam, Pincer

## **Introduction**

Hip pain is a common complaint among people of all ages. Increasingly, femoroacetabular impingement (FAI) is being recognised as an important underlying cause of hip pain, resulting from abnormal contact between the proximal femur and the acetabular rim [1]. This abnormal contact causes repetitive microtrauma leading to labral and cartilage damage [2], and may result in early hip osteoarthritis (OA). In fact, FAI has been proposed as a mechanism for the development of early OA in most non-dysplastic hips [3]. Ongoing improvements in imaging modalities have led to an increased recognition and understanding of this complex condition which is now understood to incorporate a range of disease patterns, deformity severities, and degenerative stages [4].

It is important to emphasise that FAI morphologic features and labral injuries are common in asymptomatic patients. In a comprehensive systematic review, Frank et al. [5] reported that the prevalence of asymptomatic hips with a deformity of the femoral head/neck was 37% (range 7% to 100% between studies). A higher prevalence was identified among athletes (54.8%) compared to the general population (23.1%). The authors also reported that the prevalence of asymptomatic hips with a deformity of the acetabulum was 67% (range 61% to 76% between studies). It is therefore essential to consider the patient history and physical examination when deciding on the need to treat patients with abnormalities of the proximal femur and/or acetabulum identified on imaging.

## **Pathophysiology**

The cause of FAI is not yet fully understood but several theories have been proposed. Certain factors have been suggested to cause FAI, including high-impact athletic activities

during growth [6], paediatric hip diseases [7, 8], and genetic factors [1, 9]. Even when no morphologic abnormalities are present, impingement can occur at extremes of hip movement. Repetitive activities that involve extremes of movement can aggravate the situation resulting in symptomatic impingement [10].

There are two main types of FAI: “cam” and “pincer”. They rarely occur in isolation, with most cases (86%) [11] of FAI involving a combination of both types referred to as “mixed” impingement. Cam and pincer impingements have distinctive intra-articular disease features [2, 3, 11]. Cam deformities are bony protrusions on the femoral head/neck resulting in impingement with hip movement. Cam deformities can result in trauma to the acetabulum during hip flexion and/or internal rotation when an abnormal femoral head/neck is forced into the acetabulum. This can place increased shearing and compressive forces on the labral-articular cartilage junction. Over time this will cause an outside-in abrasion of the anterosuperior acetabular cartilage and/or its avulsion from the labrum and subchondral bone [3, 12]. Chondral avulsion can in turn lead to tears or detachment of the largely uninvolved labrum.

Cam impingement is more common in young men, presenting at an average age of 32 years [13]. Athletes involved in high-impact sports, such as soccer, basketball and ice hockey, during adolescence have a higher prevalence of cam-type FAI as compared to non-athletes [14, 15]. This may be due to increased stresses on the femoral head while the physis is still developing. Another theory is that it may be due to new bone formation at the anterosuperior femoral head-neck junction. Paediatric hip diseases such as slipped capital femoral epiphysis [7] and Calve-Perthes [8] have been associated with an increased

incidence of FAI. Other factors which may influence impingement includes an abnormal femoral head-neck offset, pistol-grip deformity, reduced anteversion and asphericity of the femoral head [4, 10, 12].

Pincer-type impingement results from acetabular over-coverage. This over-coverage can be focal, in the case of acetabular retroversion, or global, in the cases of protrusio acetabuli and coxa profunda [3, 16]. Repetitive contact between the femoral head/neck and an abnormal acetabulum can result in degeneration of the labrum or ossification of the acetabular rim [10]. In contrast to cam impingement, acetabular chondral injury occurs in a thin circumferential band at the anterior and superolateral acetabular rim [4]. Ongoing labral and chondral damage can result in further deepening of the acetabulum and worsening of the over-coverage. As the condition worsens, the femoral head gets levered from the acetabular socket causing chondral damage in the posteroinferior part of the acetabulum as a contrecoup injury. Pincer impingement is more prevalent in athletic middle-aged females, presenting at an average age of 40 years [3, 10, 13].

## **Symptoms**

Patients presenting with FAI will commonly complain of insidious anterior or anterolateral hip pain that refers to the groin. When questioned about the location of symptoms, patients will often use the C-sign to indicate the area of pain. This indicates both anterior and posterior hip pain. In the early stages of the condition, the pain is often intermittent and exacerbated by increased activity such as athletic activities or prolonged walking. As the condition progresses, the pain becomes more constant. Other common symptoms associated with FAI include painful clicking, locking or instability which may indicate a labral

tear. Athletes will often report that they are less flexible compared to their teammates.

Patients will often report that activities such as high hip flexion or prolonged sitting aggravate their pain. They also report that putting on their socks, getting in/out of the car, running, and turning towards the affected side can exacerbate their symptoms.

### **Physical Exam**

Examination of gait pattern may reveal an antalgic gait pattern, especially as the condition progresses. Assessment of the hip will often demonstrate reduced range of motion particularly on flexion, internal rotation and adduction of the hip. Passive flexion is often limited to less than 105°, and passive internal rotation at 90° flexion is often limited to 0-15° [4].

There are several clinical diagnostic tests used to assess for FAI and labral pathology. To date, none of these tests have been shown to reliably confirm or rule out the diagnosis of FAI and/or labral pathology [17]. There are two tests commonly used to assess for FAI. The FADIR test is performed with the patient supine. The examiner passively flexes the hip to 90°, adducts the hip, and then passively internally rotates it. Reproduction of the patient's pain is considered a positive test. Passively flexing the hip to 90° and adducting the hip leads to the approximation of the femoral neck and the acetabular rim. The addition of internal rotation induces shearing forces at the labrum and creates a sharp pain when there is a chondral lesion, labral lesion or both [3]. The FADIR test has a sensitivity of 59-100% and a specificity of 4-75% [18]. Due to the high sensitivity, a negative FADIR test can quite confidently rule out FAI. However, a positive FADIR test cannot confidently diagnose FAI due to the low specificity of the test.

The other test, the posterior impingement test, is performed with the patient supine and with their leg hanging over the edge of the bed which places the hip in extension. The examiner then passively externally rotates the hip. If this test elicits the patient's pain then it is considered positive. Only one study has examined the sensitivity of this test and none have examined the specificity. The sensitivity was found to be 21% [19].

### **Radiological Assessment**

The role of imaging in FAI is to evaluate the hip for the characteristic features associated with impingement, and for evidence of chondral, labral and osseous injuries resulting from this over time.

#### Plain radiographs

X-ray is an important diagnostic tool in FAI. For the most part, two views are used: an anteroposterior (AP) view of the pelvis (not the hip) and an axial cross-table lateral view of the hip. An alternative to the latter is the Dunn/Rippstein view which can be helpful in assessing for pathomorphologies of the anterior femoral head-neck junction [20]. If the prerequisites of correct patient positioning are not fulfilled, radiographs must be interpreted with caution.

The following radiographic measurements/features help to identify cam impingement:

- Pistol-grip deformity: this is characterised by flattening of the lateral aspect of the femoral head-neck junction on an AP x-ray of the pelvis (Figure 1). It was first described by Stulberg et al in 1975 who likened the shape of the proximal femur to that of a flintlock pistol seen in old pirate movies [13].



- Alpha angle: first described by Notzli et al in 2002 [21], the angle  $\alpha$  is described on axial views of the hip as the angle between the axis of the femoral neck and a line connecting the centre of the femoral head with the point where asphericity of the head-neck contour begins (Figure 2). An angle  $> 55^\circ$  is considered indicative of cam impingement but some authors consider an angle  $> 60^\circ$  for reduced false positive diagnoses. The angle can also be measured on CT and MRI scans. A large systematic review by Wright et al in 2015 [22] concluded that an increased  $\alpha$  angle is the only FAI prognostic factor associated with the development of early OA and a labral tear.
- Anterior offset (OS): this is the difference between the radius of the anterior femoral head and that of the anterior femoral neck on a cross-table axial view (Figure 2). Hips with cam impingement have a decreased OS of  $7.2 \pm 0.7$  mm ( $11.6 \pm 0.7$  mm in normal asymptomatic hips) [23].

The following radiographic measurements/features help to identify pincer impingement:

- General acetabular over-coverage:
  - Coxa profunda: the acetabular fossa line abuts or lies medial to the ilioischial line on an AP view of the pelvis (Figure 3B). In normal hips, the floor of the acetabular fossa lies lateral to this line (Figure 3A).
  - Protrusio acetabuli: the femoral head lies medial to the ilioischial line (Figure 3C).
  - Lateral centre edge (LCE) angle: this allows the degree of over-coverage to be quantified. It is formed by a vertical line through the centre of the femoral head connected to a line to the lateral edge of the acetabulum (Figure 4). This

must be measured from an AP x-ray of the pelvis, not of the hip. An angle  $>39^\circ$  indicates acetabular over-coverage [24].

- Acetabular index (AI): this is an angle formed by a horizontal line from the medial point of the acetabular roof and a line connecting this point to the lateral edge of the acetabulum (Figure 4). An angle  $\leq 0^\circ$  indicates an increased acetabular depth [13].
- Focal acetabular over-coverage: this may affect the anterior or posterior acetabulum. A normal acetabulum is anteverted, with the posterior rim lying lateral to the anterior rim [25]. The posterior rim can be distinguished from the anterior rim by tracing upwards from the inferior edge of the acetabulum.
  - Cross-over sign: Focal over-coverage of the anterosuperior acetabulum causes the anterior rim to lie lateral to the posterior rim in the cranial part of the acetabulum and to cross the posterior rim in the distal part of the acetabulum (Figure 5). This results in a figure-8 configuration.
  - Posterior wall sign: this is an indicator of a prominent posterior wall. In a normal hip, the posterior rim passes approximately through the centre point of the femoral head. If this line lies lateral to this point however, a more prominent posterior wall is present (Figure 6).

### Computed Tomography and Magnetic Resonance Imaging

Computed tomography (CT) and magnetic resonance imaging (MRI) are useful in confirming findings made on x-ray imaging and in surgical planning. CT is helpful in assessing bony deformities. CT scanning in the position of discomfort allows cam deformities, including femoral retroversion and coxa vara, to be accurately mapped in a 3D reconstruction [12].

Femoral retroversion is where the femoral neck is orientated posteriorly as compared with the femoral condyles. Coxa vara is where the angle between the neck and the shaft of the femur measures  $<120^\circ$  (Figure 7B).

Magnetic resonance arthrography (MRA) has traditionally been the preferred investigation for labral and chondral pathology. However, 3T-MRI is becoming increasingly popular, with near equivalent diagnostic values for labral tears [26] whilst avoiding the need for a painful joint injection. Clinical correlation is important however, with some studies reporting a high incidence (up to 73%) of asymptomatic labral tears [27].

### **Non-operative Treatment**

Conservative management is first line treatment for FAI. This often includes rest, movement pattern re-training, modification of activities, muscle strengthening, physiotherapy, anti-inflammatories, and corticosteroid injections [10, 28, 29]. Discontinuation of sport and recreational activities is encouraged, however this is often unacceptable to young patients. Intra-articular steroid injections can be helpful in reducing pain and can also help to confirm the hip joint as the source of pain [30].

Wall et al. [29] concluded in a comprehensive systematic review that the literature seems to recommend non-operative management as first line treatment for FAI. They concluded that activity modification and physiotherapy may be beneficial. However most of the papers (48/53) included in this systematic review were review or discussion papers. Wall et al. concluded that one should be cautious when interpreting this literature as a substantial amount appears to have been based on the authors' opinions rather than on evidence-based

research. The review also concluded that high-quality randomised control trials need to be conducted to ascertain the true clinical effectiveness of non-operative management.

## **Surgical Treatment**

An unsuccessful trial of non-operative management is commonly agreed to be the main indication for surgical treatment of FAI [31]. The aim of surgery is to reshape the proximal femur and/or acetabular rim to prevent abnormal contact between these two structures. During this surgery, it is also important to address any associated labral or chondral damage. The goals of surgical management are to improve mobility and function, alleviate pain, halt joint degeneration and prevent hip OA [1, 28, 30]. Several surgical techniques to treat FAI have been described in the literature. These include open procedures (surgical dislocation), hip arthroscopy combined with limited open osteochondroplasty, and complete arthroscopic techniques [4]. For non-focal disease patterns, open procedures tend to be used to allow access for major osseous reconstructions of the joint. For focal disease, less invasive procedures can be employed.

### Open Surgical Procedures

Open surgical techniques involve dislocating the hip anteriorly. A trochanteric flip osteotomy gives a full 360° view of the femoral head-neck junction allowing the surgeon to identify any abnormalities which may be causing impingement. These may then be excised in order to restore the normal concave contour of the femoral head-neck junction. Care must be taken when dislocating the hip in order to minimise vascular trauma and prevent avascular necrosis of the femoral head. Care must also be taken to avoid a femoral neck fracture.

Mardones et al. [32] suggest that the risk of femoral neck fracture is significantly high if more than 30% of the anterolateral quadrant of the head-neck junction is resected.

### Periacetabular Osteotomy

Two surgical options are frequently used for the treatment of acetabular retroversion causing pincer-type FAI: resection of the excessive anterior acetabular rim and reverse periacetabular osteotomy [1]. During reverse periacetabular osteotomy, complete reorientation of the acetabulum is achieved by cutting the acetabulum away from the rest of the pelvis and repositioning it in a way that reduces both anterior and lateral over-coverage of the femoral head, helping to alleviate anterior impingement. This option is preferred for hips with a positive posterior wall sign indicating a deficient posterior acetabular wall as trimming the anterior rim could decrease the size of the acetabulum and create instability of the hip [1].

### Arthroscopy

There has been a significant increase in the number of arthroscopic procedures performed to treat FAI in recent years. This less invasive method is preferred over open surgery where possible due to reduced morbidity and quicker recovery times [31, 33]. Avoiding the need for trochanteric osteotomies and long periods of reduced weight-bearing has clear advantages, especially for high-demand patients such as athletes seeking a quick return to high-level sport [34].

Arthroscopic management involves the placement of 2-3 ports through which the central and peripheral compartments of the joint can be assessed. The central compartment

includes structures medial to the labrum and the peripheral compartment consists of structures located outside the labrum but within the hip capsule. Traction must be applied to allow access to the central compartment when repairing pincer lesions. Care must be taken to limit the traction time to less than 2 hours in order to avoid neurovascular injury. Traction is not required to access the peripheral compartment and so cam deformities can be corrected with the hip off traction.

#### Combined arthroscopic with limited open procedures

Combined arthroscopic with limited open procedures have been described in the literature but are not frequently used. Intra-articular pathology is treated arthroscopically and recontouring of the femoral head-neck junction can be achieved via limited incisions.

#### Management of the labrum

Since the acetabular labrum is thought to have an important role in weight-bearing and joint stabilization, preservation of healthy labral tissue is desired in order to enhance the overall integrity of the joint and to prevent or delay the onset of hip OA [4]. Multiple methods of labral management exist, including labral debridement and various forms of labral repair [35, 36]. In young people with significant labral deficiency and without concurrent degenerative changes, reconstruction of the labrum can help to restore labral function [36]. Aggressive resection of the labrum may have a negative impact on joint stability and cartilage consolidation [37].

#### **Outcome of Surgical Management**

There is no consensus when it comes to choosing between open and arthroscopic methods of treating FAI, and the decision is generally dependent on the surgeon's own preference [38, 39]. Recent studies have highlighted situations in which one approach might be preferable over the other. For example, cam deformities with significant posterolateral extension were found to be managed more thoroughly by open approaches [40]. Certain acetabular deformities might also be more completely treated with an open approach [41, 42]. An open approach can also help to reduce the risk of complications as an arthroscopic approach cannot safely address all pathology in these complex cases. Surgical outcomes are less favourable when other conditions co-exist such as OA and acetabular dysplasia. In advanced degenerative joint disease, total hip replacement is the treatment of choice [4].

Harris et al [43] in a comprehensive systematic review reported that statistically significant differences were observed among patients following surgical and non-surgical treatments for FAI, with greater improvement found among patients that underwent surgery. No significant differences were observed between the different surgical techniques used. Greater re-operation and complication rates were observed following surgical dislocation compared with mini-open and arthroscopic techniques. The review concluded that outcomes of operative treatment are significantly better than those of non-operative treatment. It is important to note however that the review only included one study which assessed outcomes of the latter.

Bedi et al. [44] published a systemic review on the outcomes of surgical management of FAI. Open surgical dislocation with labral debridement and osteoplasty was concluded to be successful, with a good correlation between patient satisfaction and favourable outcome

scores. The studies reviewed which focused on open surgical procedures found that 65-85% of patients will be satisfied with their outcome at a mean of 40 months after surgery. The failure rate, defined as a dissatisfied patient and/or conversion to total hip replacement, ranged from 4% to 30% and was highest among patients with pre-existing OA. The studies reviewed which focused on arthroscopic treatments collectively assessed 271 patients with a mean follow-up time of 26 months. Good outcomes were reported for 67-93% of these patients. The failure rate ranged from 1% to 33%.

Another systematic review by Ayeni et al. [35] found that labral repair was associated with greater improvement in post-operative functional scores compared with labral debridement, with five of the six studies reporting a statistically significant difference between these methods. However, given the limitations in study design of the included studies, these results should be interpreted cautiously.

## **Conclusion**

Advances in imaging techniques have led to an increased awareness and understanding of FAI. Cam and pincer impingement rarely occur in isolation, with a combination of both mechanisms seen most often. Intermittent hip pain and restricted hip motion are the most common initial findings. A detailed patient history and physical examination in conjunction with radiological assessment of the hip enables the clinician to diagnose FAI and to assess the severity. If conservative management, including activity modification, anti-inflammatories and physiotherapy fail, surgical treatment is generally favoured. Several surgical options are available, with the surgeon being guided by the location and severity of disease as well as their technical preferences. In general, early outcomes of surgical



treatment appear to be favourable, however these outcomes are limited to a hip joint with little or no evidence of OA. Given the lack of high quality studies on the management of FAI, further investigation with well-conducted clinical trials is warranted in order to fully elucidate the long-term outcomes of surgical and non-surgical treatment methods. Questions remain regarding the epidemiology, diagnosis and treatment of FAI, thus more research is needed to better comprehend this entity.

## References

- [1] Pun S, Kumar D, Lane NE. Femoroacetabular Impingement. *Arthritis Rheumatol.* 2015;67:17-27.
- [2] Khan M, Bedi A, Fu F, Karlsson J, Ayeni OR, Bhandari M. New perspectives on femoroacetabular impingement syndrome. *Nat Rev Rheumatol.* 2016;12:303-10.
- [3] Ganz R, Parvizi J, Beck M, Leunig M, Notzli H, Siebenrock KA. Femoroacetabular impingement: a cause for osteoarthritis of the hip. *Clin Orthop Relat Res.* 2003;417:112-20.
- [4] Zebala LP, Schoenecker PL, Clohisy JC. Anterior Femoroacetabular Impingement: A Diverse Disease with Evolving Treatment Options. *Iowa Orthop J.* 2007;27:71-81.
- [5] Frank JM, Harris JD, Erickson BJ, Slikker W, 3rd, Bush-Joseph CA, Salata MJ, Nho SJ. Prevalence of Femoroacetabular Impingement Imaging Findings in Asymptomatic Volunteers: A Systematic Review. *Arthroscopy.* 2015;31:1199-204.
- [6] Agricola R, Bessems JHJM, Ginai AZ, Heijboer MP, van der Heijden RA, Verhaar JAN, Weinans H, Waarsing JH. The Development of Cam-Type Deformity in Adolescent and Young Male Soccer Players. *Am J Sports Med.* 2012;40:1099-106.

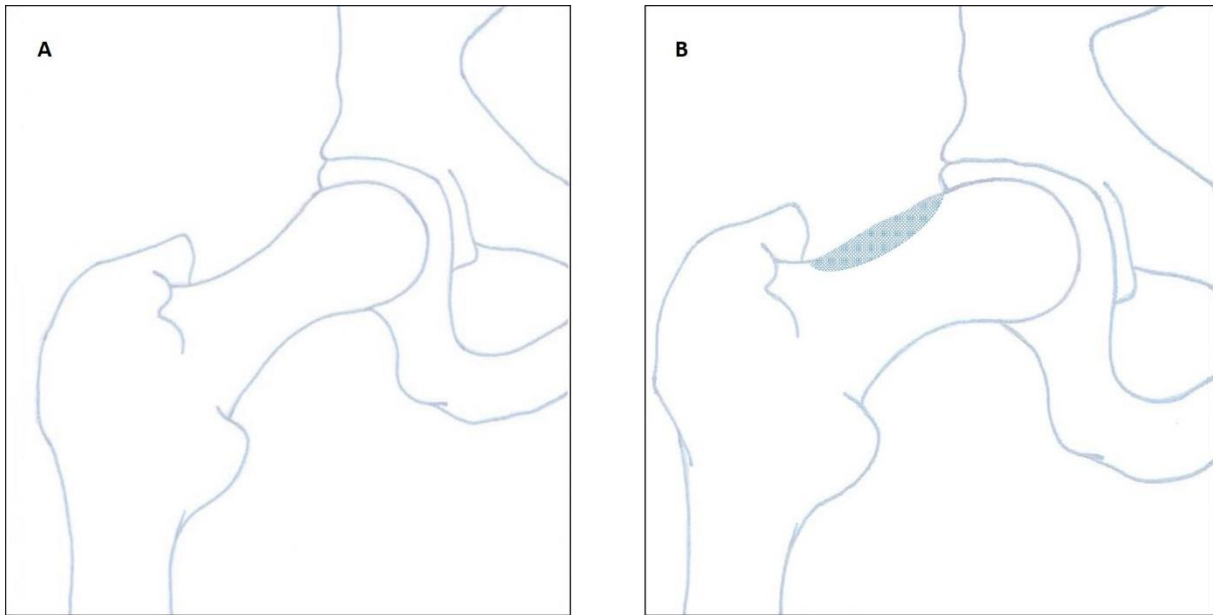
- [7] Leunig M, Casillas MM, Hamlet M, Hersche O, Nötzli H, Slongo T, Ganz R. Slipped capital femoral epiphysis: Early mechanical damage to the acetabular cartilage by a prominent femoral metaphysis. *Acta Orthopaedica Scandinavica*. 2000;71:370-5.
- [8] Accadbled F, Pailhé R, Launay F, Nectoux E, Bonin N, Gicquel P. “Femoroacetabular impingement”. *Legg-Calve-Perthes disease: From childhood to adulthood. Orthop Traumatol Surg Res*. 2014;100:647-9.
- [9] Pollard TC, Villar RN, Norton MR, Fern ED, Williams MR, Murray DW, Carr AJ. Genetic influences in the aetiology of femoroacetabular impingement: a sibling study. *J Bone Joint Surg Br*. 2010;92:209-16.
- [10] Crawford JR, Villar RN. Current concepts in the management of femoroacetabular impingement. *J Bone Joint Surg Br*. 2005;87:1459-62.
- [11] Beck M, Kalhor M, Leunig M, Ganz R. Hip morphology influences the pattern of damage to the acetabular cartilage: femoroacetabular impingement as a cause of early osteoarthritis of the hip. *J Bone Joint Surg Br*. 2005;87:1012-8.
- [12] Banerjee P, Mclean CR. Femoroacetabular impingement: a review of diagnosis and management. *Curr Rev Musculoskelet Med*. 2011;4:23-32.
- [13] Tannast M, Siebenrock KA, Anderson SE. Femoroacetabular Impingement: Radiographic Diagnosis—What the Radiologist Should Know. *AJR Am J Roentgenol*. 2007;188:1540-52.
- [14] Gerhardt MB, Romero AA, Silvers HJ, Harris DJ, Watanabe D, Mandelbaum BR. The prevalence of radiographic hip abnormalities in elite soccer players. *Am J Sports Med*. 2012;40:584-8.

- [15] Kapron AL, Anderson AE, Aoki SK, Phillips LG, Petron DJ, Toth R, Peters CL. Radiographic prevalence of femoroacetabular impingement in collegiate football players: AAOS Exhibit Selection. *J Bone Joint Surg Am.* 2011;93:e111(1-10).
- [16] Larson CM. Pincer-Type Femoroacetabular Impingement. *Oper Tech Sports Med.* 2012;20:273-80.
- [17] Tijssen M, van Cingel R, Willemsen L, de Visser E. Diagnostics of Femoroacetabular Impingement and Labral Pathology of the Hip: A Systematic Review of the Accuracy and Validity of Physical Tests. *Arthroscopy.* 2012;28:860-71.
- [18] Reiman MP, Goode AP, Hegedus EJ, Cook CE, Wright AA. Diagnostic accuracy of clinical tests of the hip: a systematic review with meta-analysis. *Br J Sports Med.* 2013;47:893-902.
- [19] Clohisy JC, Knaus ER, Hunt DM, Leshner JM, Harris-Hayes M, Prather H. Clinical Presentation of Patients with Symptomatic Anterior Hip Impingement. *Clin Orthop Relat Res.* 2009;467:638-44.
- [20] Meyer DC, Beck M, Ellis T, Ganz R, Leunig M. Comparison of six radiographic projections to assess femoral head/neck asphericity. *Clin Orthop Relat Res.* 2006;445:181-5.
- [21] Notzli HP, Wyss TF, Stoecklin CH, Schmid MR, Treiber K, Hodler J. The contour of the femoral head-neck junction as a predictor for the risk of anterior impingement. *J Bone Joint Surg Br.* 2002;84:556-60.
- [22] Wright AA, Naze GS, Kavchak AE, Paul D, Kenison B, Hegedus EJ. Radiological variables associated with progression of femoroacetabular impingement of the hip: a systematic review. *J Sci Med Sport.* 2015;18:122-7.

- [23] Eijer H, Leunig M, Mahomed M, Ganz R. Crosstable lateral radiograph for screening of anterior femoral head-neck offset in patients with femoro-acetabular impingement. *Hip Int.* 2001;11:37-41.
- [24] Tonnis D, Heinecke A. Acetabular and femoral anteversion: relationship with osteoarthritis of the hip. *J Bone Joint Surg Am.* 1999;81:1747-70.
- [25] Siebenrock KA, Kalbermatten DF, Ganz R. Effect of pelvic tilt on acetabular retroversion: a study of pelves from cadavers. *Clin Orthop Relat Res.* 2003;407:241-8.
- [26] Robinson P. Conventional 3-T MRI and 1.5-T MR arthrography of femoroacetabular impingement. *AJR Am J Roentgenol.* 2012;199:509-15.
- [27] Register B, Pennock AT, Ho CP, Strickland CD, Lawand A, Philippon MJ. Prevalence of abnormal hip findings in asymptomatic participants: a prospective, blinded study. *Am J Sports Med.* 2012;40:2720-4.
- [28] Sangal RB, Waryasz GR, Schiller JR. Femoroacetabular impingement: a review of current concepts. *R I Med J.* 2014;97:33-8.
- [29] Wall PD, Fernandez M, Griffin DR, Foster NE. Nonoperative treatment for femoroacetabular impingement: a systematic review of the literature. *PM R.* 2013;5:418-26.
- [30] Kuhlman GS, Domb BG. Hip impingement: identifying and treating a common cause of hip pain. *Am Fam Physician.* 2009;80:1429-34.
- [31] Ayeni OR, Belzile EL, Musahl V, Naudie D, Crouch S, Sprague S, Bhandari M. Results of the PeRception of femOroaCetabular impingEment by Surgeons Survey (PROCESS). *Knee Surg Sports Traumatol Arthrosc.* 2014;22:906-10.
- [32] Mardones RM, Gonzalez C, Chen Q, Zobitz M, Kaufman KR, Trousdale RT. Surgical treatment of femoroacetabular impingement: evaluation of the effect of the size of the resection. *J Bone Joint Surg Am.* 2005;87:273-9.

- [33] Yeung M, Khan M, Schreiber VM, Adamich J, Letkemann S, Simunovic N, Bhandari M, Musahl V, Philippon MJ, Safran MR, Ayeni OR. Global discrepancies in the diagnosis, surgical management, and investigation of femoroacetabular impingement. *Arthroscopy*. 2014;30:1625-33.
- [34] Philippon MJ, Stubbs AJ, Schenker ML, Maxwell RB, Ganz R, Leunig M. Arthroscopic management of femoroacetabular impingement: osteoplasty technique and literature review. *Am J Sports Med*. 2007;35:1571-80.
- [35] Ayeni OR, Adamich J, Farrokhyar F, Simunovic N, Crouch S, Philippon MJ, Bhandari M. Surgical management of labral tears during femoroacetabular impingement surgery: a systematic review. *Knee Surg Sports Traumatol Arthrosc*. 2014;22:756-62.
- [36] Ayeni OR, Alradwan H, de Sa D, Philippon MJ. The hip labrum reconstruction: indications and outcomes--a systematic review. *Knee Surg Sports Traumatol Arthrosc*. 2014;22:737-43.
- [37] Ferguson SJ, Bryant JT, Ganz R, Ito K. The influence of the acetabular labrum on hip joint cartilage consolidation: a poroelastic finite element model. *J Biomech*. 2000;33:953-60.
- [38] Ayeni OR, Wong I, Chien T, Musahl V, Kelly BT, Bhandari M. Surgical indications for arthroscopic management of femoroacetabular impingement. *Arthroscopy*. 2012;28:1170-9.
- [39] Ayeni OR, Naudie D, Crouch S, Adili A, Pindiprolu B, Chien T, Beaulé PE, Bhandari M. Surgical indications for treatment for femoroacetabular impingement with surgical hip dislocation. *Knee Surg Sports Traumatol Arthrosc*. 2013;21:1676-83.
- [40] Bedi A, Zaltz I, De La Torre K, Kelly BT. Radiographic comparison of surgical hip dislocation and hip arthroscopy for treatment of cam deformity in femoroacetabular impingement. *Am J Sports Med*. 2011;39 Suppl:20s-8s.

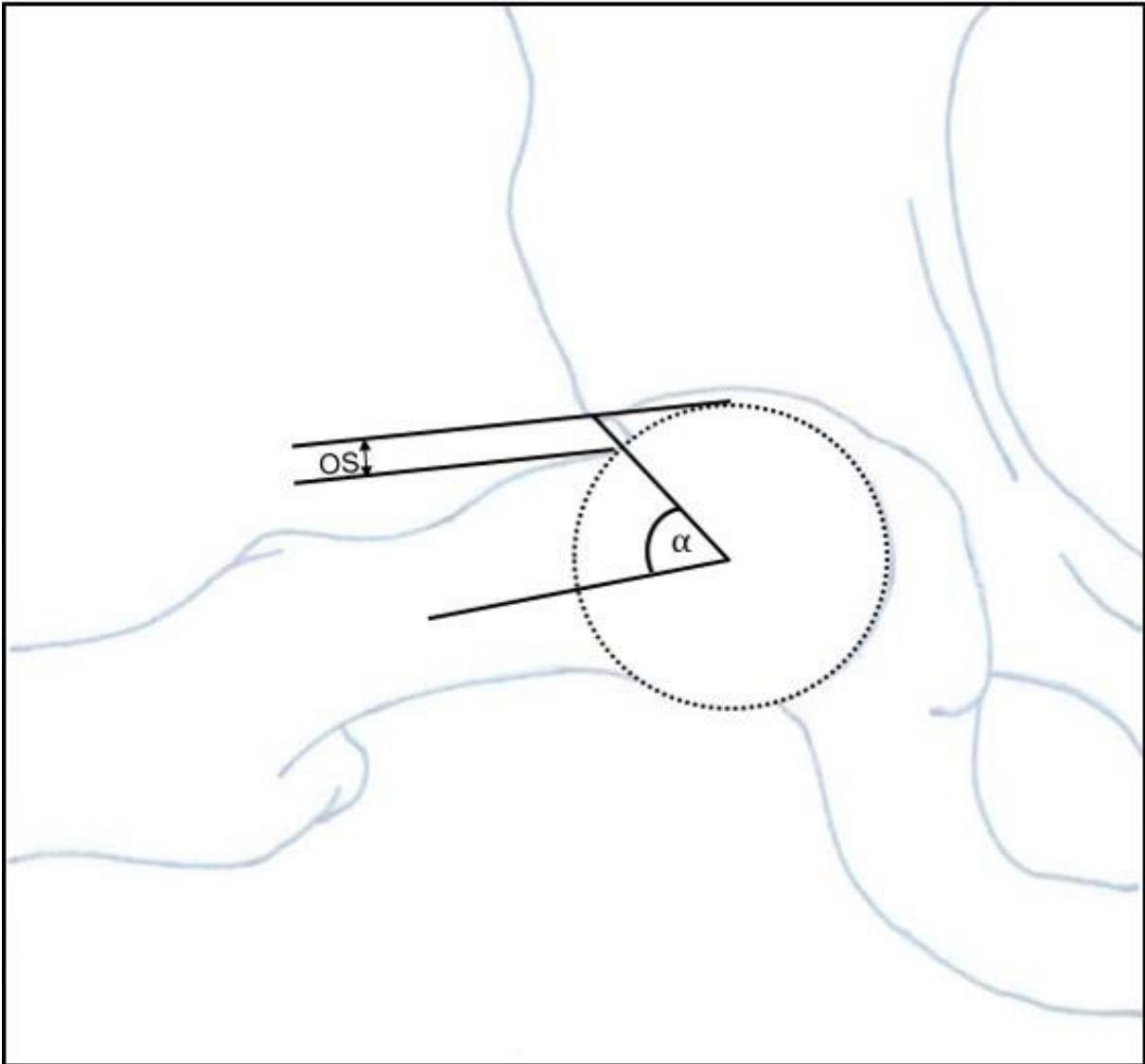
- [41] Zaltz I, Kelly BT, Larson CM, Leunig M, Bedi A. Surgical treatment of femoroacetabular impingement: what are the limits of hip arthroscopy? *Arthroscopy*. 2014;30:99-110.
- [42] Ross JR, Schoenecker PL, Clohisy JC. Surgical dislocation of the hip: evolving indications. *HSS J*. 2013;9:60-9.
- [43] Harris JD, Erickson BJ, Bush-Joseph CA, Nho SJ. Treatment of femoroacetabular impingement: a systematic review. *Curr Rev Musculoskelet Med*. 2013;6:207-18.
- [44] Bedi A, Chen N, Robertson W, Kelly BT. The management of labral tears and femoroacetabular impingement of the hip in the young, active patient. *Arthroscopy*. 2008;24:1135-45.



**Fig. 1**

A: Schematic drawing of a normal hip as seen on an AP radiograph of the pelvis.

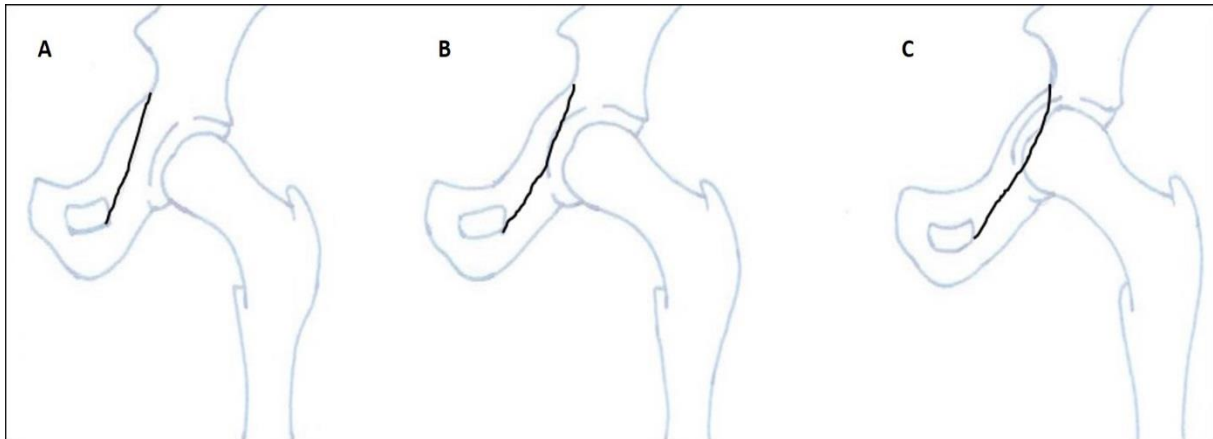
B: Schematic drawing of a hip with an anteroposterior osseous bump (pistol-grip deformity) characterised by flattening of the lateral aspect of the femoral head-neck junction on an AP view (shaded area).



**Fig. 2**

Schematic drawing of an axial cross-table view of the hip with an anterosuperior osseous bump. The angle alpha ( $\alpha$ ) lies between a line along the axis of femoral neck and a line connecting the centre of the femoral head with the point at which asphericity of the femoral head-neck contour begins. The anterior offset (OS) is the distance between a line drawn along the widest part of the femoral head and a parallel line drawn along the widest part of the femoral neck.



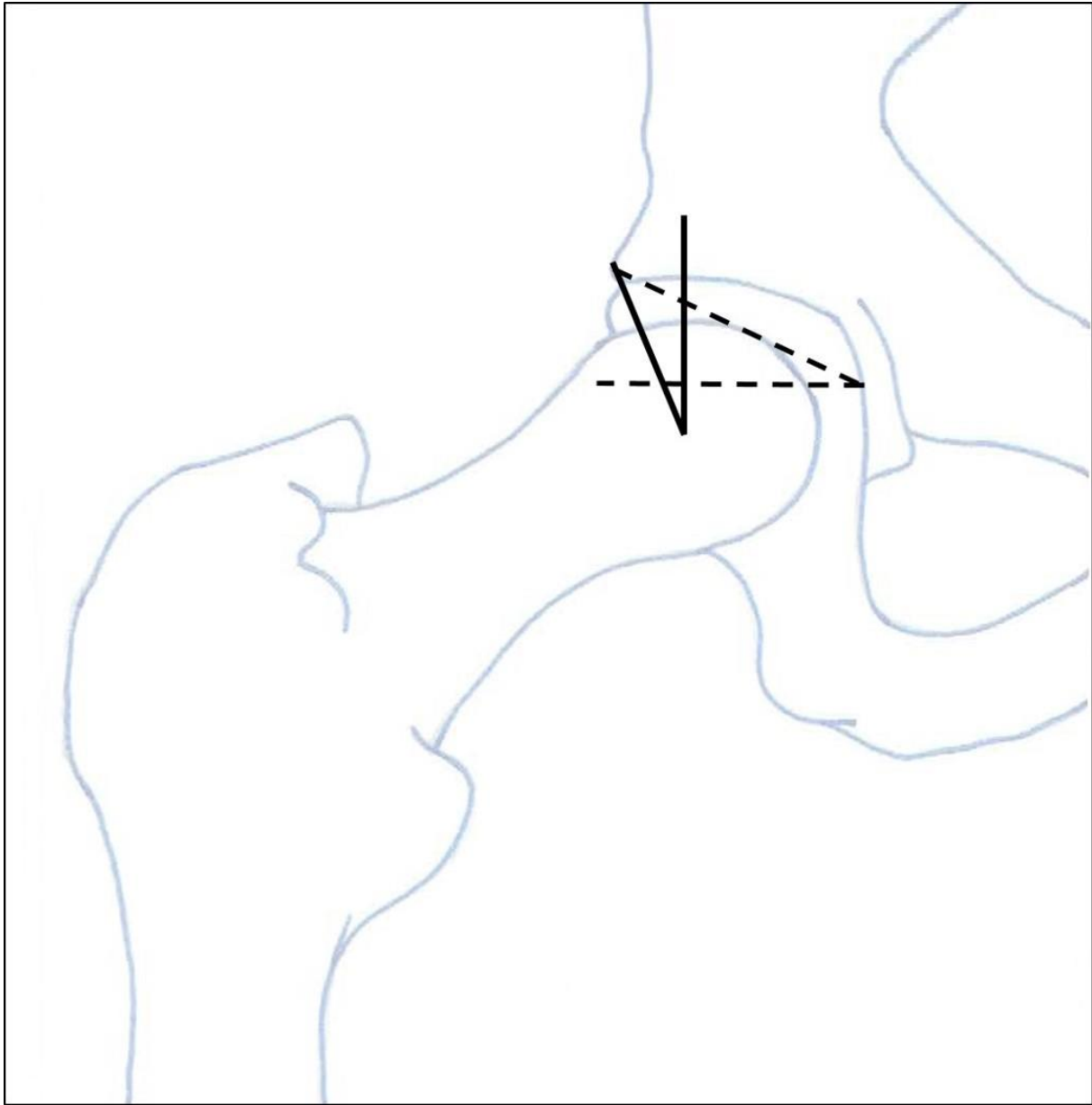


**Fig. 3**

A: Schematic drawing of a normal hip, with the femoral head and floor of the acetabular fossa located lateral to the ilioischial line (black line).

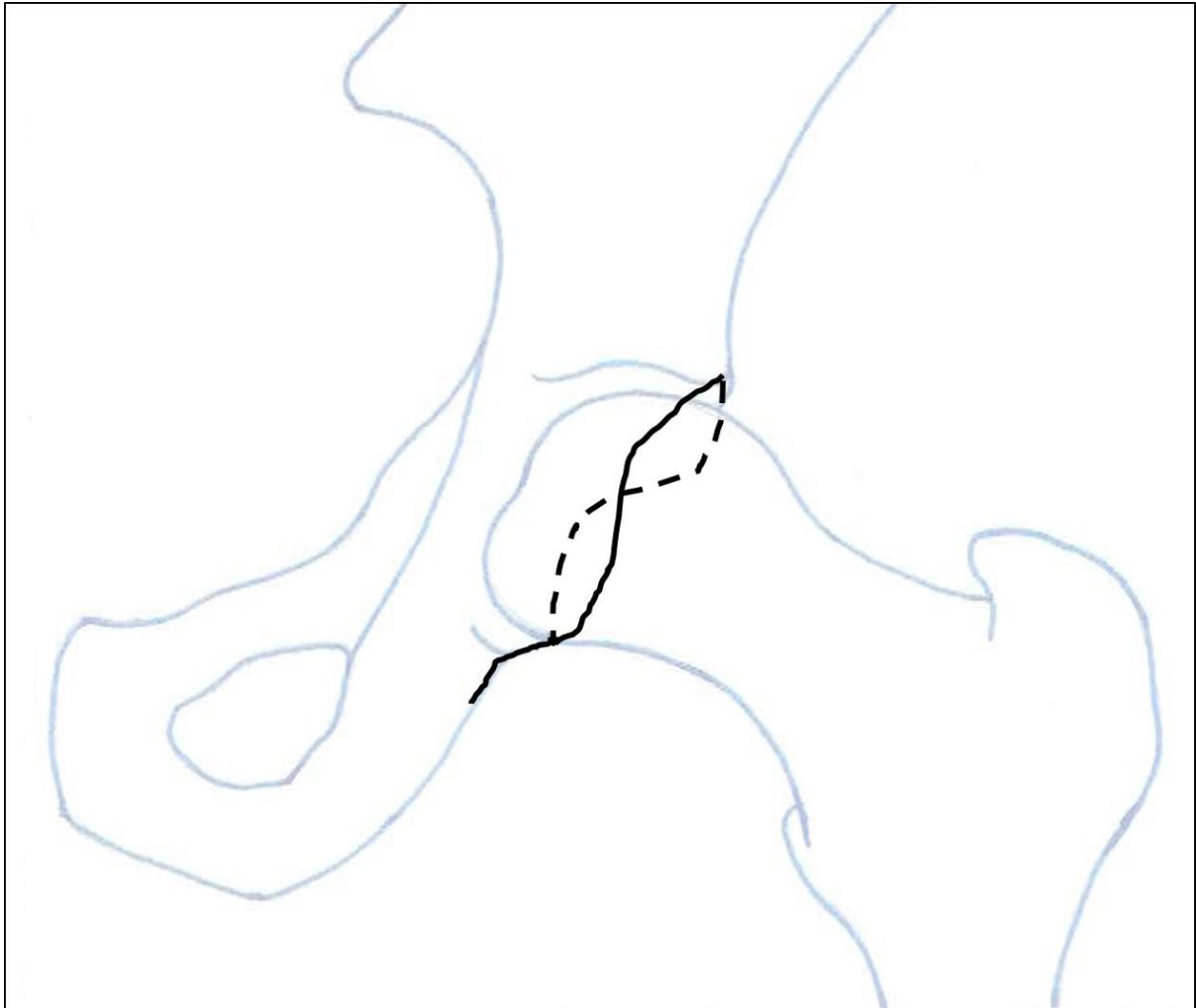B: Schematic drawing of coxa profunda, with the floor of the acetabular fossa abutting the ilioischial line.

C: Schematic drawing of protrusio acetabuli, with the femoral head overlapping the ilioischial line.



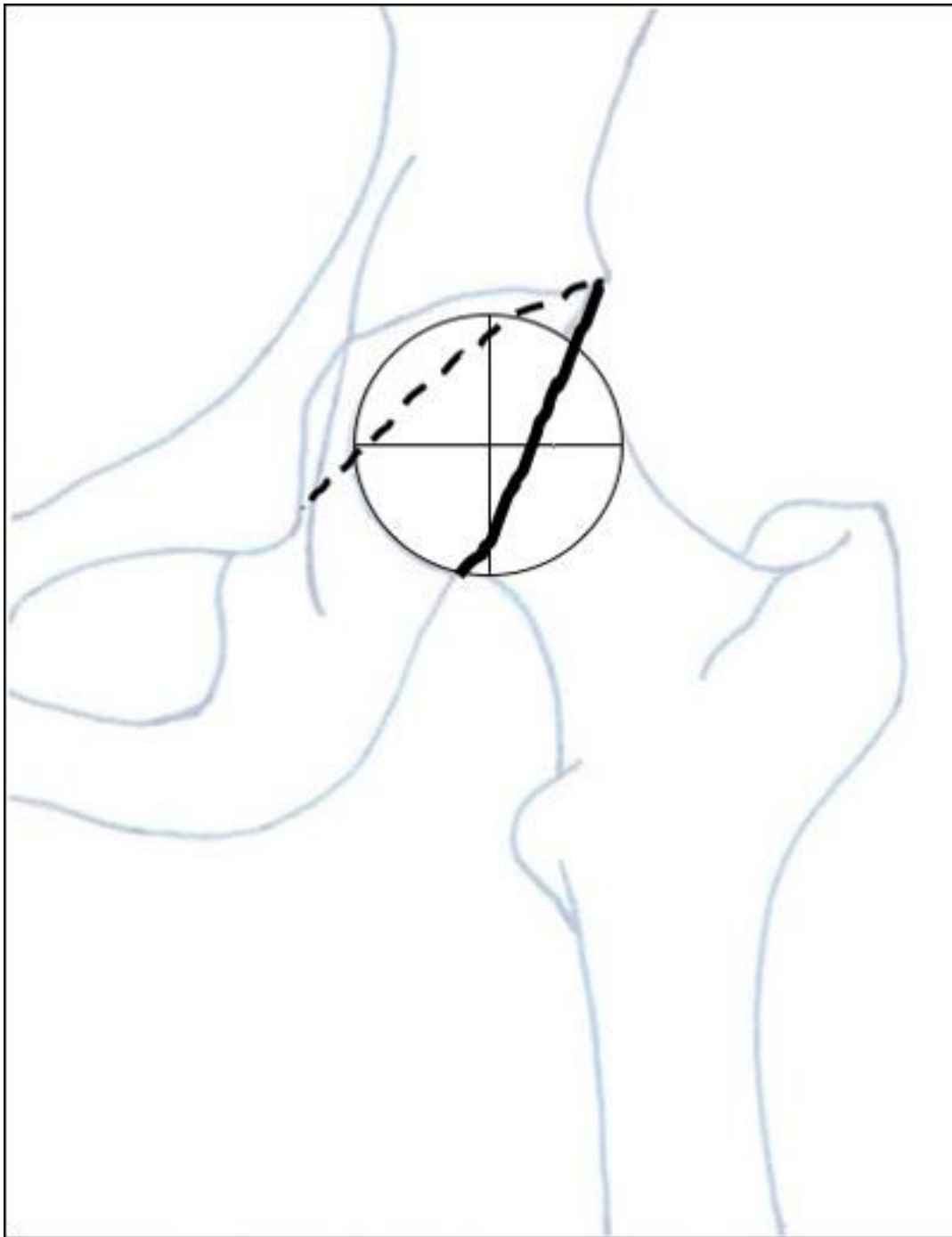
**Fig. 4**

Schematic drawing of the hip as seen on an AP radiograph of the pelvis. The lateral centre edge (LCE) angle lies between a vertical line through the centre of the femoral head and a line connecting the centre of the femoral head with the lateral edge of the acetabular roof (solid lines). The acetabular index (AI) is the angle which lies between a horizontal line and a line connecting the medial edge with the lateral edge of the acetabular roof (broken lines).

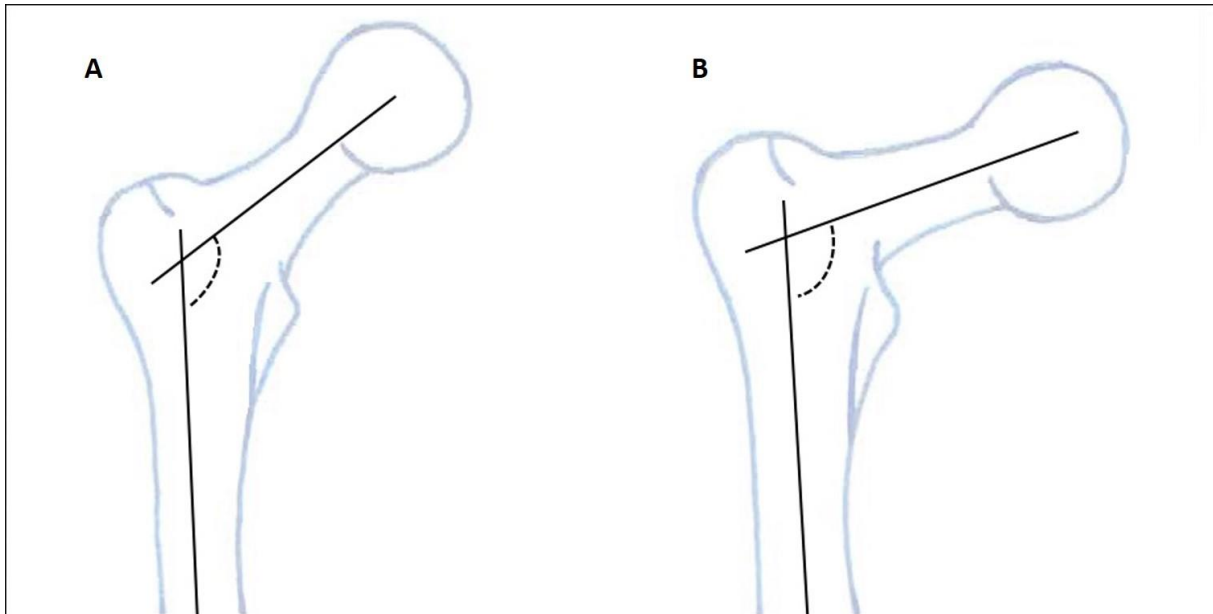


**Fig. 5**

Schematic drawing of a hip with focal over-coverage of the anterosuperior acetabulum as indicated by the anterior acetabular rim (broken line) crossing and lying lateral to the posterior rim (solid line) in the cranial part of the acetabulum ("cross-over" sign or "figure-of-8" sign).



**Fig. 6**  
Schematic drawing of a hip with focal over-coverage as indicated by a prominent posterior wall, with the posterior acetabular rim (solid line) lying lateral to the centre of the femoral head. The anterior rim is indicated by the broken line.



**Fig. 7**

Schematic drawing of a normal hip (A) and coxa vara (B). When the angle between the femoral shaft axis and the femoral neck axis measures 120-135° this is considered normal. Coxa vara is where this angle measures < 120°. Coxa valga is where it measures > 135°.