

Title	The presentation and diagnosis of the first known community transmitted case of SARS-CoV-2 in the Republic of Ireland
Authors	Faller, Eamonn;Lapthorne, S.;Barry, R.;Shamile, F.;Salleh, F.;Doyle, D.;O'Halloran, D.;Prentice, Michael B.
Publication date	2020
Original Citation	Faller, E., Lapthorne, S., Barry, R., Shamile, F., Salleh, F., Doyle, D., O'Halloran, D., Prentice, M. and Sadlier, C. (2020) 'The presentation and diagnosis of the first known community transmitted case of SARS-CoV-2 in the Republic of Ireland', Irish Medical Journal, 113(5), P78 (5pp). Available at: http://www.imj.ie/wp-content/uploads/2020/07/The-Presentation-Diagnosis-of-The-First-Known-Community-Transmitted-Case-of-SARS-CoV-2-in-the-Republic-of-Ireland.pdf (Accessed: 30 November 2020)
Type of publication	Article (peer-reviewed)
Link to publisher's version	http://www.imj.ie/wp-content/uploads/2020/07/The-Presentation-Diagnosis-of-The-First-Known-Community-Transmitted-Case-of-SARS-CoV-2-in-the-Republic-of-Ireland.pdf
Rights	© 2020, Irish Medical Journal. All rights reserved.
Download date	2024-03-01 04:47:26
Item downloaded from	https://hdl.handle.net/10468/10792

The Presentation and Diagnosis of the First Known Community-Transmitted Case of SARS-CoV-2 in the Republic of Ireland

E. Faller, S. Lapthorne, R. Barry, F. Shamile, F. Salleh, D. Doyle, D. O'Halloran, M. Prentice, C. Sadlier

Cork University Hospital, Wilton, Cork, Ireland

Abstract

Introduction

This case series describes the diagnosis of the first case of community transmission of SARS-CoV-2 in the Republic of Ireland.

Cases

Case 1: A 25 year old male presented with dyspnoea, cough and high fevers for 4 days. He was commenced on broad-spectrum antimicrobials and oxygen therapy. His respiratory function deteriorated in spite of these measures and he required mechanical ventilation. CT showed left upper lobe consolidation as well as multifocal ground-glass opacification.

Case 2: A 43 year-old male presented with headache and was found incidentally to have pneumonia. He was recently diagnosed with pituitary apoplexy secondary to an adenoma with resultant pituitary insufficiency but MRI brain was stable. His respiratory function deteriorated in spite of antibiotics and he required mechanical ventilation. CT showed likely atypical infection with resultant ARDS.

Outcome

Both underwent nasopharyngeal RT-PCR testing for SARS-CoV-2. Patient 2 was positive. Patient 1 was extubated and made a good recovery. Patient 2 was transferred to another centre for ECMO therapy. He died 27 days after transfer.

Conclusion

Given the atypical presentations in generally otherwise young and healthy individuals, the decision was made outside of national guidance to perform testing for SARS-CoV-2. This diagnosis had far-reaching implications for the SARS-CoV-2 pandemic within Ireland.

Introduction

Severe acute respiratory syndrome secondary to novel coronavirus disease (SARS-CoV-2) was declared a worldwide pandemic by the World Health Organisation (WHO) on the 11th March 2020. As of 28th April 2020 there are 19,383 confirmed cases and 924 deaths in the Republic of Ireland (Health Protection and Surveillance Centre, 2020). This case series describes two young patients with who presented to our institution days apart. Both had clinical presentations and radiological and laboratory findings consistent with severe viral pneumonitis but no epidemiological link to any known cases of SARS-CoV-2 or known areas of high prevalence as of 5th March 2020 (World Health Organisation, 2020).

Patient 1

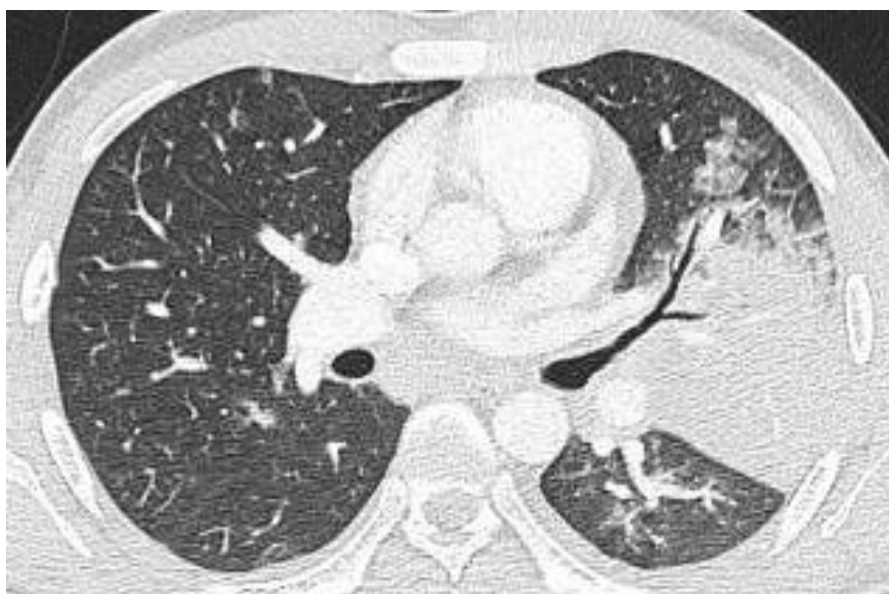
Patient 1. A 25 year old man with no background medical history was referred to Cork University Hospital by a primary care medical practitioner on 21/02/2020. He had been unwell for 4 days with a history of high fevers, vomiting, cough and progressive dyspnoea. He had no history of recent foreign travel, sick contacts or unusual exposures. He worked in a wine distributing warehouse and lived with his partner and young child. On examination he was dyspnoeic but oxygen saturation was normal on room air. He had a temperature of 38.8° celsius and was haemodynamically stable. Admission chest x-ray revealed a left midzone consolidation. Admission laboratory investigations are shown and are remarkable for a mild lymphopenia and a raised CRP. HIV serology was negative.

Haematology	Patient 1
WBC (x10 ⁹ /L)	5.7 (3.7-9.5)
Neut (x10 ⁹ /L)	4.4 (1.7-6.1)
Lymph (x10 ⁹ /L)	0.48 (1.0-3.2)
Hb (g/dL)	15.7 (13.3-16.7)
Platelet (x10 ⁹ /L)	107 (140-440)
Biochemistry	
Sodium (mmol/L)	133 (136-145)
Potassium (mmol/L)	4.1 (3.5-5.1)
Urea (mmol/L)	5.1 (2.76-8.07)
Creatinine (µmol/L)	99 (59-104)
CRP (mg/L)	124.8 (0-5)

Table 1: Admission blood laboratory values for Patient 1. Values are presented with (reference range) for males. WBC, white blood cell count; Neut, neutrophils; Lymph, lymphocytes; Hb, haemoglobin; CRP, C-reactive protein

Initial impression was one of a community-acquired pneumonia and he was commenced on IV co-amoxiclav 1.2g TDS and PO clarithromycin 500mg BD.

That afternoon he was reviewed for progressive dyspnoea. Arterial blood gas sampling revealed hypoxia with a pO₂ of 8.6 kPa on a FiO₂ of 4 litres via nasal prongs. D-dimer concentration was raised at 1.11mg/L (<0.5mg/L). He was commenced on therapeutic low molecular weight heparin. CT pulmonary angiogram was negative for pulmonary embolus but showed left upper lobe consolidation as well as multifocal ground-glass opacification involving all lobes (see below).



CTPA image of patient 1 showing left upper lobe consolidation and adjacent ground-glass opacification

His co-amoxiclav was escalated to IV piperacillin-tazobactam 4.5g QID, vancomycin with a target trough level of 15-20mg/L was added and anticoagulation discontinued. He was commenced on nasal high-flow therapy however his respiratory function continued to deteriorate. When reviewed on 23/02/2020, oxygen saturations had dropped to 81% in spite of high flow oxygen therapy. Arterial blood gas sampling on this occasion revealed a pO₂ of 5.7 kPa on a FiO₂ of 70%.

He was transferred to the intensive care unit where he was intubated and ventilated on the 24/02/2020.

Patient 2

Patient 2. A 43 year-old male who presented to Cork University Hospital with a headache on the 25/02/2020 and was noted to have an incidental cough. He had 2 recent short admissions when he had presented with headache and was diagnosed with pituitary apoplexy secondary to an adenoma with resultant pituitary insufficiency. He also had a background of a right subclavian venous thrombosis in 2013, mild asthma maintained on a salbutamol inhaler and gastro-oesophageal reflux disease. He reported no recent foreign travel or unusual exposures and worked as a farmer. On examination he was dyspnoeic and required 4 litres of oxygen via nasal prongs to maintain oxygen saturations above 94%. His chest was clear to auscultation but x-ray revealed right lower lobe opacification with associated air bronchograms. Urgent MRI brain revealed no change in his pituitary lesion. His bloods showed a lymphopenia and mild thrombocytopenia. He was commenced on IV co-amoxiclav 1.2g TDS as well as clarithromycin 500mg BD.

Haematology	Patient 2
WBC (x10 ⁹ /L)	6.9 (3.7-9.5)
Neut (x10 ⁹ /L)	5.12 (1.7-6.1)
Lymph (x10 ⁹ /L)	0.78 (1.0-3.2)
Hb (g/dL)	13.5 (13.3-16.7)
Platelet (x10 ⁹ /L)	136 (140-440)
Biochemistry	
Sodium (mmol/L)	132 (136-145)
Potassium (mmol/L)	4.3 (3.5-5.1)
Urea (mmol/L)	7.4 (2.76-8.07)
Creatinine (μmol/L)	90 (59-104)
CRP (mg/L)	135 (0-5)

Table 2: Admission blood laboratory values for Patient 2. Values are presented with (reference range) for males. WBC, white blood cell count; Neut, neutrophils; Lymph, lymphocytes; Hb, haemoglobin; CRP, C-reactive protein

Despite receiving 48 hours of intravenous antibiotics he continued spiking temperatures and became progressively dyspnoeic and hypoxic. Chest x-ray showed interval deterioration with greater air space disease in both lungs, more confluent in the mid zones and both bases. His antibiotics were changed to piperacillin-tazobactam 4.5g QID and vancomycin IV with a target trough level of 15-20mg/L and he was commenced on nasal high-flow therapy. His respiratory function deteriorated in spite of these measures and was transferred to the intensive care unit on the evening of 28/02/2020 where he required intubation and ventilation. Piperacillin-tazobactam was changed to meropenem 1g TDS.

Due to sustained severe hypoxia despite broad spectrum antimicrobials, CT pulmonary angiogram was performed. This was negative for pulmonary embolus but revealed diffuse pulmonary opacification demonstrating an anterior to posterior density gradient with diffuse ground-glass opacification in the anti-dependent portion (shown below). Overall impression was one of an atypical infection with a resultant acute respiratory distress syndrome.

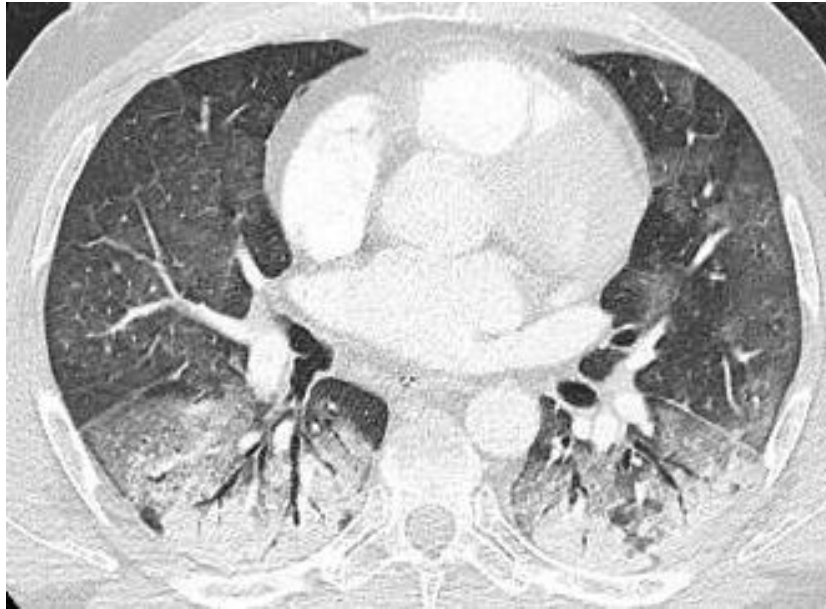

Image from CTPA of patient 2 showing diffuse pulmonary opacification demonstrating an anterior to posterior density gradient with diffuse ground-glass opacification in the anti-dependent portion

Outcomes

Despite neither patient having any epidemiological link to an area of high prevalence or to a known case, given the atypical presentations and failure to identify another cause, suspicion was raised for SARS-CoV-2.

The infectious diseases service was consulted regarding both patients. They were each requiring high level ventilatory support in intensive care. The decision was therefore taken to perform viral PCR testing for SARS-CoV-2.

The test result was positive in patient 2. This patient's presentation on 25/02/2020 antedated the first known imported case in the Republic of Ireland reported on 29/02/2020 and also represented the first community transmission of SARS-CoV-2 in the country. Epidemiological tracing is ongoing but has thus far failed to reveal the source of this transmission. Genotyping of the virus was performed in the National Virus Reference Laboratory. The strain showed very little difference to the original Hubei strain and carried none of the characteristic mutations of the Bavaria/Lombardy strains. It was noted to be similar to 3 genotyped strains from the United Kingdom but to share most genetic similarity with a strain from South Korea.

Patient 1 was found to be adenovirus positive on multiplex PCR oropharyngeal swab. It is possible that this was not the true aetiological agent of his syndrome. Testing for SARS-CoV-2 was performed on his admission oropharyngeal swab and the virus was not detected. It was repeated on the 06/03/2020 and was not detected. He improved and was extubated on the 06/03/2020 with dramatic clinical improvement thereafter. He was discharged home on the 10/03/2020.

Patient 2 deteriorated and was transferred to another centre for commencement of extra-corporeal membrane oxygenation (ECMO) therapy on the 07/03/20. He was commenced on remdesivir of which he completed a 10 day course. He died following 27 days of ECMO.

Discussion

Given the atypical presentations in generally otherwise young and healthy individuals, the decision was made to perform testing for SARS-CoV-2. The testing was done outside of national guidance applicable at that time but revealed a crucially important diagnosis.

For the patients in question this had implications for management, prognosis and family contact-tracing. From a hospital perspective it allowed immediate staff and patient contact-tracing and isolation to commence.

Thus far there have been a number of cases of onward transmission from this index case including healthcare staff and patient contacts. It had far-reaching implications on the wider epidemiology of SARS-CoV-2 in Ireland as it provided evidence of community transmission in spite of only six imported cases having been reported nationally at time of diagnosis. It resulted in immediate changes to the SARS-CoV-2 testing algorithm (Health Protection and Surveillance centre, 2020) with further community cases identified at short interval. This informed the national response to SARS-CoV-2 which has suppressed the curve and saved countless lives nationally.

This case highlights the importance of clinical judgement in deciding appropriate clinical investigation and management. In an unprecedented moment in the history of modern medicine, where evidence-based guidance and high quality clinical trials are lacking, individual clinical acumen and reasoned decision-making are more important than ever.

Declaration of Conflicts of Interest:

The authors declare no conflict of interest.

Corresponding Author:

Eamonn Faller
Infectious diseases department,
Cork University Hospital
Email: Eamonn.faller@hse.ie

References:

1. Health Protection and Surveillance centre. (2020). *COVID - 19 Risk assessment for use in a RECEIVING HOSPITAL SETTING V6.6 06/03/2020*. Retrieved from <https://www.hpsc.ie/>
2. Health Protection and Surveillance Centre. (2020). *Epidemiology of COVID-19 in Ireland 28/04/2020*. Retrieved from [https://www.hpsc.ie/a-z/respiratory/coronavirus/novelcoronavirus/casesinireland/epidemiologyofcovid-19inireland/COVID-19 Epidemiology report for NPHE 20200428_Website.pdf](https://www.hpsc.ie/a-z/respiratory/coronavirus/novelcoronavirus/casesinireland/epidemiologyofcovid-19inireland/COVID-19%20Epidemiology%20report%20for%20NPHE%2020200428_Website.pdf)
3. World Health Organisation. (2020). *Coronavirus disease 2019 (COVID-19) Situation Report – 45* (Vol. 2019). Retrieved from https://www.who.int/docs/default-source/coronaviruse/situation-reports/20200305-sitrep-45-covid-19.pdf?sfvrsn=ed2ba78b_4