

Title	PET/CT in the imaging of ovarian cancer
Authors	O'Connor, Owen J.;Prakash, Priyanka;Cronin, Carmel G.;McDermott, Shanaugh;Blake, Michael A.
Publication date	2013-01-01
Original Citation	O'Connor, O. J., Prakash, P., Cronin, C. G., McDermott, S. and Blake M. A . (2013) 'PET/CT in the imaging of ovarian Cancer', <i>Frontiers in Bioscience (Elite edition)</i> , 5, pp. 141-153. doi: 10.2741/E603
Type of publication	Article (peer-reviewed)
Link to publisher's version	https://fbscience.com/Elite/articles/10.2741/E603 - 10.2741/E603
Rights	© 2013 The Author(s). Published by Bioscience Research Institute - https://creativecommons.org/licenses/by/4.0/
Download date	2025-04-20 04:20:24
Item downloaded from	https://hdl.handle.net/10468/12209

PET/CT in the imaging of ovarian Cancer

Owen J. O'Connor¹, Priyanka Prakash², Carmel G. Cronin¹, Shaunagh McDermott¹ and Michael A. Blake¹

¹Department of Radiology, Massachusetts General Hospital and Harvard Medical School, 55 Fruit St., Boston, MA 02114, USA,

²Department of Radiology, University of Pennsylvania, 3400 Spruce St., Philadelphia, PA, USA

TABLE OF CONTENTS

1. Abstract
2. Introduction
3. FDG PET/CT technique
4. FDG PET/CT imaging appearances
 - 4.1 Distinguishing physiologic from pathologic increased ovarian FDG uptake
 - 4.2 Distinguishing benign versus malignant lesions
5. Staging of ovarian cancer
6. Detection of recurrent disease
7. Potential limitations
8. Conclusion
9. References

1. ABSTRACT

Ovarian cancer is responsible for the largest proportion of deaths among patients with gynecologic cancer. This paper discusses fluorodeoxyglucose positron emission tomography/computed tomography (FDG PET/CT) in the imaging of ovarian cancer. We discuss and demonstrate how FDG PET/CT can be used to appropriately guide clinical management decisions in patients with ovarian cancer. In particular, FDG PET/CT shows great promise for the preoperative evaluation of women with primary ovarian cancer and for subsequent postoperative assessment for recurrence.

2. INTRODUCTION

The American College of Radiology guidelines state that the goals of oncologic imaging with PET/CT are to help discriminate benign from malignant disease, quantify the extent of malignant disease, detect residual and recurrent disease and to monitor and guide therapy (1). To date, ultrasound and computed tomography (CT), have been the mainstay of imaging evaluation of patients with ovarian cancer. The optimal role for fluorodeoxyglucose positron emission tomography (FDG PET) and PET/CT for the evaluation of ovarian malignancy is being extensively studied. This paper

PET/CT in ovarian cancer

reviews the current status of FDG PET/CT in the imaging of ovarian cancer (2).

3. FDG PET/CT TECHNIQUE

At the authors' institution, we perform PET/CT examinations using a 64-slice multidetector CT (MDCT) integrated with a PET system which uses 3D lutetium oxyorthosilicate crystals. FDG is administered according to patient body mass index (BMI). Adults with a BMI less than 30 receive 15 mCi, patients with a BMI between 30 and 35 receive 20mCi and very obese patients receive 25 mCi. We require that patients fast for a minimum of 4 hours prior to imaging, and blood glucose is confirmed to be less than 200 mg/dL before FDG administration. Following FDG injection, patients are encouraged to drink water and void regularly in order to minimize pelvic irradiation and reduce normal bladder FDG activity at the time of imaging. We do not routinely catheterize the bladder prior to PET/CT in patients with ovarian cancer. An attenuation correction CT is acquired from the skull base to mid-thigh in order to facilitate FDG localization and calculate attenuation correction to be applied to PET images. This attenuation correction CT is usually acquired one hour after FDG administration. PET images are then immediately acquired from skull base to mid thigh and these images are fused with the contemporaneous diagnostic quality contrast-enhanced, neck, chest, and abdominal CT examination which is usually performed with intravenous administration of 120 mL of iodinated contrast medium (iopamidol 370 mg [Iopamiro, Bracco Diagnostics]). Our interpretation of the subsequent imaging is performed by three attending radiologists; a chest radiologist, an abdominal radiologist and a nuclear medicine radiologist. Each radiologist studies both the attenuation corrected PET images and the diagnostic CT images. The fused PET/CT is mainly used for visual interpretation and tumor volume measurements. Once the imaging has been independently studied, the three radiologists review the imaging together and arrive at a consensus prior to issuing a report of their interpretations. Final interpretation should bear in mind the following response patterns: Persistent disease is disease which has demonstrated a partial response to initial therapy and then an immediate elevation of CA125 or clinical evidence of disease. Chemotherapy resistant disease refers to recurrence detected within 6 months of completion of initial treatment. Refractory/Unresponsive/Progressive disease refers to progression during initial therapy. Recurrent ovarian cancer refers to recurrence after complete initial response to first line therapy, negative second look operation and a disease free interval of greater than 6 months.

4. FDG PET/CT IMAGING APPEARANCES

4.1. Distinguishing physiologic from pathologic increased ovarian FDG uptake.

Ovarian FDG uptake varies during differing phases of the menstrual cycle in premenopausal women which can lead to diagnostic uncertainty; however, there are a number of helpful indicators of non-significant FDG

uptake that can be sought. Physiologic ovarian FDG uptake is particularly pronounced in the early luteal phase (Figure 1). Normal physiological ovarian FDG uptake can be minimized by imaging immediately following menstruation. PET/CT is rarely deliberately timed so as to be performed at the beginning of the menstrual period in the authors' institution. Occasionally PET/CT may be so performed in selected cases where there is known malignancy in the pelvis and it is believed that physiological ovarian uptake would compromise image interpretation. Typically, physiologic ovarian FDG uptake shows spherical or discoid-shaped uptake with smooth margins. Normal ovarian uptake is usually located above the urinary bladder or around the uterus. Combined PET/CT offers advantages over PET alone in this circumstance as the features of normal ovarian uptake on PET can be correlated with the CT component of the exam in order to help distinguish physiological from pathologic uptake. Normal benign ovarian tissue can have characteristic small rim-enhancing cysts on CT, there should be no regional lymphadenopathy, and there should be concordance with the appropriate stage of the menstrual cycle (3). Ovarian FDG uptake in a post menopausal patient however should always be considered pathologic.

4.2. Distinguishing benign versus malignant lesions

Combined structural and metabolic data acquired contiguously with PET/CT has facilitated more accurate localization of suspicious areas of increased FDG uptake and improved interpretation of unexpected findings in the ovaries. While older studies which evaluated the use of PET alone for the early diagnosis of ovarian cancer have reported a disappointingly low sensitivity (58%) and specificity (76%), combined PET/CT has demonstrated a sensitivity of 87% and specificity of 100% for differentiating benign from malignant ovarian cancer (4, 5). These results were achieved when a focal increased standardized uptake value (SUV) of 3 or higher in the ovary was interpreted as indicative of ovarian malignancy, while an SUV of 2.7 or less was considered benign. Benign and malignant ovarian FDG uptake on PET were also differentiated using information provided by the contemporaneously acquired CT, such as the presence of characteristic patterns of benign FDG uptake as described in the preceding section and the absence of lymphadenopathy in patients with benign lesions. Four false-negative PET/CT studies were recorded. Three of the four primary tumors which were PET/CT negative measured 5 mm or less. While SUV values are not routinely reported in the authors' institution, the intensity of FDG uptake is correlated with the morphology of the lesion which it correlates with on CT, and an interpretation of the significance of this uptake is then made.

Further research has demonstrated that PET/CT has a sensitivity of 80% and a specificity of 97% for the diagnosis of synchronous malignancy in the contralateral ovary in patients with primary ovarian cancer (6). Even though PET/CT is relatively specific for the assessment of ovarian lesions that are greater than 5 mm in size, its sensitivity is low compared with ultrasonography for the assessment of small (<5mm) lesions although all current

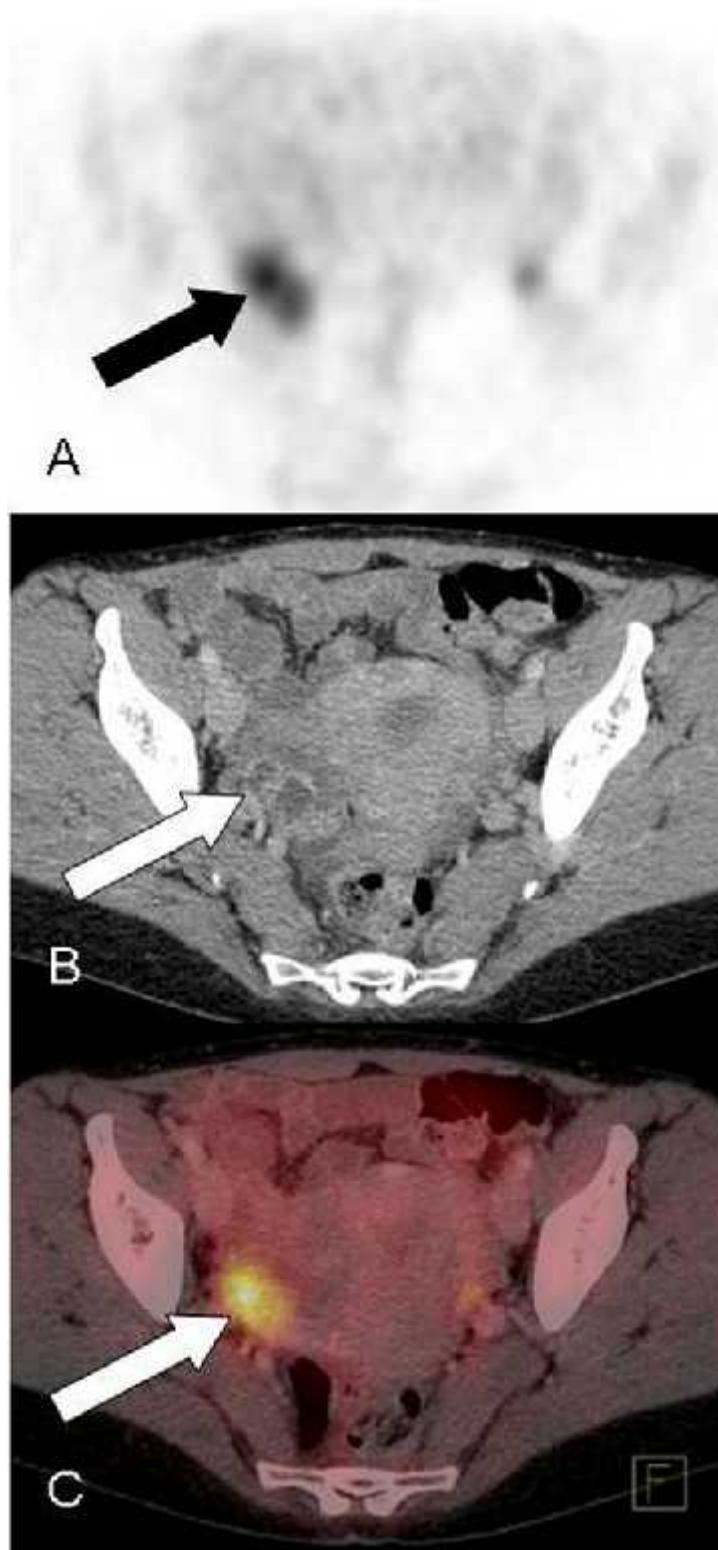


Figure 1. Transverse PET, intravenous contrast enhanced CT, and fused PET/CT images in a premenopausal woman with physiologic uptake in a normal ovary. A, There is a spherical area of increased FDG uptake (arrow) in the right adnexal region on PET. B, Morphologically normal right ovary (arrow) containing follicular and corpus luteum cysts as seen on CT. C, Fused images confirms increased FDG uptake is within the ovary (arrow)

Table 1. International federation of obstetric gynecology (FIGO) and TNM staging systems for ovarian cancer

Tumor Type, TNM Category	FIGO Stage	Description
Primary tumor (T)		
TX		Primary tumor cannot be assessed
T0		No evidence of primary tumor
T1	I	Tumor limited to ovaries (one or both)
T1a	IA	Tumor limited to one ovary; capsule intact, no tumor on ovarian surface; no malignant cells in ascites or peritoneal washing
T1b	IB	Tumor limited to both ovaries
T1c	IC	Tumor limited to one or both ovaries with any of the following: capsule ruptured, tumor on ovarian surface, malignant cells in ascites or peritoneal washings
T2	II	Tumor involves one or both ovaries with pelvic extension or implants
T2a	IIA	Extension or implants on uterus or tube(s); no malignant cells in ascites or peritoneal washings
T2b	IIB	Extension to or implants on other pelvic tissues; no malignant cells in ascites or peritoneal washings
T2c	IIC	Pelvic extension or implants (T2a or T2b) with malignant cells in ascites or peritoneal washings
T3	III	Tumor involves one or both ovaries with microscopically confirmed peritoneal metastasis outside the pelvis
T3a	IIIA	Microscopic peritoneal metastasis beyond pelvis (no macroscopic tumor)
T3b	IIIB	
T3c	IIIC	Peritoneal metastasis beyond pelvis > 2 cm in greatest dimension or regional lymph node metastasis
Regional lymph nodes (N)		
NX		Regional lymph nodes cannot be assessed
N0		No regional lymph node metastasis
N1	IIIC	Regional lymph node metastasis
Distant metastasis (M)		
MX		Distant metastasis cannot be assessed
M0		No distant metastasis
M1	IV	Distant metastasis (excludes peritoneal metastasis)

Table 2. Summary of TNM and international federation of obstetrics gynecology staging of ovarian cancer

Stage Grouping	Primary Tumor Stage (T)	Regional Lymph Node Stage (N)	Distant Metastasis Stage (M)
I	T1	N0	M0
IA	T1a	N0	M0
IB	T1b	N0	M0
IC	T1c	N0	M0
II	T2	N0	M0
IIA	T2a	N0	M0
IIB	T2b	N0	M0
IIC	T2c	N0	M0
III	T3	N0	M0
IIIA	T3a	N0	M0
IIIB	T3b	N0	M0
IIIC	T3c	N0	M0
	Any T	N1	M0
IV	Any T	Any N	M1

imaging modalities are limited in accurately characterizing such small lesions.. In addition, the majority of patients which are screened for ovarian disease with ultrasound do not have malignancy and for the vast majority of these patients PET/CT would be wasteful of a valuable resource and impart unnecessary radiation exposure. Therefore, it is the authors' opinion that PET/CT should not replace sonography for the screening of ovarian cancer. Given its high specificity, FDG PET/CT is more appropriately used to assess for occult metastases for staging purposes or prior to surgical intervention.

5. STAGING OF OVARIAN CANCER

Ovarian cancer is surgically staged in accordance with the International Federation of Gynecology and Obstetrics TNM staging system (7) (Tables 1 and 2). Stage I cancer is limited to the ovaries, stage II to the pelvis, stage III beyond the pelvis and stage IV involves distant sites such as the liver parenchyma. Nodal spread can occur through the gonadal lymphatics to the retroperitoneum, via the broad ligaments to the obturator, internal and external

iliac nodes, and via the round ligaments to the inguinal nodes. Peritoneal spread follows the route of normal peritoneal fluid circulation and occurs in areas of relative stasis such as at the rectosigmoid junction, paracolic gutters and beneath the right hemidiaphragm (8). Traditionally, CT has been the preferred imaging modality for primary preoperative staging of ovarian cancer. Combined PET/CT has been shown by recent studies to be beneficial in evaluating distant metastases and equivocal lesions (5, 6). For example, in one study, CT alone incorrectly understaged four of six patients with stage four ovarian cancer because distant metastases were not identified (5). PET/CT was highly sensitive for peritoneal deposits which exceeded 1 cm in diameter and lymph nodes exceeding 7 mm. PET/CT has been reported to increase pretreatment staging accuracy compared with CT alone from 53–55% to 69–75% (Figure 2 and 3) (5). The sensitivity of PET/CT is limited for the detection of varieties of ovarian cancer with poor FDG uptake such as mucinous tumors and for the assessment of lymph nodes less than 7mm in size and peritoneal deposits less than 1cm (9). It has been suggested that one of the most helpful aspects of information that

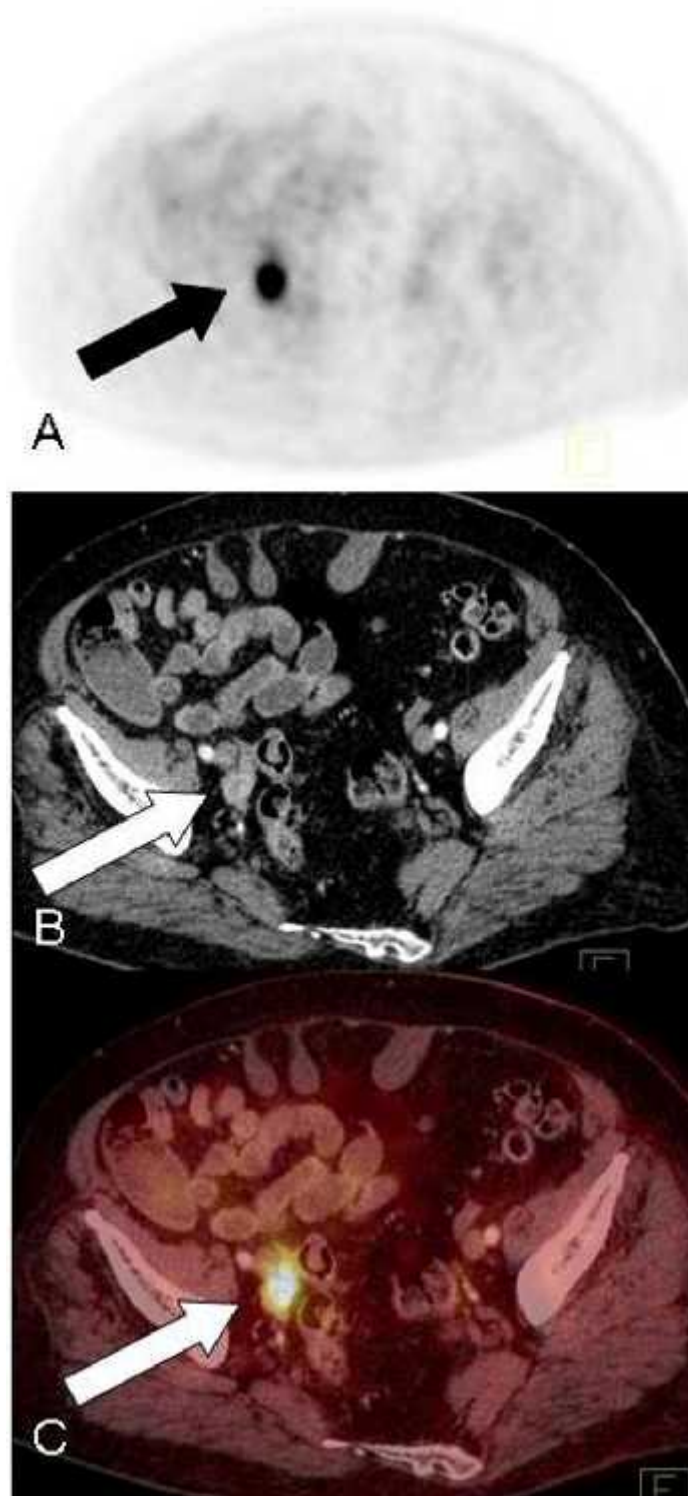


Figure 2. Transverse PET, intravenous contrast enhanced CT, and fused PET/CT images in a 73-year-old post menopausal woman with Leydig cell ovarian cancer. A, There is a focus of intense FDG uptake in the right adnexal region on PET (arrow). B, There is an abnormal soft tissue lesion on CT posterior to the right external iliac artery and vein (arrow). C, Fused images help localize the increased FDG uptake to the soft tissue nodule (arrow). This information was of assistance to the surgeon at subsequent diagnostic laparoscopy where tissue was obtained and the diagnosis of ovarian cancer was made.

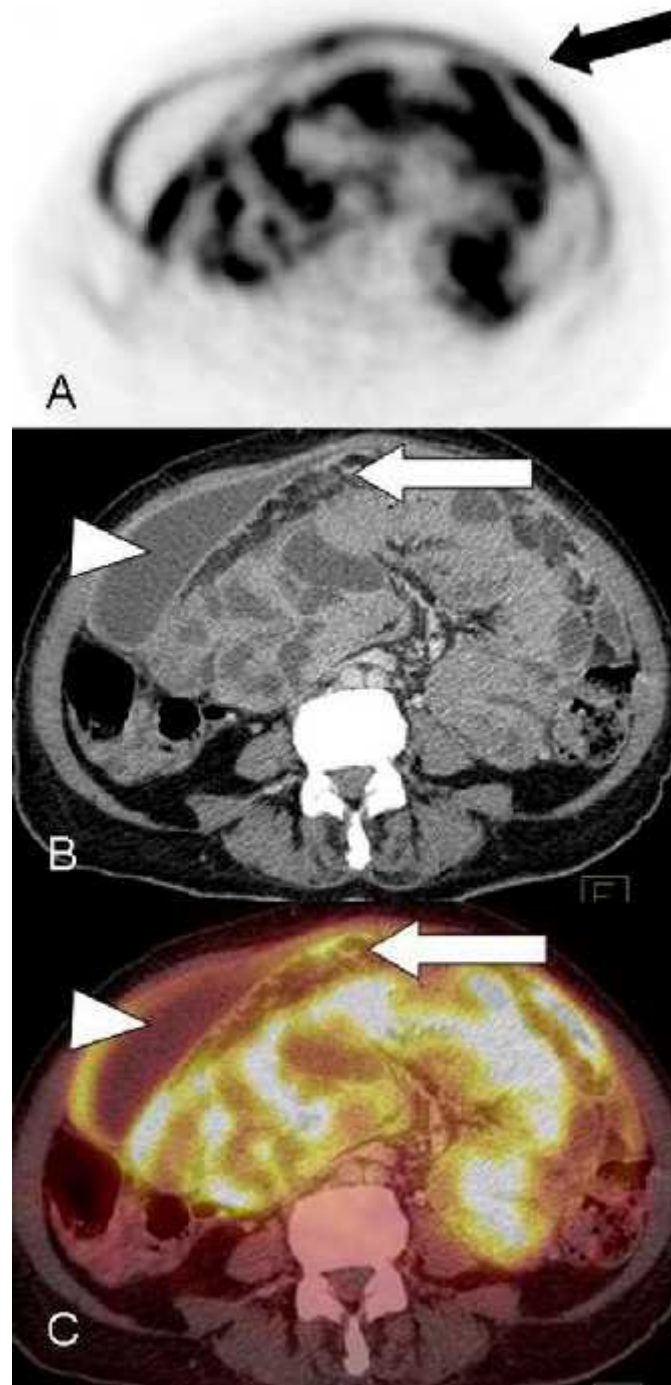


Figure 3. Transverse PET, intravenous contrast enhanced CT, and fused PET/CT images in a 63-year-old post menopausal woman with ovarian cancer and extensive peritoneal metastases. A, There are crescent-shaped areas of FDG uptake on the small bowel mesentery on PET (arrow). B, There is abnormal soft tissue in the omentum on CT (arrow) with associated ascites (arrowhead) and inflammatory fat stranding. Due to the close proximity between bowel, fat standing and peritoneal disease, the soft tissue planes are indistinct and the tumor extent is uncertain on CT alone. C, Fused images help localize the local extent of tumor (arrow) within the abdomen. Note the increased uptake in the peritoneum surrounding the liver (arrowhead). Findings are important for assessment of tumor burden and for oncological follow-up in this case which is not amenable to surgical cure.

PET/CT in ovarian cancer

PET/CT provides is that it helps distinguish between stage I–IIIB cancer from stage III C–IV cancer. This distinction is very important since optimal treatment for stage I–IIIB disease entails debulking surgery whereas, the majority of patients with stage IIIC–IV disease are better treated with chemotherapy. PET/CT for the purpose of making this vital distinction has a specificity, sensitivity, and accuracy of 91%, 100%, and 98%, respectively, compared with 64%, 97%, and 88% for CT (6). This has been recognized by the European Society of Urogenital Radiologists (ESUR) which has stated that PET/CT may be indicated when there is suspected stage IV disease or where intravenous contrast is contraindicated, although the Society believes that the benefits of PET/CT over CT for the staging of ovarian cancer have not been clearly established (10).

6. DETECTION OF RECURRENT DISEASE

Approximately 75% of patients with ovarian cancer experience disease recurrence following treatment with curative intent (11). Early diagnosis and accurate localization of recurrence and of metastases are essential for appropriate clinical decision-making. This is because the number of sites of recurrence affects prognosis following cytoreductive surgery for recurrent ovarian cancer (12). PET/CT is particularly valuable in this setting for the detection of disease that could otherwise be missed on CT such as peritoneal disease. Peritoneal deposits in the greater omentum, on the diaphragm or on the surface of the liver can sometimes be easily overlooked on CT alone. Ascites is a less common feature of recurrent ovarian cancer compared with primary cancer and its presence is suggestive of widespread peritoneal disease (10). The serological tumor marker CA-125 has a high sensitivity for early detection of recurrence, however, it does not quantify tumor burden or indicate the location of recurrence. CA-125 also has a poor negative predictive value (13). PET has a sensitivity of 96% for the detection of recurrent disease when CA-125 levels rise and reportedly predates CT appearances by six months (14). The ESUR acknowledges the growing data in support of the role for PET/CT when CA-125 is increasing but where conventional imaging is inconclusive and that PET/CT has a role when there is suspicion for recurrence and CT and MRI are negative (10). CT has been the standard imaging technique for evaluation of suspected recurrence of ovarian cancer. Accuracy of CT varies from 38% to 88% (15). PET/CT has been shown to increase the accuracy of diagnosing recurrence (Figures 4, 5 and 6). FDG PET/CT is considered appropriate by the American College of Radiology for the imaging of patients with suspected recurrence and a negative CT and for the assessment of patients with oligometastatic disease on CT as part of treatment planning (16). The patient-based sensitivity, specificity, and accuracy of PET/CT ranges from 53% to 97%, 80% to 97%, and 68% to 92%, respectively (15, 17–18). The lowest sensitivity of 53% was reported in a study where the lesions which were FDG negative measured less than 5 mm

in size; below the resolution of PET/CT and essentially all other currently available imaging techniques (15). PET/CT has a high positive predictive value of 89%–98% for recurrence of ovarian cancer and appears to be more sensitive for the detection of extra-pelvic lesions than for pelvic lesions (19). This is partly because physiologic bladder uptake can obscure pathologic pelvic uptake. Additionally, the erroneous interpretation of FDG uptake due to postsurgical pelvic inflammatory changes as representative of tumor recurrence can lead to false-positive results on PET/CT.

The profile of PET/CT for restaging recurrent ovarian cancer has been raised due to its ability to help physicians accurately localize lesions and quantify the extent of recurrence and metastases. PET/CT for the prediction of optimal cytoreduction in recurrent ovarian cancer has a reported accuracy of 79%, sensitivity of 93%, specificity of 56%, positive predictive value of 77%, and negative predictive value of 83% (20). Therefore FDG PET/CT has good efficacy in planning surgical treatment of patients with recurrent ovarian cancer (20). PET/CT was found to be comparable to staging laparoscopy for this purpose with the caveat that false-negative results are most likely to occur due to limited detection of small peritoneal implants which measure less than 7 mm in size. It has been shown that information gained from PET/CT changes treatment technique for 44–57% of patients (21, 22).

7. POTENTIAL LIMITATIONS

The accurate characterization of lesions that measure less than 1cm in diameter using FDG PET/CT is suboptimal due to the spatial resolution limitations of PET. This has important implications for the detection of small deposits of malignancy such as miliary disease, for which a false-negative rate of 5%–10% is quoted. Detection of small peritoneal deposits measuring less than 5mm in size is also limited due to significantly lower SUV values ($p=0.006$) probably due to reduced FDG uptake and spatial resolution limits of PET (23). The presence of bowel peristalsis in the abdomen and pelvis combined with physiological bowel and bladder uptake can create misregistration of PET and CT data and interfere with interpretation (24). Usually an awareness of this phenomenon and careful image review are sufficient for accurate interpretation. PET/CT for the detection of recurrent ovarian cancer can also be limited by the difficulty distinguishing postoperative inflammatory changes from tumor recurrence or persistence (Figure 7). Often, correlation with prior imaging, clinical, and biochemical examinations helps determine the significance of abnormal FDG uptake and helps decision making. The reporting radiologist should also be aware of the potential for low FDG uptake either by necrotic tumors or those which contain considerable amounts of mucin (8).

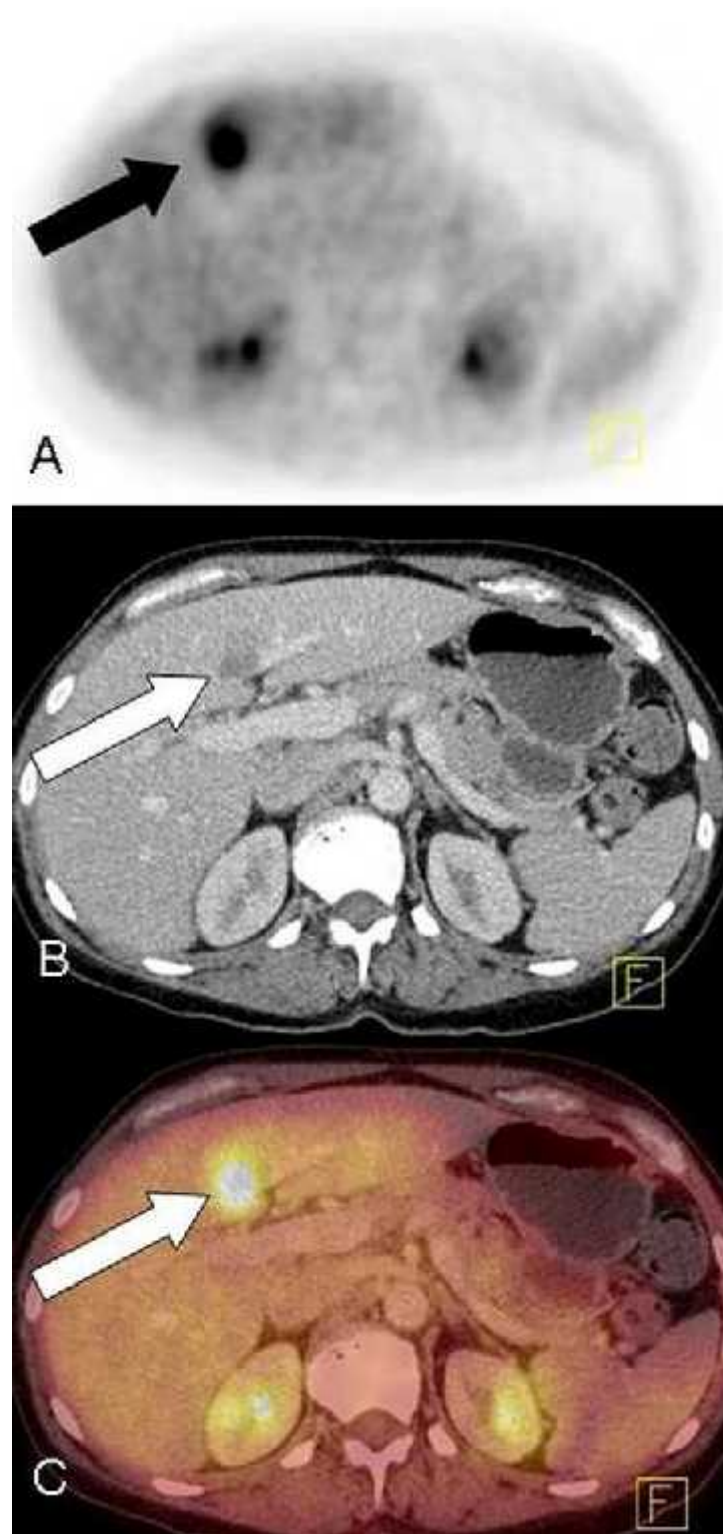


Figure 4. Transverse PET, intravenous contrast enhanced CT, and fused images in a 62-year-old-woman with metastatic ovarian cancer to the liver. A, There is increased FDG uptake in the segment 4B of the liver (arrow) adjacent to the falciform ligament on PET imaging. B, A metastatic deposit in segment 4B is confirmed on CT (arrow). C, Fused images confirms increased FDG uptake in the liver lesion identified on CT (arrow). No other foci of abnormal increased uptake were seen within the liver.

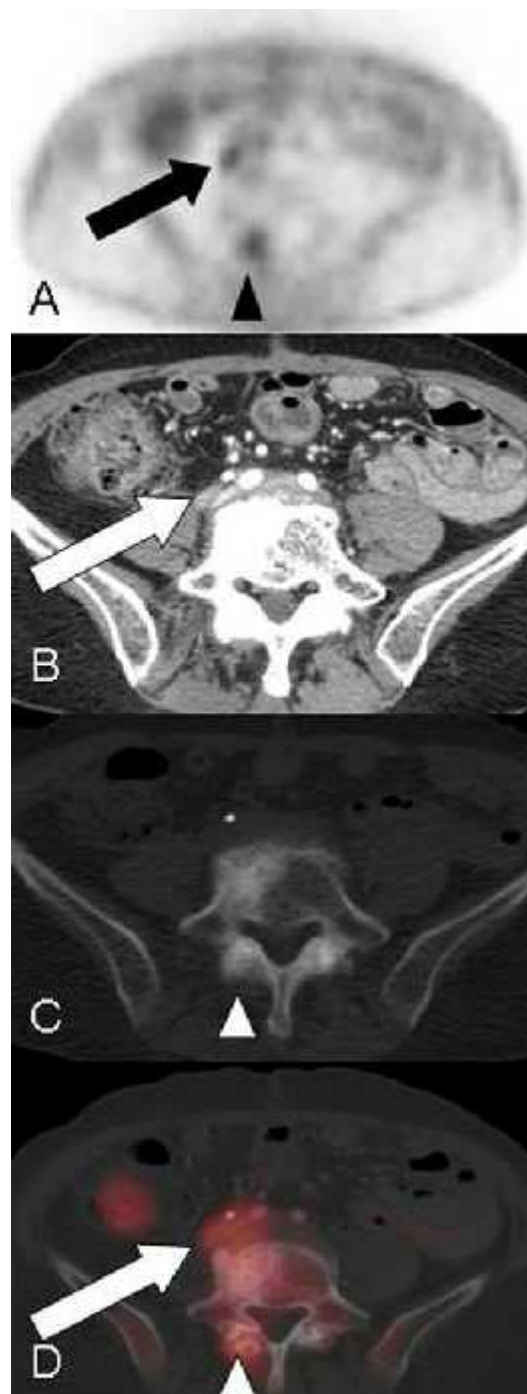

Figure 5. Transverse PET, intravenous contrast enhanced CT, and fused PET/CT images with bone windows in a 72-year-old-woman with metastatic ovarian cancer to the retroperitoneum. A, There is a small focus of increased FDG uptake in the retroperitoneum on PET (arrow). It is not possible to differentiate between normal ureteric or metastatic uptake based on PET alone. A second focus of increased FDG uptake is seen in a vertebra at this level (arrowhead). B, On soft tissue windows, there is a small linear soft tissue lesion posterior to the right ureter on CT (arrow). C, On bone windows, it can be seen that there is hypertrophy at the level of the facet joint (arrowhead). D, Fused images confirm increased FDG uptake in the retroperitoneum lies within the soft tissue lesion, likely a lymph node posterior to the right ureter (arrow) rather than in the ureter itself. This uptake is therefore highly suspicious for metastatic disease. Increased spinal uptake is due to facet joint hypertrophy rather than malignancy (arrowhead).

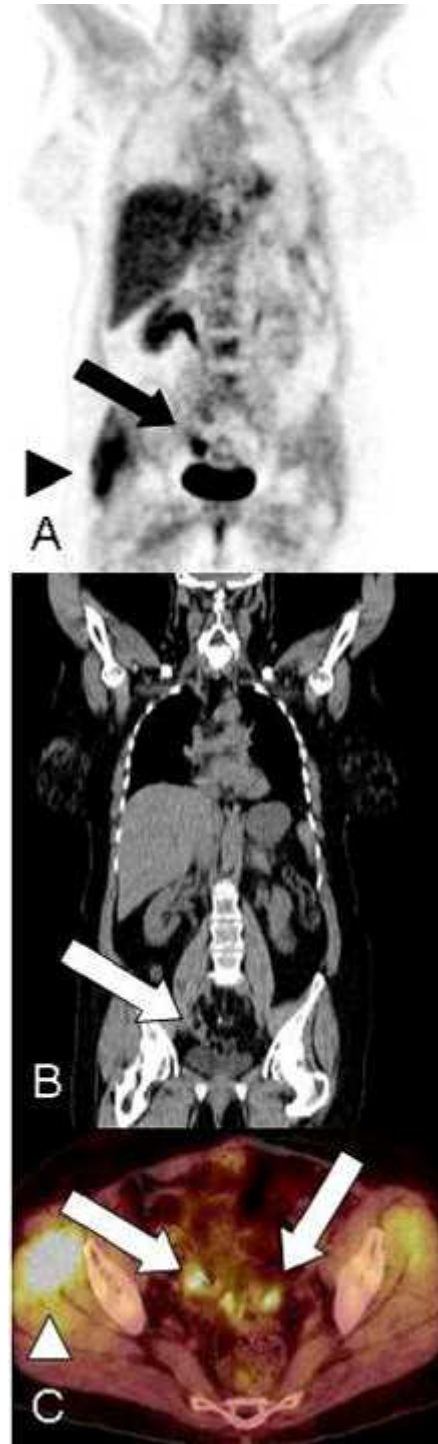

Figure 6. Coronal PET, intravenous contrast enhanced CT, and fused axial PET/CT images in a 59-year-old woman with recurrent ovarian cancer in the pelvis previously treated with hysterectomy and bilateral salpingo-oophorectomy with a CA-125 level of 11,500. A, There is a discrete focus of avid FDG uptake in the pelvis on PET (arrows). Based on the PET images alone it is difficult to accurately differentiate this uptake from normal bowel uptake, ureter or a bladder diverticulum. Incidental note is made of increased FDG uptake in the upper right thigh (arrowhead). B, There is a soft tissue lesion in the pelvis on CT (arrow). C, Fused images confirms increased FDG uptake in two soft tissue pelvic lesions rather than in bowel and therefore these deposits are likely metastases (arrows). Upper right thigh FDG uptake is again noted (arrowhead) without a mass on CT. This increased FDG uptake is due to muscle activity and not metastatic disease.

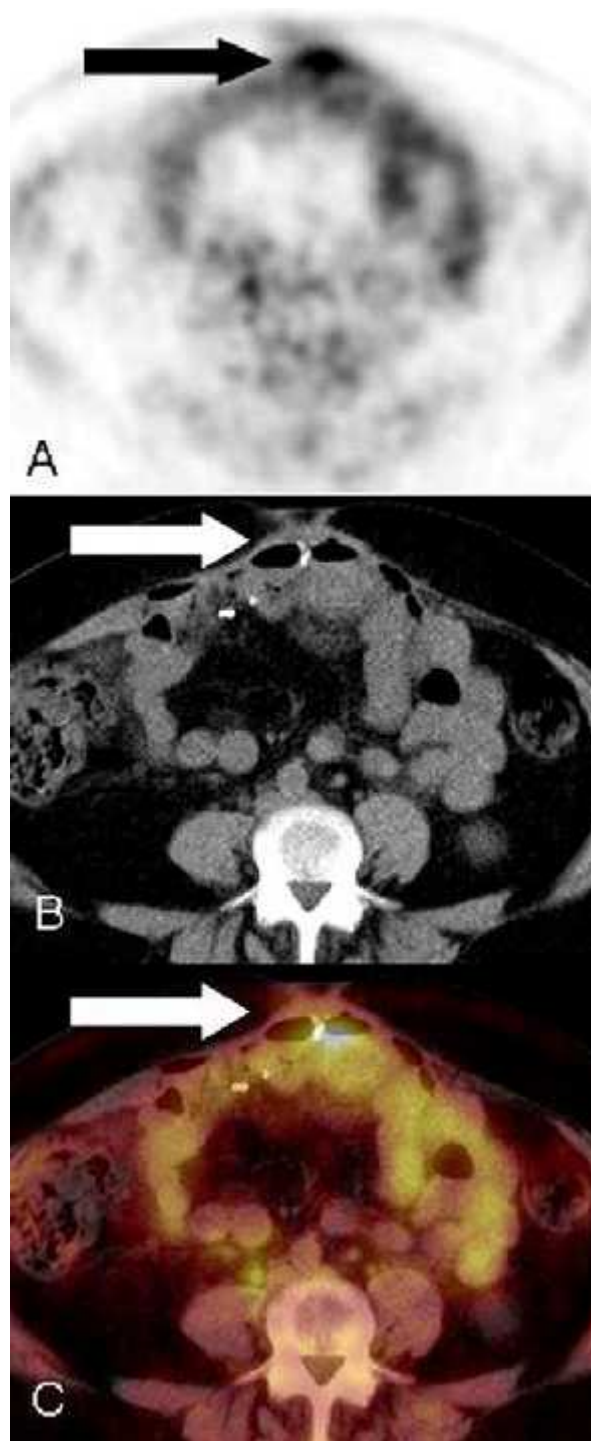


Figure 7. Transverse PET, intravenous contrast enhanced CT, and fused PET/CT images in a 59-year-old-woman (same case as in Figure 6) with recurrent ovarian cancer at site of previous surgery and CA-125 level of 11,500. A, There is abnormal FDG uptake in the anterior abdominal wall on PET (arrow). B, There is subtle increased soft tissue thickening in the region of the surgical clips (arrow) in the anterior abdominal wall that could be secondary to surgery and represent suture granuloma or fibrosis. C, Fused images confirm increased FDG uptake in the anterior abdominal wall at the level of the surgical clips (arrow). The prior surgery was 2 years before the PET/CT and therefore this uptake is abnormal and highly suspicious for metastatic disease.

8. CONCLUSION

The American Cancer Society estimates that ovarian cancer will account for 21,990 new malignancies and 15,460 deaths in 2011 in the United States, which makes ovarian cancer responsible for the greatest number of deaths among patients with gynecologic malignancy (1). FDG PET/CT is an important tool for the preoperative evaluation and post operative surveillance of these women. FDG PET/CT has the potential to provide clinically important information and appropriately direct patient management. Pending better data from randomized studies, PET is currently best indicated for the staging of ovarian cancer when stage IV disease is suspected or intravenous contrast is contraindicated. In the setting of suspected recurrent disease PET should be considered if conventional imaging is inconclusive in the presence of rising CA-125 titers.

REFERENCES

1. ACR practice guidelines for performing FDG-PET/CT in oncology. http://www.acr.org/secondarymainmenucategories/quality_safety/guidelines/nuc_med/fdg_pet_ct.aspx. Accessed July 21, 2011
2. Rebecca Siegel, Elizabeth Ward, Otis Brawley, Ahmedin Jemal: Cancer statistics, 2011: The impact of eliminating socioeconomic and racial disparities on premature cancer deaths. *CA Cancer J Clin* 61(4), 212-36 (2011)
3. Yiyang Liu: Benign ovarian and endometrial uptake on FDG PET-CT: patterns and pitfalls. *Ann Nucl Med* 23, 107-112 (2009)
4. Sabine Fenchel, Dieter Grab, Karin Nuessle, Joerg Kotzerke, Andrea Rieber, Rolf Kreienberg, Hans-Juergen Brambs, Sven N. Reske: Asymptomatic adnexal masses: correlation of FDG PET and histopathologic findings. *Radiology* 223, 780-788 (2002)
5. Paola Castellucci, Anna Perrone, Mariac Picchio, Tullio Ghi, Mohsena Farsad, Cristina Nanni, Cristina Messa, Maria Merigiola, Giuseppe Pelusi, Adil Al-Nahhas, Domenico Rubello, Ferruccio Fazio, Stefano Fanti: Diagnostic accuracy of ¹⁸F-FDG PET/CT in characterizing ovarian lesions and staging ovarian cancer: correlation with transvaginal ultrasonography, computed tomography, and histology. *Nucl Med Commun* 28, 589-595 (2007)
6. Kazuhiro Kitajima, Koji Murakami, Erena Yamasaki, Yasushi Kaji, Ichio Fukasawa, Noriyuki Inaba, Kazuro Sugimura: Diagnostic accuracy of integrated FDG-PET/contrast-enhanced CT in staging ovarian cancer: comparison with enhanced CT. *Eur J Nucl Med Mol Imaging* 35, 1912-1920 (2008)
7. Svetlana Mironov, Oguz Akin, Neeta Pandit-Taskar, Lucy Hann: Ovarian cancer. *Radiol Clin North Am* 45, 149-166 (2007)

8. Hongju Son, Shahid Khan, Jamal Rahaman, Katherine Cameron, Monica Prasad-Hayes, Linus Chuang, Josef Machac, Sherif Heiba, Lale Kostakoglu: Role of FDG PET/CT in staging of recurrent ovarian cancer. *Radiographics* 31, 569-583 (2011)
9. Katsunobu Kawahara, Yoshida Yoshida, Tetsuji Kurokawa, Yoshiro Suzuki, Keiko Nagahara, Tatsuro Tsuchida, Hidehiko Okazawa, Yasuhisa Fujibayashi, Yoshiharu Yonekura, Fumikazu Kotsuji: Evaluation of positron emission tomography with tracer 18-fluorodeoxyglucose in addition to magnetic resonance imaging in the diagnosis of ovarian cancer in selected women after ultrasonography. *J Comput Assist Tomogr* 28, 505-516 (2004)
10. Rosemarie Forstner, Evis Sala, Karen Kinkel, John Spencer: European Society of Urogenital Radiology. ESUR guidelines: ovarian cancer staging and follow-up. *Eur Radiol* 20, 2773-2780 (2010)
11. Robert Greenlee, Mary Beth Hill-Harmon, Taylor Murray, Michael Thun: Cancer statistics, 2001. *CA Cancer J Clin* 51, 15-36 (2001)
12. Ioannis Biliatis, Dimitrios Haidopoulos, Alexandros Rodolakis, Georgios Vlachos, Athanasios Protopapas, Nikolaos Thomakos, Theodoros Sergentanis, Nikolaos Akrivos, Aris Antsaklis: Survival after secondary cytoreduction for recurrent ovarian cancer: Which are the prognostic factors? *J Surg Oncol*. 2010 Aug 18. pubmed ahead of print
13. Gordon Rustin, Ann Nelstrop, Malgorzata Tuxen, Hannah Lambert: Defining progression of ovarian carcinoma during follow-up according to CA 125: a North Thames Ovary Group study. *Ann Oncol* 7, 361-364 (1996)
14. Michael Zimny, Wulf Siggelkow, Willibad Schröder, Bernd Nowak, Susanne Biemann, Werner Rath, Ulrich Buell: 2-[Fluorine-18]-fluoro-2-deoxy-d-glucose positron emission tomography in the diagnosis of recurrent ovarian cancer. *Gynecol Oncol* 83, 310-315 (2001)
15. Sandro Sironi, Cristina Messa, Giorgia Mangili, Barbara Zangheri, Giovanni Aletti, Elisabetta Garavaglia, Riccardo Vigano, Maria Picchio, Gianluca Taccagni, Alessandro Del Maschio, Ferruccio Fazio: Integrated FDG PET/CT in patients with persistent ovarian cancer: correlation with histological findings. *Radiology* 233, 433-440 (2004)
16. ACR Appropriateness Criteria October 2008. http://www.acr.org/secondarymainmenucategories/quality_safety/app_criteria.aspx 2008. Accessed August 20, 2010.
17. Hyun Chung, Won Kang, Jae Kim, Noh-Hyun Park, Yong-Sang Song, June-Kay Chung, Soon-Beom Kang, Hyo-Pyo Lee: Role of [¹⁸F] FDG PET/CT in the assessment of suspected recurrent ovarian cancer: correlation with clinical or histological findings. *Eur J Nucl Med Mol Imaging* 34, 480-486 (2007)

PET/CT in ovarian cancer

18. Sunit Sebastian, Susanna Lee, Neil Horowitz, James Scott, Alan Fischman, Joseph Simeone, Arlan Fuller, Peter Hahn. PET-CT vs CT alone in ovarian cancer recurrence. *Abdom Imaging* 33,112-118 (2008)

19. Andrei Iagaru, Erik Mittra, Ross McDougall, Andrew Quon, Sanjiv Sam Gambhir: ¹⁸F-FDG PET/CT evaluation of patients with ovarian carcinoma. *Nucl Med Commun* 29, 1046-1051 (2008)

20. Anna Fagotti, Francesco Fanfani, Cristiano Rositto, Domenica Lorusso, Anna De Gaetano, Alessandro Giordano, Giuseppe Vizzielli, Giovanni Scambia: A treatment selection protocol for recurrent ovarian cancer patients: the role of FDG-PET/CT and staging laparoscopy. *Oncology* 75, 152-158 (2008)

21. Mangili Giorgia, Maria Picchio, Sandro Sironi, Riccardo Vigano, Emanuela Rabaiotti, D Bornaghi, Valentino Bettinardi, Cinzia Crivellaro, Cristina Messa, Francesco Fazio: Integrated PET/CT as a first-line re-staging modality in patients with suspected recurrence of ovarian cancer. *Eur J Nucl Med Mol Imaging* 34, 658-666 (2007)

22. Bryony Simcock, Deborah Neesham, Michael Quinn, Elisabeth Drummond, Alvin Milner, Rodney Hicks: The impact of PET/CT in the management of recurrent ovarian cancer. *Gynecol Oncol* 103, 271-276 (2006)

23. Pierandrea De Iaco, Alessandra Musto, Luca Orazi, Claudio Zamagni, Marta Rosati, Vincenzo Allegri, Nicoletta Cacciari, Adil Al-Nahhas, Domenico Rubello, Stefano Venturoli, Stefano Fanti: FDG-PET/CT in advanced ovarian cancer staging: Value and pitfalls in detecting lesions in different abdominal and pelvic quadrants compared with laparoscopy. *Eur J Radiol* 80, 98-103 (2011)

24. Priyanka Prakash, Carmel Cronin, Michael Blake: Role of PET/CT in Ovarian Cancer. *AJR* 194, 464-470 (2010)

Abbreviations: FDG PET/CT: fluorodeoxyglucose positron emission tomography/computed tomography, CT: computed tomography, MDCT: multidetector CT; SUV: standardized uptake value, BMI: body mass index, ESUR: European Society of Urogenital Radiologists, TNM: tumor node metastasis

Key Words Ovarian cancer, PET-CT, Oncology, FDG-PET, Review

Send correspondence to: Michael A Blake, Department of Radiology, Massachusetts General Hospital and Harvard Medical School, 55 Fruit St., Boston, MA 02114, USA, Tel: 617-726-8396, Fax, 617-726-4891, E-mail: mblake2@partners.org